

Quadricuspid Aortic Valve Combined with Moderate Ascending Aortic Dilatation

A Report of Four Cases

Vladimir E. Uspenskiy, MD, PhD*, Alexei M. Osadchii, MD, PhD, Mikhail L. Gordeev, MD, PhD

Department of Cardiothoracic Surgery, Northwest Federal Medical Research Centre, Saint Petersburg, Russia

Abstract

The quadricuspid aortic valve is a very uncommon malformation associated with aortic insufficiency, aortic stenosis, endocarditis, and ascending aortic dilatation. We report four cases of this aortic valve malformation. One patient with severe aortic regurgitation and moderate aortic dilatation required aortic valve replacement. Three patients had mild or moderate aortic insufficiency combined with moderate ascending aortic dilatation. These patients were referred to follow-up. The presented cases demonstrate that this aortic valve malformation may not be as rare as it appears and that attention must be paid to any quadricuspid findings during computed tomographic angiography and echocardiography.

Copyright © 2015 Science International Corp.

Key Words

Aorta • Aortic valve disease • Bicuspid aortic valve • Dilatation • Quadricuspid ascending aneurysm

Introduction

The quadricuspid aortic valve (QAV) is a very uncommon malformation [1]. A much more common congenital aortic valve lesion is bicuspid aortic valve (BAV). Approximately 50% of patients with QAV develop severe aortic insufficiency (AI) [2], which may require aortic valve replacement [3]. Another condition

common to QAV is ascending aortic dilatation. We present four cases of congenital QAV with varying degrees of aortic dilatation and insufficiency.

Case Report

Three asymptomatic patients (two males) underwent computed tomographic (CT) angiography, which revealed borderline ascending aortic dilatation (Figure 1A) and congenital QAV (Figure 1B). Echocardiography revealed mild or mild-to-moderate (between grades 1 and 2) AI in all patients, without significant aortic stenosis, and with normal to moderately dilated left ventricle (Table 1). The 2- and 3-dimensional echocardiography verified symmetric a 4-cusp valve and a 4-sinus aortic root. These patients were followed medically.

Another patient, a 64-year-old male, was admitted to our clinic, with dyspnea on exertion and chest discomfort. Echocardiography revealed QAV with severe AI (Figure 2A) and moderate ascending aortic dilatation. The left ventricle was dilated with normal ejection fraction (Table 1). CT angiography confirmed these findings. Coronary angiography revealed normal coronary arteries. The patient underwent open heart surgery (Figure 2B). The aortic valve was replaced with a 23-mm mechanical bi-leaflet



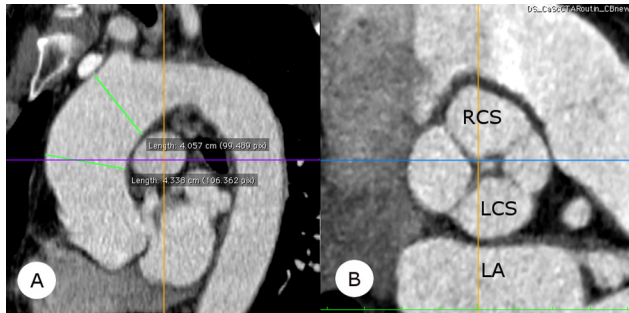


Figure 1. Panel A. Computed tomographic (CT) angiography of moderately dilated ascending aorta. Panel B. CT angiography of Type B quadricuspid aortic valve (QAV). LA = left atrium; LCS = left coronary sinus; RCS = right coronary sinus.

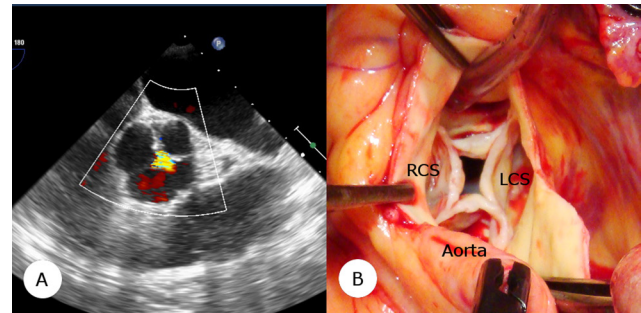


Figure 2. Panel A. Transesophageal echocardiography of quadricuspid aortic valve (QAV), note central AI flow. Panel B. Intra-operative view of QAV. LCS = left coronary sinus; RCS = right coronary sinus.

prosthesis. Histological examination revealed fibrosis of the aortic cusps. The post-operative period was uneventful. Echocardiography before discharge showed normally functioning aortic valve prosthesis and reduced volume of the left ventricle without any depression of its contractility.

Discussion

The congenital QAV is a rare abnormality of the aortic valve, diagnosed in 0.04–0.008% of autopsies as well at echocardiography studies [1, 2]. Like BAV, congenital QAV is associated with the development of AI, aortic stenosis and ascending aortic dilatation [2, 3]. In all our presented cases, the ascending aorta was moderately dilated with the presence of some AI. In one case aortic valve replacement was required due to severe AI. In addition, QAV can be associated with other cardiac abnormalities: ruptured sinus of Valsalva, subaortic stenosis, hypertrophic cardiomyopathy,

coronary artery abnormalities, patent ductus arteriosus and ventricular septal defects [4].

Hurwitz and Roberts [1] described seven types of congenital QAV based on valve leaflet size. Due to the risk of aortic-associated severe complications (e.g., acute ascending aortic dissection) and progression of aortic regurgitation, early diagnosis and follow-up in patients with congenital QAV is very important. In all our presented cases, the diagnosis was made by CT angiography.

In QAV, a question arises regarding the timing of surgery. Two factors should be noted: the degree of ascending aortic dilatation and the AI grade. In current guidelines for the management of patients with valvular heart disease there is no data concerning surgery in patients with QAV. We feel that recommendations regarding BAV may reasonably be used also for QAV.

We conclude, that QAV may not be quite as rare as we previously thought. QAV is associated with the development of aortic regurgitation and ascending

Table 1.

Patient No.	Age, years	BSA, m ²	QAV type [1]	Aortic root diameter, mm	Ascending aortic diameter, mm	LV EDV, ml	LV EF, %	AV peak gradient, mm Hg	AI, grade	Decision
1	64	2.04	B	41	44	291	51	19.2	3	Surgery
2	63	1.89	B	40	43	142	55	9.3	1	Follow-up
3	61	2.21	D	44	46	224	56	21.0	2	Follow-up
4	70	1.82	A	37	45	173	65	17.6	2	Follow-up

AI = aortic insufficiency; BSA = body square area; EDV = end-diastolic volume; EF = ejection fraction; LV = left ventricle; QAV = quadricuspid aortic valve.

aortic dilatation. Close follow-up is essential to ensure surgical intervention before severe AI occurs (with consequent left ventricle damage) and before severe aortic dilatation (with possible aortic dissection) supervenes.

Acknowledgements

The authors would like to thank Dr. Andrey Kozlenok for performing 2- and 3-dimensional

transesophageal echocardiography and professors Roberts and Thompson for English language and grammar corrections.

Conflict of Interest

The authors have no conflicts of interest relevant to this publication.

[Comment on this Article or Ask a Question](#)

References

1. Hurwitz LE, Roberts WC. Quadricuspid semilunar valve. *Am J Cardiol.* 1973;31:623-626. DOI: [10.1016/0002-9149\(73\)90332-9](https://doi.org/10.1016/0002-9149(73)90332-9)
2. Godefroid O, Colles P, Vercauteren S, Louagie Y, Marchandise B. Quadricuspid aortic valve: A rare etiology of aortic regurgitation. *Eur J Echocardiogr.* 2006;7:168-170. DOI: [10.1016/j.euje.2005.03.011](https://doi.org/10.1016/j.euje.2005.03.011)
3. Zhu J, Zhang J, Wu S, Zhang Y, Ding F, Mei J. Congenital quadricuspid aortic valve associated with aortic insufficiency and mitral regurgitation. *J Cardiothorac Surg.* 2013;8:87. DOI: [10.1186/1749-8090-8-87](https://doi.org/10.1186/1749-8090-8-87)
4. Kawano Y, Kimura M, Motomura T, Nakamura M, Iwakuma A, Sukehiro S. Quadricuspid aortic valve with aortic regurgitation: Report of a case and a review of the surgically corrected cases reported in Japan. *Med Bull Fukuoka Univ.* 2002;29:151-158. PMID: [1010183](https://pubmed.ncbi.nlm.nih.gov/1010183/)

Cite this article as: Uspenskiy VE, Osadchii AM, Gordeev ML. Quadricuspid Aortic Valve Combined with Moderate Ascending Aortic Dilatation: A Report of Four Cases. *AORTA (Stamford).* 2015;3(6):187-190. DOI: <http://dx.doi.org/10.12945/j.aorta.2015.15.004>

EDITOR'S COMMENTS

Wei-Guo Ma, MD

*Beijing Anzhen Hospital
Capital Medical University
Beijing, China*

Quadricuspid Aortic Valve: Rare But Real

With interest I read the report of Uspenskiy and associates on quadricuspid aortic valve (QAV) with ascending aortic dilatation.

QAV is believed to be a very rare congenital anomaly, but the incidence is probably underestimated. Although the incidence was reported to be between 0.008-0.033% in early years, the incidence was 0.043% in an echo series [1]. In patients undergoing aortic valve replacement, the incidence ranges from 0.55% to 1.46% [2].

In 2001, Nakamura and colleagues [3] proposed a classification according to the position of the accessory cusp based on a review of 42 patients with QAV in Japan. It is composed of 4 types and simpler than the classification originally described by Hurwitz and Roberts in 1973 [4].

Recent literature suggests that an abnormal number of cusps is caused by developmental changes in the early stages of truncal separation. The abnormal aortic valve can be uni-, bi-, quadri- and penta-cuspid [5]. BAVs tend to be stenotic while QAVs tend to regurgitate. In a recent large series of 31 patients with QAVs from the Cleveland Clinic, moderate to severe aortic regurgitation was seen as the predominant hemodynamic lesion in 68% of the patients [6]. Specific criteria for aortic intervention in patients with QAV do not exist, due to the rarity of this anomaly.

References

1. Feldman BJ, Khandheria BK, Warnes CA, Seward JB, Taylor CL, Tajik AJ. Incidence, description and functional assessment of isolated quadricuspid aortic valves. *Am J Cardiol* 1990;65:937-938. DOI: [10.1016/0002-9149\(90\)91446-D](https://doi.org/10.1016/0002-9149(90)91446-D)
2. Yotsumoto G, Iguro Y, Kinjo T, Matsumoto H, Masuda H, Sakata R. Congenital quadricuspid aortic valve: report of nine surgical cases. *Ann Thorac Cardiovasc Surg* 2003;9:134-137. PMID: [12732093](https://pubmed.ncbi.nlm.nih.gov/12732093/)
3. Nakamura Y, Taniguchi I, Saiki M, Morimoto K, Yamaga T. Quadricuspid aortic valve associated with aortic stenosis and regurgitation. *Jpn J Thorac Cardiovasc Surg* 2001;49:714-716. DOI: [10.1007/BF02913511](https://doi.org/10.1007/BF02913511)
4. Hurwitz LE, Roberts WC. Quadricuspid semilunar valve. *Am J Cardiol* 1973;31:623-626. DOI: [10.1016/0002-9149\(73\)90332-9](https://doi.org/10.1016/0002-9149(73)90332-9)
5. McMahon C. Left ventricular outflow obstruction: aortic valve stenosis, subaortic stenosis, supraaortic stenosis, and bicuspid aortic valve. In: Moller JH, Hoffman JIE, Benson DW, van Hare GF, Wren C, eds. *Pediatric Cardiovascular Medicine*, 2nd ed. West Sussex, UK: Wiley-Blackwell;2012:406-425. DOI: [10.1002/9781444398786.ch30](https://doi.org/10.1002/9781444398786.ch30)
6. Idrees JJ, Roselli EE, Arafat A, Johnston DR, Svensson LG, Sabik JF, 3rd, et al. Outcomes after repair or replacement of dysfunctional quadricuspid aortic valve. *J Thorac Cardiovasc Surg* 2015;150:79-82. DOI: [10.1016/j.jtcvs.2015.03.019](https://doi.org/10.1016/j.jtcvs.2015.03.019)