

Visceral Debranching for the Treatment of Thoracoabdominal Aortic Aneurysms

Scott M. Damrauer, MD, Ron M. Fairman, MD

Division of Vascular Surgery and Endovascular Therapy, Hospital of the University of Pennsylvania, Philadelphia, Pennsylvania, USA

Based on a Presentation at the 2013 VEITH Symposium, November 19–23, 2013 (New York, NY, USA)

Abstract

Surgical repair of thoracoabdominal aortic aneurysms (TAAA) is associated with significant morbidity and mortality. Hybrid approaches that involve visceral debranching and aortic endografting allow for an alternative approach in certain high-risk patients. In most circumstances the visceral vessels can be bypassed in a retrograde manner from the iliac arteries via a midline laparotomy, and the aortic aneurysm subsequently excluded with standard aortic endografts. These procedures avoid the extensive two-cavity exposure, aortic cross-clamping, and mechanical circulatory support that comprise open TAAA repair, and offer the theoretical advantage of being less invasive. Despite this, outcomes have been mixed with reported perioperative mortality rates of 0% and 34% and permanent paraplegia rates of 0% to 13% in most major series. The reported outcomes, as well as the variation between centers, highlight the importance of patient selection in undertaking hybrid repair. In practice, the best outcomes are achieved in patients who have high-risk anatomy, rather than high-risk comorbidities.

Copyright © 2015 Science International Corp.

Key Words:

Thoracoabdominal aortic aneurysm • Visceral debranching • Hybrid operation • Thoracic endovascular aortic repair (TEVAR)

Introduction

Surgical repair of thoracoabdominal aortic aneurysms (TAAA) is a formidable undertaking for both patient and surgeon. Clinical outcomes at

high-volume centers are excellent, with cumulative 30-day mortality rates reported as less than 10% in selected series [1, 2]. Larger, more representative databases show that real-world experience does not duplicate these results. In a study using the National Inpatient Sample (NIS) from 1988 to 1998 the overall morbidity was shown to be greater than 50% and mortality was 23% [3]. Totally endovascular approaches are available at select institutions, and are reported to have better outcomes with low rates of mortality, morbidity, and spinal cord ischemia [4-6]; unfortunately, these are not generalizable due to restrictions on access to devices and need for custom fabrication.

Hybrid procedures offer an alternative approach to TAAA management. Relying on a combination of standard open techniques and off-the-shelf endovascular stent grafts, they are broadly applicable to a wide range of patient anatomy. First described by Quinones-Baldrich and colleagues at the University of California Los Angeles (UCLA), these approaches rely on debranching of the visceral aorta followed by standard endovascular aneurysm repair, covering the entire affected aortic segment [7]. Because hybrid approaches avoid the extensive two cavity exposure, aortic cross-clamping, and mechanical circulatory support that comprise open TAAA repair, they offer the theoretical advantage of being less invasive. Despite this, results following hybrid repair have been mixed, with outcomes varying widely depending on both patient and surgeon related factors. In reality,



hybrid repair is no less of an undertaking for either patient or surgeon, but rather a different undertaking that can offer specific advantages in distinct subsets of patients.

Technical Details

Hybrid TAAA repair is a two-staged procedure, consisting of open visceral debranching followed by aortic endografting. The first stage, visceral debranching, is most commonly achieved from a transabdominal approach via midline laparotomy. In the absence of prior laparotomy, this allows ready exposure of all of the visceral vessels as well as the iliac arteries. Retrograde bypasses are typically constructed from the common iliac arteries using prosthetic conduit and the target vessels are ligated proximal to the revascularization to prevent endoleaks after placement of the aortic stent graft. An iliac conduit is also fashioned to facilitate arterial access for the endovascular portion of the repair. The second stage of the hybrid repair, consisting of aortic endografting to exclude the aneurysm, can be performed at the same operative setting or, as has become our practice, in a delayed fashion. By delaying the aortic endografting portion of the procedure, the patient is given time to recover and the physiological insult is distributed over time. The patients typically remain hospitalized between the first and second stages.

One technical advantage of the hybrid repair is the ability to tailor the visceral reconstruction to patient specific anatomy. For any individual patient, there may be multiple potential bypass configurations and there are a number of important principles to guide in selecting the most appropriate option: these are best illustrated through the example of a recent patient treated at our institution. A 66 year-old female presented with a 7cm Type III TAAA (Figure 1). She had previously undergone an aortic arch replacement as well as a TEVAR (thoracic endovascular aneurysm repair) for a descending aortic aneurysm and the remainder of the aorta was aneurysmal. She had atrial fibrillation and chronic obstructive pulmonary disease and had previously suffered from a pulmonary embolus, acute respiratory distress syndrome, and recurrent pneumonias. She was not felt to be a candidate for traditional open repair and was accordingly offered




Figure 1. Three-dimensional reconstruction of CTA demonstrating previous aortic arch replacement and TEVAR, presenting now with a Type III TAAA.

a hybrid procedure.

The visceral debranching was performed via a midline laparotomy to allow a direct anterior approach to the renal and visceral vessels. The distal common iliac arteries were isolated bilaterally to serve as inflow for the bypass grafts. When selecting a site on the iliac artery to seat the proximal bypass anastomosis, care must be taken to insure that there is sufficient artery proximal to the bypass to allow the iliac limb of the endograft to obtain a distal seal. Although iliac artery based bypasses are by-and-large the most common configuration, the native infrarenal aorta can be used as a basis for the grafts, assuming it is free of aneurysmal disease. Alternatively, if there is extensive aortic or aorto-iliac aneurysmal or occlusive disease, the infrarenal aorta can be replaced with a tube graft sewn to the aortic bifurcation or with a bifurcated graft to the common iliac arteries, and the visceral bypasses based on the replaced segment. In either case, attention, again, must be paid to leave enough normal aorta or proximal graft to provide an appropriate seal zone for the planned endograft.

After isolating the bypass inflow, the target vessels were isolated. Celiac artery revascularization was accomplished via a bypass to the common hepatic artery and was done in a manner that allowed preservation of hepatic and gastric perfusion. From the anterior approach it is usually most straightforward to select the hepatic artery as the recipient site for the bypass as this can be isolated in the omental bursa, or lesser sac. The proximal celiac artery must also be dissected, but only enough to allow the vessel to be ligated after completion of the bypass. By revascularizing the hepatic artery but ligating the celiac trunk, the left gastric and splenic arteries can continue to be perfused by retrograde filling of the proximal hepatic artery. In this patient, the superior mesenteric artery (SMA) was isolated in the omental bursa as it emerged from behind the pancreas. Although the SMA can also be easily identified at the base of the transverse mesocolon, the former location has the advantage of being well proximal to the origin of the middle colic artery, and allows for the ligation of the SMA just proximal to the bypass. The left renal artery was isolated proximally as it branched from the aorta and the right renal artery was identified as it emerged from behind the vena cava; when preparing the renal arteries, care must be taken to insure that the bypass is proximal to any early renal branches.

Prosthetic bypass grafts are used for the revascularization, which can be accomplished with a variety of straight, bifurcated, and custom-branched graft configurations. Target vessels can be revascularized individually or in series with jump grafts. In this patient, bilateral bifurcated Dacron grafts were used to revascularize the right renal and hepatic arteries from the right common iliac artery, and the left renal and superior mesenteric arteries from the left common iliac artery. We have subsequently changed our practice to use a jump graft from the SMA to hepatic artery; this allows us to reserve one of the Dacron limbs for use as a conduit to facilitate subsequent introduction of the stent-graft. The grafts are tunneled retroperitoneally so that they are excluded from the peritoneum and separated from the bowel; the iliac conduit is left buried in the lower abdominal subcutaneous tissue for later exposure.

Aortic endografting for exclusion of the aneurysm can be done concomitantly or in a delayed fashion,

and there are not significant data to unambiguously recommend one approach over another [8]. Proponents of simultaneous procedures argue that the staged approach leaves the patient susceptible to rupture in the intervening period, although there are little data, other than anecdotal experience, to support this approach [9]. Our practice is to perform the stent-graft procedure after the patient has recovered from the debranching, but on the same admission. The delayed approach offers the advantage that it allows the patient to recover from many of the physiological insults of the debranching procedure before exposing them to the risks associated with the placement of the stent grafts. This is especially important in terms of renal function, as it allows the kidneys to recover from the ischemia associated with the bypass before subjecting them to the nephrotoxic iodinated contrast necessary for the endovascular portion of the case.

The patient presented here had a relatively uneventful post-operative course and returned to the operating room on post-operative day 19 for endovascular stent-grafting. A combination of thoracic endografts and a bifurcated abdominal device were used to extend from the previous TEVAR into the proximal common iliac arteries (Figure 2). The choice of endovascular device should be based on surgeon experience and preference and patient anatomy; there is no systematic advantage of one device over another for this procedure. Because of the previous intervention and extent of planned coverage, a spinal drain and somatosensory evoked potential (SSEP) monitoring were used for spinal cord protection. The patient tolerated the procedure well and was discharged home on post-operative day 9 from the stent-graft.

Clinical Outcomes

The hybrid approach has many theoretic advantages (Table 1). Although certainly not a “minimally invasive” procedure, visceral disbranching can be accomplished via a standard laparotomy, without entering the chest cavity, and does not involve aortic cross-clamping or mechanical circulatory support. Because of this, hybrid repair is thought to have the theoretical advantage of being “less-invasive” than

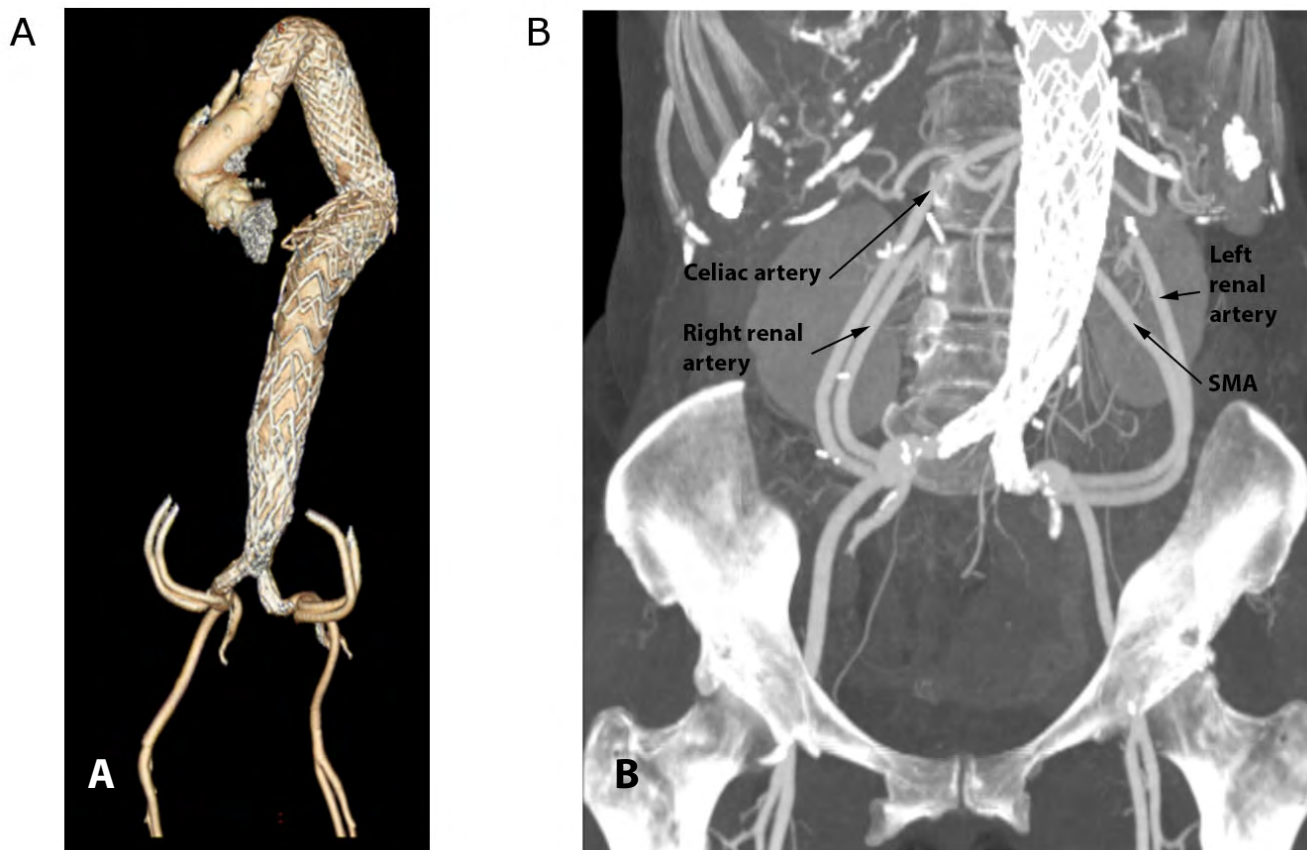


Figure 2. Three-dimensional reconstruction (A) and maximum intensity projection images (B) of follow-up CTA, demonstrating excluded aneurysm and patent ilio-mesenteric and ilio-renal bypasses.

open TAAA repair and theoretically results in less physiological derangement. It was initially hoped that hybrid repair would result in less coagulopathy, ischemia-reperfusion injury, bacterial translocation, sepsis, end-organ damage, and renal failure, culminating in reduced length of stay and lower morbidity

and mortality. In practice, the results of published series have been mixed (Table 2), leaving ambiguity as to the exact role for hybrid repairs [9-24].

Table 1. Theoretical advantages of visceral debranching and hybrid TAAA repair

Technical advantage	Theoretic benefit to patient
No thoracotomy	Decreased post-operative pain,-decreased pulmonary complications
No aortic cross-clamp	Less end-organ ischemia, minimized ischemia-reperfusion injury, decreased renal failure, decreased spinal ischemia
No need for cardiopulmonary support	Less hemodynamic instability, decreased coagulopathy

In 2009 Quinones-Baldrich and colleagues from the University of California Los Angeles (UCLA) reported the follow-up for their first patient and the results of their overall experience in 20 cases [19]. At 10 years, the index patient for hybrid repair was alive and well without the need for further intervention and no aneurysm related morbidity. Among a mixed cohort of high-risk patients who underwent hybrid procedures for aortic arch pathology (three patients) and thoracoabdominal and juxtarenal aortic aneurysms (seventeen patients), they reported nine major complications in six patients (32%), one case of permanent paraplegia (out of 15 patients at risk, 6.6%), and no perioperative mortality (0%). With a mean of 16 months of follow-up they identified 3 endoleaks (30%, one type I, three type II), and no bypass thrombosis

Table 2. Major published series of hybrid TAAA repair with more than 15 patients

Author	Year	Patients	30-day Mortality	Permanent paraplegia	Endoleaks	Graft patency	Overall survival	Mean Follow-up (mos)
Zhou (24)	2006	31	3.2%	0%	6%	95%	90% ^a	16
Black (10)	2006	22	23%	0%	42%	98%	NA	9.5
Lee (15)	2007	17	24%	0%	12%	96%	76% ^a	8
Van de Mortel (23)	2008	16	31%	0%	13%	95%	69% ^a	13
Quinones-Baldrich (19)	2009	20	0%	6.6%	30%	100%	76% ^a	17
Donas (11)	2009	58	8.6%	3.4%	17%	97%	74% ^a	22
Drinkwater (9)	2009	107	15%	8.4%	33%	87%*	NA	NA
Patel (18)	2009	23	17%	4%	23%	90%	68% ^b	6
Kabbani (13)	2010	36	8.3%	0%	39%	93%	80% ^a	6
Patel (17)	2010	29	3.4%	3.4%	34%	95%	NA	NA
Kuratani (14)	2010	86	2.3%	0%	17%	99%	86% ^c	88
Smith (21)	2011	24	12.5%	8.3%	12%	99%	NA	12
Hughes (12)	2012	58	9%	4%	NA	95%	62% ^c	26
Tshomba (22)	2012	52	14%	1.9%	7.7%	93%	77% ^d	24**
Rossett (20)	2014	76	34%	11%	3%	99%	NA	30
Massoni (16)	2014	45	24%	13%	NA	79%	45% ^e	26

* 30 day ** median ^aat end of follow-up period ^b1-year Kaplan-Meier survival ^c5-year Kaplan-Meier survival ^dfreedom from aortic-related deaths at end of follow-up ^e6-year Kaplan-Meier survival

or aneurysm enlargement. There were two reinterventions (10%, one type I and one type II endoleak). The overall survival was 76% at 2 years. Based on their durable outcomes, low morbidity and mortality, and little need for reintervention, the UCLA group concluded that hybrid repair offered significant advantages to traditional open repair, especially for high-risk patients.

Hughes and colleagues from Duke report similar outstanding outcomes [12]. Among 58 patients who underwent hybrid repair, there was a 9% rate of perioperative mortality and a 4% rate of permanent paraplegia. Interestingly, the paraplegia rate was nil among the final 25 patients in the series, all of whom had staged repairs. Those patients who underwent staged repairs also had shorter combined operative times, decreased intraoperative transfusions, and were more likely to be extubated in less than 24 hours than those who had single-stage procedures. With a median follow-up of 26 months, there

was a 95% graft patency rate, and all thromboses were clinically silent. There was no intervention for required for any endoleaks.

The excellent early results achieved in these studies are complemented by recent publications attesting to the durability of the visceral artery bypass grafts and low rates of late aortic related death. In 46 patients with 164 grafts, Shaherdan and colleagues report an 86% 5-year primary patency rate [25]. Patency at 5-years for individual bypasses ranged from 69% for the right renal artery to 100% for the hepatic artery, with the left renal and SMA between 87% and 88%. Among the 32 patients surviving past the perioperative period, there were 6 deaths due to procedure related respiratory failure, and only 2 deaths due to aortic or branch vessel complications.

The experience reported by Patel and colleagues from Massachusetts General Hospital (MGH) stands in stark contrast. A recognized high volume center for aortic surgery, MGH has traditionally reported out-

standing results with open TAAA repair [26]. When Patel and colleagues examined the outcomes of hybrid procedures in 23 high-risk individuals who were not candidates for open TAAA (type I-III) repair, they reported a 4.3% rate of permanent paraplegia and a 26% in-hospital mortality rate, all of which were higher than what they observed in their contemporaneous open experience (3.9% permanent paraplegia and 10% mortality) [18]. With a mean follow-up period of 166 days, there were 7 graft thromboses out of 70 grafts (10%) and five endoleaks (22%, three type I and two type II), three of which required reintervention. The poor results obtained in the patients who underwent hybrid repair lead the MGH group to conclude that the morbidity and mortality profile should limit the use of the hybrid repair, and that many patients unfit for open repair were simply unfit for surgical intervention of any kind.

This sobering appraisal is further supported by a study from the North American Complex Abdominal Aortic Debranching Registry that demonstrated a 14% SCI rate among 159 patients treated at a total of 13 institutions [27]. This rate significantly exceeded that which has been reported for open repair in most specialized aortic centers [1, 2], and suggests that despite avoiding many of the issues related to spinal cord perfusion in traditional open repairs, hybrid approaches are not able to improve upon those outcomes.

The different outcomes obtained in these studies likely reflect differences in the underlying cohorts between the centers and highlight the importance of patient selection in hybrid repair. In examining the specifics of the patient cohorts, the MGH cohort appears to be higher risk with regard to patient comorbidities and physiology, suggesting that although hybrid repair may offer some advantage in morbidity and mortality, it is certainly not a low-risk endeavor. Despite the outstanding outcomes of the UCLA and Duke groups, the MGH experience demonstrates that there are, in fact, limits to how far the hybrid technique can be pushed, and that in extremely high-risk patient populations, a non-operative approach may be advisable.

The largest single series in the literature is a multi-institutional European study reported by Drinkwater and colleagues [9]. Reporting on 107 consecutive hybrid repairs, they had a 93% technical success

rate, an 8% rate of permanent paraplegia, and a 15% 30-day mortality rate. There was 86% graft patency at 30-days and an initial endoleak rate of 33%. Although these results are quite similar to those reported by MGH, Drinkwater et al. offer an alternative interpretation of their experience. They highlight that the even though their cohort is high risk, based on the patients' comorbidities and the fact that many were previously denied open repair, their outcomes compare favorably with those reported in the non-selected, real-world studies of open TAAA repairs, where morbidity ranges from 19% to 23% [3, 28]. This leads them to conclude that despite the fact that hybrid TAAA carries a significant associated morbidity and mortality, it offers a viable alternative to traditional open repair in high risk patients.

A recent meta-analysis of 19 studies encompassing 507 patients demonstrated similar results [29]. The authors report a pooled rate of 30-day mortality at 12%, a pooled rate of permanent paraplegia of 4.5%, and a pooled rate of renal insufficiency of 8.8%. During a mean follow-up period of 34 months, the graft patency was 96% and there was a 23% rate of endoleak, with 27% of those patients requiring reintervention. Because a pooled analysis was performed, these results are likely heavily biased by those of Drinkwater and colleagues, which comprised 20% of the patients [9], but, nonetheless, provide the best estimates of the morbidity and mortality associated with hybrid TAAA repair. Based on these data, hybrid repairs carry a significant, but not necessarily prohibitive, associated morbidity and mortality, especially when considering the overall risk profile of the patients being offered this type of intervention.

Current role in TAAA Management

Based on the available literature and our clinical experience, careful patient selection is key. Although hybrid repairs may allow high-risk patients to have outcomes equal to those published from administrative surgical databases, they do not approach those reported at select centers of excellence with significant expertise in open TAAA repair, even when the hybrid repairs are performed at the same high volume centers. Although they may offer a viable alternative

for patients at slightly higher than average operative risk, or for those who have isolated high risk comorbidities (i.e. chronic lung disease), patients who are deemed unfit for open TAAA repair are likely unfit for hybrid repair as well.

Not all "high-risk" patients, however, are the same. In relatively healthy individuals who are considered high risk due to anatomic features, the hybrid approach offers a reasonable treatment option. In fact, hybrid repair may have the most to offer as a re-operative approach to recurrent TAAA. By allowing the surgeon to avoid densely scarred operative fields and obliterated tissue planes, the hybrid approach facilitates repair for individuals who would otherwise not have a viable open approach to their pathology. This is best demonstrated by both the Duke and UCLA experiences, in which they reported outstanding outcomes in a cohort for which the hybrid repair constituted a repeat aortic operation (55% to 60% of the patients) [19, 30]. This has been reinforced by our experience, in which the best outcomes are achieved in patients who have specific anatomic reasons that make them unsuitable

for open TAAA repair.

In the end, it is clear that despite many theoretical advantages, and the impression that it is less invasive than standard open TAAA repair, hybrid repair is still a significant undertaking with real risks of associated morbidity and mortality. Although there is a clear role for hybrid repair in patients who are good physiological candidates for operative intervention, but have specific anatomical challenges that preclude traditional open repair, hybrid repair has little to offer for the true physiologically high-risk patient. It should be remembered that hybrid repair is no less of an operation than traditional open repair, it is just a different one.

Conflict of Interest

The authors have no conflict of interest relevant to this publication.

Comment on this Article or Ask a Question

References

- Lemaire SA, Price MD, Green SY, Zarda S, Coselli JS. Results of open thoracoabdominal aortic aneurysm repair. *Ann Cardiothorac Surg.* 2012;1:286–292. DOI: [10.3978/j.issn.2225-319X.2012.08.16](https://doi.org/10.3978/j.issn.2225-319X.2012.08.16)
- Estrera AL, Sheinbaum R, Miller CC, Harrison R, Safi HJ. Neuromonitor-guided repair of thoracoabdominal aortic aneurysms. *J Thorac Cardiovasc Surg.* 2010;140(6 Suppl):S131–S136. DOI: [10.1016/j.jtcvs.2010.07.058](https://doi.org/10.1016/j.jtcvs.2010.07.058)
- Cowan JA, Dimick JB, Henke PK, Huber TS, Stanley JC, Upchurch GR. Surgical treatment of intact thoracoabdominal aortic aneurysms in the United States: Hospital and surgeon volume-related outcomes. *J Vasc Surg.* 2003;37:1169–1174. DOI: [10.1016/S0741-5214\(03\)00085-5](https://doi.org/10.1016/S0741-5214(03)00085-5)
- Reilly LM, Rapp JH, Grenon SM, Hiramoto JS, Sobel J, Chuter T, et al. Efficacy and durability of endovascular thoracoabdominal aortic aneurysm repair using the caudally directed cuff technique. *J Vasc Surg.* 2012;56:53–64. DOI: [10.1016/j.jvs.2012.01.006](https://doi.org/10.1016/j.jvs.2012.01.006)
- Guillou M, Bianchini A, Sobocinski J, Maurel B, D'elia P, Tyrrell M, et al. Endovascular treatment of thoracoabdominal aortic aneurysms. *J Vasc Surg.* 2012;56:65–73. DOI: [10.1016/j.jvs.2012.01.008](https://doi.org/10.1016/j.jvs.2012.01.008)
- Greenberg R, Eagleton M, Mastracci T. Branched endografts for thoracoabdominal aneurysms. *J Thorac Cardiovasc Surg.* The American Association for Thoracic Surgery; 2010;140(6 Suppl):S171–S178. DOI: [10.1016/j.jtcvs.2010.07.061](https://doi.org/10.1016/j.jtcvs.2010.07.061)
- Quinones-Baldrich WJ, Panetta TF, Vescera CL, Kashyap VS. Repair of type IV thoracoabdominal aneurysm with a combined endovascular and surgical approach. *J Vasc Surg.* 1999;30(October 1997):555–560. DOI: [10.1016/S0741-5214\(99\)70084-4](https://doi.org/10.1016/S0741-5214(99)70084-4)
- Canaud L, Karthikesalingam A, Jackson D, Cresswell L, Cliff M, Markar SS, et al. Clinical outcomes of single versus staged hybrid repair for thoracoabdominal aortic aneurysm. *J Vasc Surg.* 2013;58:1192–1200. DOI: [10.1016/j.jvs.2013.04.061](https://doi.org/10.1016/j.jvs.2013.04.061)
- Drinkwater SL, Böckler D, Eckstein H, Cheshire NJW, Kotelis D, Wolf O, et al. The visceral hybrid repair of thoraco-abdominal aortic aneurysms—a collaborative approach. *Eur J Vasc Endovasc Surg.* 2009;38:578–585. DOI: [10.1016/j.ejvs.2009.07.002](https://doi.org/10.1016/j.ejvs.2009.07.002)
- Black SA, Wolfe JHN, Clark M, Hamady M, Cheshire NJW, Jenkins MP. Complex thoracoabdominal aortic aneurysms: Endovascular exclusion with visceral revascularization. *J Vasc Surg.* 2006;43:1081–1089. DOI: [10.1016/j.jvs.2005.12.071](https://doi.org/10.1016/j.jvs.2005.12.071)
- Donas KP, Lachat M, Rancic Z, Oberkofler C, Pfammatter T, Guber I, et al. Early and mid-term outcome of a novel technique to simplify the hybrid procedures in the treatment of thoracoabdominal and pararenal aortic aneurysms. *J Vasc Surg.* 2009;50:1280–1284. DOI: [10.1016/j.jvs.2009.06.053](https://doi.org/10.1016/j.jvs.2009.06.053)
- Hughes GC, Andersen ND, Hanna JM, McCann RL. Thoracoabdominal aortic aneurysm: Hybrid repair outcomes. *Ann Cardiothorac Surg.* 2012;1:311–9. DOI: [10.3978/j.issn.2225-319X.2012.08.13](https://doi.org/10.3978/j.issn.2225-319X.2012.08.13)
- Kabbani LS, Criado E, Upchurch GR, Patel HJ, Eliason JL, Rectenwald J, et al. Hybrid repair of aortic aneurysms involving the visceral and renal vessels. *Ann Vasc Surg.* 2010;24:219–224. DOI: [10.1016/j.avsg.2009.08.007](https://doi.org/10.1016/j.avsg.2009.08.007)
- Kuratani T, Kato M, Shirakawa Y, Shimamura K, Sawa Y. Long-term results of hybrid endovascular repair for thoraco-abdominal aortic aneurysms. *Eur J Cardiothorac Surg.* 2010;38:299–304. DOI: [10.1016/j.ejcts.2010.02.013](https://doi.org/10.1016/j.ejcts.2010.02.013)

15. Lee WA, Brown MP, Martin TD, Seeger JM, Huber TS. Early results after staged hybrid repair of thoracoabdominal aortic aneurysms. *J Am Coll Surg.* 2007;205:420–431. DOI: [10.1016/j.jamcollsurg.2007.04.016](https://doi.org/10.1016/j.jamcollsurg.2007.04.016)
16. Massoni CB, Geisbsoch P, Gallitto E, Hakimi M, Gargiulo M, Bockler D. Follow-up outcomes of hybrid procedures for thoracoabdominal aortic pathologies with special focus on graft patency and late mortality. *J Vasc Surg.* 2014;59:1265–1273. DOI: [10.1016/j.jvs.2013.11.064](https://doi.org/10.1016/j.jvs.2013.11.064)
17. Patel HJ, Upchurch GR, Eliason JL, Criado E, Rectenwald J, Williams DM, et al. Hybrid debranching with endovascular repair for thoracoabdominal aneurysms: A Comparison with open repair. *Ann Thorac Surg.* 2010;89:1475–1481. DOI: [10.1016/j.athoracsur.2010.01.062](https://doi.org/10.1016/j.athoracsur.2010.01.062)
18. Patel R, Conrad MF, Paruchuri V, Kwolek CJ, Chung TK, Cambria RP. Thoracoabdominal aneurysm repair: Hybrid versus open repair. *J Vasc Surg.* 2009;50:15–22. DOI: [10.1016/j.jvs.2008.12.051](https://doi.org/10.1016/j.jvs.2008.12.051)
19. Quinones-Baldrich W, Jimenez JC, DeRubertis B, Moore WS. Combined endovascular and surgical approach (CESA) to thoracoabdominal aortic pathology: A 10-year experience. *J Vasc Surg.* 2009;49:1125–1134. DOI: [10.1016/j.jvs.2008.12.003](https://doi.org/10.1016/j.jvs.2008.12.003)
20. Rosset E, Ben Ahmed S, Galvaing G, Favre JP, Sessa C, Lermusiaux P, et al. Editor's Choice- Hybrid treatment of thoracic, thoracoabdominal, and abdominal aortic aneurysms: A multicenter retrospective study. *Eur J Vasc Endovasc Surg.* 2014;47:470–478. DOI: [10.1016/j.ejvs.2014.02.013](https://doi.org/10.1016/j.ejvs.2014.02.013)
21. Smith TA, Gatens S, Andres M, Modrall JG, Clagett GP, Arko FR. Hybrid repair of thoracoabdominal aortic aneurysms involving the visceral vessels: comparative analysis between number of vessels reconstructed, conduit, and gender. *Ann Vasc Surg.* 2011;25:64–70. DOI: [10.1016/j.avsg.2010.06.004](https://doi.org/10.1016/j.avsg.2010.06.004)
22. Tshomba Y, Melissano G, Logaldo D, Rinaldi E, Bertoglio L, Civilini E, et al. Clinical outcomes of hybrid repair for thoracoabdominal aortic aneurysms. *Ann Cardiothorac Surg.* 2012;1:293–303. DOI: [10.3978/j.issn.2225-319X.2012.07.15](https://doi.org/10.3978/j.issn.2225-319X.2012.07.15)
23. Van de Mortel RHW, Vahl AC, Balm R, Buth J, Hamming JF, Schurink GWH, et al. Collective experience with hybrid procedures for suprarenal and thoracoabdominal aneurysms. *Vascular.* 2008;16:140–146. DOI: [10.2310/6670.2008.00017](https://doi.org/10.2310/6670.2008.00017)
24. Zhou W, Reardon M, Peden EK, Lin PH, Lumsden AB. Hybrid approach to complex thoracic aortic aneurysms in high-risk patients: Surgical challenges and clinical outcomes. *J Vasc Surg.* 2006;44:688–693. DOI: [10.1016/j.jvs.2006.06.013](https://doi.org/10.1016/j.jvs.2006.06.013)
25. Shahverdyan R, Gawenda M, Brunkwall J. Five-year patency rates of renal and visceral bypasses after abdominal debranching for thoraco-abdominal aortic aneurysms. *Eur J Vasc Endovasc Surg.* 2013;45:648–656. DOI: [10.1016/j.ejvs.2013.03.012](https://doi.org/10.1016/j.ejvs.2013.03.012)
26. Lancaster RT, Conrad MF, Patel VI, Cambria MR, Ergul EA, Cambria RP. Further experience with distal aortic perfusion and motor-evoked potential monitoring in the management of extent I-III thoracoabdominal aortic aneurysms. *J Vasc Surg.* 2013;58:283–290. DOI: [10.1016/j.jvs.2013.01.042](https://doi.org/10.1016/j.jvs.2013.01.042)
27. Oderich GS, Timaran C, Farber M, Quinones-Baldrich W, Escobar G, Glociczki P, et al. RR14. Spinal cord injury after hybrid endovascular repair of thoracoabdominal aortic aneurysms in the North American Complex Abdominal Aortic Debranching (NACAAD) Registry. *J Vasc Surg.* 2012;55 (6 Suppl):93S – 94S. DOI: [10.1016/j.jvs.2012.03.223](https://doi.org/10.1016/j.jvs.2012.03.223)
28. Rigberg D a, McGory ML, Zingmond DS, Maggard M a, Agustin M, Lawrence PF, et al. Thirty-day mortality statistics underestimate the risk of repair of thoracoabdominal aortic aneurysms: A statewide experience. *J Vasc Surg.* 2006;43:217–223. DOI: [10.1016/j.jvs.2005.10.070](https://doi.org/10.1016/j.jvs.2005.10.070)
29. Moulakakis KG, Mylonas SN, Antonopoulos CN, Liapis CD. Combined open and endovascular treatment of thoracoabdominal aortic pathologies: A systematic review and meta-analysis. *Ann Cardiothorac Surg.* 2012;1:267–276. DOI: [10.3978/j.issn.2225-319X.2012.08.02](https://doi.org/10.3978/j.issn.2225-319X.2012.08.02)
30. Hughes GC, Barfield ME, Shah A a, Williams JB, Kuchibhatla M, Hanna JM, et al. Staged total abdominal debranching and thoracic endovascular aortic repair for thoracoabdominal aneurysm. *J Vasc Surg.* 2012;56:621–629. DOI: [10.1016/j.jvs.2011.11.149](https://doi.org/10.1016/j.jvs.2011.11.149)

Cite this article as: Damrauer SM, Fairman RM. Visceral Debranching for the Treatment of Thoracoabdominal Aortic Aneurysms. *AORTA* 2015;3(2):67-74. DOI: <http://dx.doi.org/10.12945/j.aorta.2015.14-066>