

# How Do You Manage the Diaphragm During Open Thoracoabdominal Interventions on the Aorta?

Bulat A. Ziganshin

(on behalf of the Editorial Office)

## Key Words

**Thoracoabdominal aortic aneurysm · Diaphragm management**

With this article, we would like to introduce, starting from the inaugural issue of the *Aorta* journal, our special feature, “Ask the Editors.” In this feature, the readers have the opportunity to ask questions of the editors in any of the topic categories of the journal. One or several editors will reply, presenting their expert opinions. This is an opportunity to get detailed answers to difficult questions; questions will be selected to be of general interest to readers of *Aorta*.

For the first issue the question is:

**How do you manage the diaphragm during open thoracoabdominal interventions on the aorta?**

- (A) Radial incision (Fig. 1)
- (B) Circumferential incision (Fig. 2)
- (C) No incision, enlargement of the hiatus without disturbing the diaphragm

We asked two renowned experts in the field to respond to this question and share their extensive experience with the readers.

*Professor Michael Jacobs*

(Chairman, Department of Surgery, Maastricht University Medical Center, The Netherlands)

*I routinely make a limited circumferential incision (response B) of 8–10 cm to allow opening and exposure of the thoracic and abdominal aorta. In addition, I open the hiatus and put a sling around the remaining part of*

*the diaphragm. This sling can be pulled up and aside to expose the aorta from all directions. The majority of the diaphragm remains intact.*

*Professor Anthony L. Estrera*

(Department of Cardiothoracic and Vascular Surgery, The University of Texas Medical School at Houston, USA)

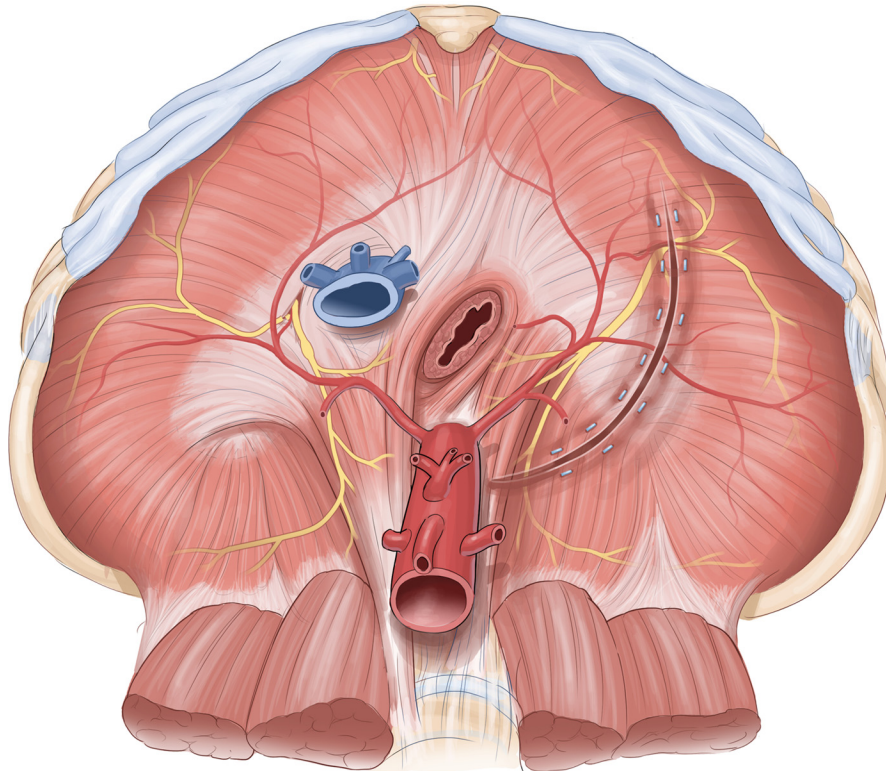
*I manage the diaphragm during thoracoabdominal aortic aneurysm repair with an incomplete circumferential incision (B). The incision length is based on how much exposure is required. This incision was adopted based on work performed by our group in 1999. (Engle J, Safi HJ, Miller CC 3rd, Campbell MP, Harlin SA, Letsou GV, Lloyd MD KS, Root DB: The impact of diaphragm management on prolonged ventilator support after thoracoabdominal aortic repair. *J Vasc Surg.* 1999 Jan;29(1):150–156.) This demonstrated improved pulmonary outcomes with the incomplete circumferential incision.*

We encourage the readers to submit their questions to the editors of *Aorta*. We will ask an expert in the field to provide a response and publish it in a subsequent issue.

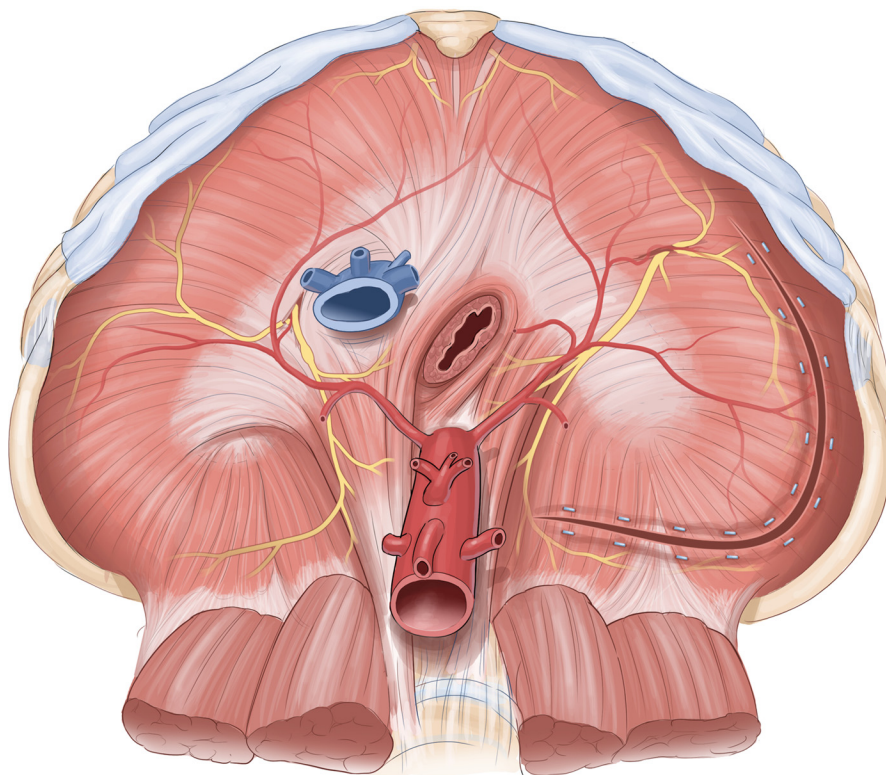
## Comment on this Article or Ask a Question

**Cite this article as:** Ziganshin BA. How Do You Manage the Diaphragm During Open Thoracoabdominal Interventions on the Aorta?. *Aorta* 2013;1(1):67–68. DOI: <http://dx.doi.org/10.12945/j.aorta.2013.13.021>





**Figure 1.** Radial incision of the diaphragm.



**Figure 2.** Circumferential incision of the diaphragm.