

Life-Threatening Surgery for Mycotic Aneurysm

Zan K. Mitrev, MD, FETCS*, Tanja N. Anguseva, MD

Special Hospital for Surgery "FILIP II", Skopje, Macedonia

Abstract

Infected aneurysm (or mycotic aneurysm) is defined as an infectious disease of the wall of an artery with formation of a blind, saccular out-pouching that is contiguous with the arterial lumen. Symptoms are frequently absent or nonspecific during the early stages. Once clinically presented, infected aneurysms are often at an advanced stage of development and associated with complications such as rupture. Nontreatment or delayed treatment of infected aneurysms has a poor outcome, with high morbidity and mortality rate via fulminant sepsis or hemorrhage. In clinically suspected cases, computed tomography is used for diagnosis. Urgent surgery, performed to prevent aortic rupture carries high morbidity and mortality rates.

Copyright © 2013 Science International Corp.

Key Words

Mycotic aneurysm · Surgical treatment · Aorta

Introduction

Mycotic aneurysm is a serious clinical condition with significant morbidity and mortality. It is defined as an infectious disease of the wall of an artery with formation of a blind, saccular out-pouching that is contiguous with the arterial lumen [1]. Early detection of a mycotic aortic aneurysm is essential for rapid and efficacious initial treatment and, therefore, for an improved prognosis.

The prevalence of infected aortic aneurysms among aortic aneurysms is 0.7%–1% [2]; 7%–24% demonstrate spontaneous rupture, and a further 47%–61% demonstrate contained or impending rup-

ture at presentation. Spontaneously ruptured infected aortic aneurysms have 63%–100% mortality [2].

The most common sites for mycotic aneurysm are: thoracic and abdominal aorta, abdominal visceral arteries, lower extremity arteries, and intracranial arteries (typically, there are more peripheral than berry aneurysms).

Only 7% of patients are asymptomatic [2]. Infected thoracic aortic aneurysms usually manifest chest and interscapular pain.

Prolonged culture-specific antibiotic therapy in combination with conventional surgery or endovascular techniques is advocated for successful treatment of infected aneurysms [3]. Intravenous antibiotic therapy is commonly given for the initial 4-6 weeks.

Case Report

We present the case of a 24-year-old female, who was referred to our hospital with an 8 month history of chest and back pain, cough, voice changes, slightly elevated body temperature, headaches, and occasional breathing difficulties. During this period the patient was treated for pneumonia at the University Clinic for Pulmonology.

On admission, her temperature was normal. Blood examination showed a white blood cell count of 1000, C-reactive protein level of 36.74 mg/dL, IgA level of 11.58 g/L and IgG level of 13.87 g/L. Cardiac enzymes and renal function were within normal range. Computed tomography disclosed a giant aneurysm of the



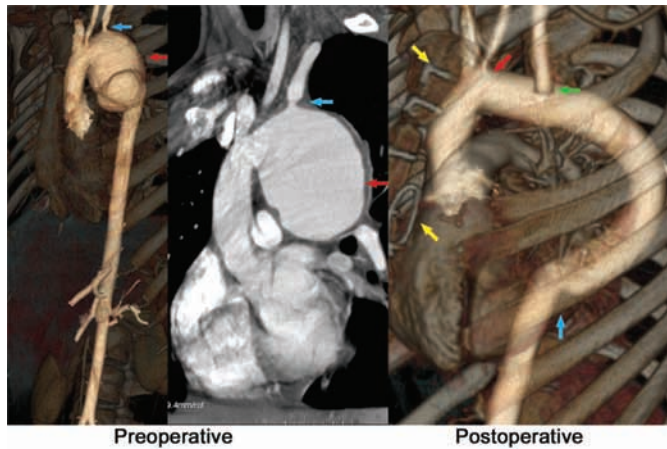


Figure 1. (Left panel) Preoperative computed 3D image of aorta with a giant aneurysm of the aortic arch and proximal thoracic aorta, with irregular arterial wall, periaortic edema, periaortic soft-tissue mass (**red arrow**), and stenosis of left subclavian artery outflow (**blue arrow**). (Right panel) Postoperative 3D image of the replaced arch and descending thoracic aorta (vascular prosthesis) and with proximal anastomosis (**red arrow**), distal anastomosis (**blue arrow**), and reimplanted left subclavian artery with Dacron interposition graft (**green arrow**); sternal wires on the anterior and left lateral thoracotomy (**yellow arrow**).

aortic arch and descending aorta with suspected mycotic (infective) etiology (Fig. 1).

After admission, the patient was treated for one week with intravenous antibiotics (ampicillin IV) and antifungals (difluconazol) prior to surgery. Her blood results showed increased leukocytes and procalcitonin, as well as immunology markers. Gram-negative bacteria (*Enterococcus fecium*), were found in the patient's sputum.

After a week of medical treatment, in a completely hemodynamically stable condition with normalized laboratory parameters, the patient was operated. After sternotomy with left anterior thoracotomy (in the third intercostal space), cannulation of the right subclavian, right femoral artery, and the right atrium was performed. The hemiarch and the descending aorta were replaced with vascular prosthesis and the left subclavian artery was reimplanted using a Dacron interposition graft (Fig. 1). Pathohistological analysis confirmed, the mycotic (infective) etiology of the aneurysm, showing compressed perivascular tissue, hematoma, and fibroinflammatory tissue with abundant polymorphonuclears. The patient was discharged on the 9th postoperative day.

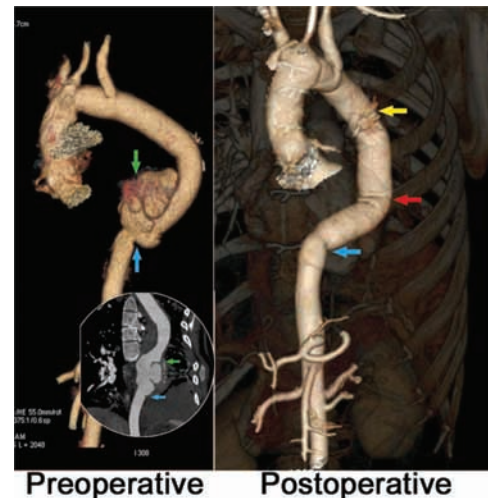


Figure 2. (Left panel) Preoperative 3D and angiographic image of pseudoaneurysm with contained rupture (**green arrow**) on the previously placed prosthesis and distal anastomosis (**blue arrow**). (Right panel) Postoperative 3D image of the replaced descending thoracic aorta with proximal anastomosis on the previous prosthesis (**red arrow**). Distal anastomosis with the thoracic aorta (**blue arrow**), place of cannulation of the prosthesis (**yellow arrow**).

Six months after surgery she was on continuous antibiotics (amoxiclav) and antimycotics (difluconazol) as oral treatment.

Nine months later the same patient was urgently admitted in hemorrhagic shock with chest and back pain, breathlessness, hematemesis, and melena. A rupture of the thoracic aorta at the distal anastomosis was detected by computerized tomography, with suspicion for recurrence of the previous disease (Fig. 2). Laboratory parameters favored infection.

Under reanimation, as a life-saving procedure, urgent reoperation was performed with extracorporeal circulation through the left external iliac artery and vein. Through left anterolateral thoracotomy at the level of the fourth intercostal space, the proximal part of the previously placed vascular prosthesis was urgently cannulated and the thoracic aorta was clamped proximally and distally from the site of rupture. At the site of the distal anastomosis from the previous surgery, a split of the half-circumference of the aorta with massive bleeding into the pulmonary parenchyma and the left pleura was found.

In a condition of normothermia with beating heart, the distal part of the thoracic aorta was replaced with a Dacron prosthesis (Fig. 2).

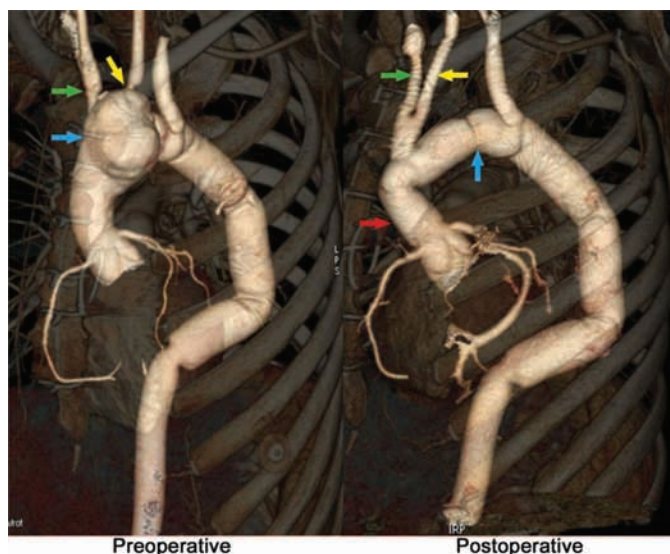


Figure 3. (Left panel) Preoperative 3D topographical image of newly formed aneurysm (blue arrow) on the ascending aorta and the arch involving the outflow of brachiocephalic trunk (green arrow) and ostial stenosis of the left common carotid artery (yellow arrow). (Right panel) Postoperative 3D topographical preview of the replaced ascending aorta (red arrow) and complete arch to the previous prosthesis (blue arrow) with Y prosthesis up to the brachiocephalic trunk (green arrow) and the left common carotid artery (yellow arrow).

Postoperatively, the patient was in a coma with delayed awakening. She was weaned from the respirator on the 21st day; (percutaneous tracheostomy and gastrostomy had been placed). Gram-negative bacteria (*Enterococcus fecium*) were cultured in her sputum for the second time. The tracheotomy cannula was removed on the 21st postoperative day. The patient had transitory mild hemiparesis that resolved completely and the patient was discharged after 30 days of hospitalization. She was on antibiotic and antimycotic treatment (according to antibiogram) in the next 7 months.

In the meantime the patient continuously displayed clinical signs of iridocyclitis. Therefore, suspecting vasculitic etiology, we noted increased IgG and IgA levels, but rheumatology tests for antinuclear antibodies and anti-DNA were negative.

Eight months after the second surgery, the patient complained of chest pain, dry cough, slightly increased temperature, and pain in the neck. Computed tomography verified a new aneurysm of the aortic arch, indicating a new relapse (Fig. 3). Therefore, urgent surgical treatment was undertaken.

The surgery was performed following arterial cannulation of the right subclavian and right femoral arteries and cannulation of the right femoral vein up to the right atrium. Under hypothermia of 31°C, a complete replacement of the aortic arch up to the previously placed prosthesis was made. Then a supra-coronary replacement of the ascending aorta was performed and through Y prosthesis the brachiocephalic trunk and the left carotid artery were reimplanted (Fig. 3). With normal postoperative progress, the patient was discharged on the 12th day.

Gram-negative bacteria in the patient's sputum were confirmed as enterococcal bacteria. She was treated with antibiotics for the next 4 months.

For the first time, 6 months after the third operation, the patient was without clinical signs for iridocyclitis and the immunologic parameters decreased to a normal range.

Discussion

Although the first mycotic aneurysm was reported in 1885 by Sir William Osler for fungal vegetations in the aortic arch complicated by endocarditis, mycotic aneurysm remains one of the most life-threatening conditions in the field of vascular surgery [1,4]. Essentially, three mechanisms of development of mycotic aortic aneurysm have been described; namely, septic embolization (usually is secondary to bacterial endocarditis); direct or lymphatic spread from an adjacent infected focus; and hematogenous seeding of the arterial wall during bacteremia from a distant focus [1,5].

Our patient presented with episodes of immunological hyperactivity, fever, and chest pain that were suppressed with antibiotic therapy, but recurred quickly once treatment was withdrawn. She had combined iridocyclitis with significantly increased immunological markers. Microbiology of her sputum showed Gram-negative bacteria (enterococcus), which suggests pneumonia as a probable origin for direct spread of the infection on to the thoracic aorta, which further triggered the patient's immunoactivity, resulting in aneurysmatic changes of the aortic tissue.

As already mentioned in the Introduction, the conventional strategy for treatment of mycotic aneurysm is prompt surgical intervention followed by long-term antibiotic therapy, which is essential to control systemic sepsis and to achieve cardiovascular stability

[1,6,7]. However, the surgical procedures are associated with substantial mortality rates and risk of recurrent infection, as was the case in our patient. Survival is influenced not by the type of reconstruction but by the status of aneurysmal rupture. In addition, fever presentation indicates a persisting active infection process or inflammation and predicts poor prognosis, even under aggressive treatment.

In the case of severe aortic enlargement, surgery is the treatment of choice. In 25% of the cases a relapse aneurysm occurs on the borderline with the healthy tissue [8]. Our patient, during all three pre-

sentations required emergency surgery: the first and third time with significant enlargement of aortic dimensions, and the second time with a life-threatening shock condition.

In conclusion, the best chance of survival in patients with this difficult condition depends on early computed tomography evaluation and prompt surgical intervention under appropriate and intensive antibiotic therapy.

[Comment on this Article or Ask a Question](#)

REFERENCES

1. Kaufman SL, White RI Jr, Harrington DP, Barth KH, Siegelman SS. Protean manifestations of mycotic aneurysms. *AJR Am J Roentgenol.* 1978;131:1019–1025. [10.2214/ajr.131.6.1019](https://doi.org/10.2214/ajr.131.6.1019)
2. Hsu RB, Chen RJ, Wang SS, Chu SH. Infected aortic aneurysms: clinical outcome and risk factor analysis. *J Vasc Surg.* 2004;40:30–35. [10.1016/j.jvs.2004.03.020](https://doi.org/10.1016/j.jvs.2004.03.020)
3. Lesèche G, Castier Y, Petit MD, Bertrand P, Kitzis M, Mussot S, et al. Long-term results of cryopreserved arterial allograft reconstruction in infected prosthetic grafts and mycotic aneurysms of the abdominal aorta. *J Vasc Surg.* 2001;34:616–622. [10.1067/mva.2001.116107](https://doi.org/10.1067/mva.2001.116107)
4. Miller DV, Oderich GS, Aubry MC, Panneton JM, Edwards WD. Surgical pathology of infected aneurysms of the descending thoracic and abdominal aorta: clinicopathologic correlations in 29 cases (1976 to 1999). *Hum Pathol.* 2004;35:1112–1120. [10.1016/j.humpath.2004.05.013](https://doi.org/10.1016/j.humpath.2004.05.013)
5. McCready RA, Bryant MA, Divelbiss JL, Chess BA, Chitwood RW, Paget DS. Arterial infections in the new millennium: an old problem revisited. *Ann Vasc Surg.* 2006;20:590–595. [10.1007/S10016-006-9107-y](https://doi.org/10.1007/S10016-006-9107-y)
6. Malouf JF, Chandrasekaran K, Orszulak TA. Mycotic aneurysms of the thoracic aorta: a diagnostic challenge. *Am J Med.* 2003;115:489–496. [10.1016/S0002-9343\(03\)00394-2](https://doi.org/10.1016/S0002-9343(03)00394-2)
7. Brown SL, Busuttill RW, Baker JD, Machleder HI, Moore WS, Barker WF. Bacteriologic and surgical determinants of survival in patients with mycotic aneurysms. *J Vasc Surg.* 1984;1:541–547. [10.1067/mva.1984.avs0010541](https://doi.org/10.1067/mva.1984.avs0010541)
8. Chen YF, Lin PY, Yen HW, Lin CC. Double mycotic aneurysms of the ascending aorta. *Ann Thorac Surg.* 1997;63:529–531. [10.1016/S0003-4975\(96\)00904-6](https://doi.org/10.1016/S0003-4975(96)00904-6)

Cite this article as: Mitrev ZK, Anguseva TN. Life-Threatening Surgery for Mycotic Aneurysm. *Aorta* 2013;1(3):193–197. DOI: <http://dx.doi.org/10.12945/j.aorta.2013.13-017>

EDITOR'S COMMENTS AND QUESTIONS

Editor's Comment:

The authors are to be commended for advanced heroic treatment of a very challenging case. Furthermore, this case is valuable as an illustration of subsequent care beyond the original operation.

Editor's Questions:

1. Were the blood cultures positive? Were aortic tissue cultures positive? Were bacteria seen in the surgical specimen?

We did not isolate positive blood cultures from this patient. Aortic tissue cultures were also negative. But according to the literature, in 60%–70% of patients, blood cultures are negative, and even in the aortic tissue, cultures are negative in 25% of cases [1].

The diagnosis of an infected aneurysm was established by clinical and operative findings, including

pathological findings of the aortic wall [with pathohistological report, mycotic (infective) etiology of the aneurysm was confirmed, resulting in compressed perivascular tissue, hematoma, and fibroinflammatory tissue with plenty of polymorphonuclears]. Essentially, three mechanisms of mycotic aortic aneurysm have been implicated, namely, septic embolization that usually is secondary to bacterial endocarditis; direct or lymphatic spread from an adjacent infected focus; and hematogenous seeding of the arterial wall during bacteremia from a distant focus. In our patient's clinical expression, in situ aortic morphology and the pathohistological result were positive for mycotic (infective) aneurysm.

The only positive microbiology result was from the patient's sputum for enterobacter species, which we suppose was residual from previous pneumonia, which triggered the patient's total inflammatory system response.

2. Why was antifungal treatment administered? *The management of mycotic aneurysms requires*

eradication of the source of infection and maintenance of distal arterial flow. Surgery is almost always indicated, since mortality for untreated patients is greater than 90%. Bactericidal medications with a broad spectrum antibiotic and antifungal activity should be started immediately once the diagnosis has been made. Adjustments in antibiotic selection can be made following sensitivity results. Antibiotics should be continued postoperatively for a minimum of 6-8 weeks, or oral antibiotics may be required for a lifetime, as it was in our case. We isolated *Enterococcus faecium* and *Candida* from the patient's sputum. After the third reoperation the patient was relieved from antibiotics and antimycotics [2].

3. Did you consider wrapping the anastomosis with omentum to capitalize on the special ability of the omentum to heal and prevent infection?

No, we did not consider this due to small, but real risk of myocardial compression resulting in bulky omental tissue occupying pericardial and/or anterior mediastinal space, during the first and the third operation while the aneurysm was on the aortic arch and ascending aorta. During the second operation, the patient underwent life-threatening surgery, due to rupture of the aorta, so the emergent nature of the surgery did not allow usage of omental wrapping. Otherwise, due to hemorrhagic shock, all the tissues were ischemic, even the patient's omentum.

REFERENCES

1. Inafuku H, Senaha S, Morishima Y, Nagano T, Arakaki K, Yamashiro S, et al. Infected thoracoabdominal aortic aneurysms including the major abdominal branches in 4 Cases. *Ann Thorac Cardiovasc Surg.* 2008; 14:196–199.
2. Mahesh B, Caputo M, Angelini GD, Bryan AJ. Treatment of an aortic fungal false aneurysm by composite stentless porcine/pericardial conduit: a case report. *Cardiovasc Surg.* 2003; 11:93–95. [10.1016/S0967-2109\(02\)00140-0](https://doi.org/10.1016/S0967-2109(02)00140-0)