

## Platelet-rich plasma in the treatment of acute hamstring injuries in professional football players

GIACOMO ZANON<sup>1</sup>, FRANCO COMBI<sup>2</sup>, ALBERTO COMBI<sup>3</sup>, LORIS PERTICARINI<sup>4</sup>,  
LUIGI SAMMARCHI<sup>5</sup>, FRANCESCO BENAZZO<sup>6</sup>

<sup>1</sup> Clinica Ortopedica e Traumatologica, Università degli Studi di Pavia - Fondazione IRCCS Policlinico San Matteo, Pavia, Italy

<sup>2</sup> Athletics National Team Physician, Milan, Italy

<sup>3</sup> Clinica Ortopedica e Traumatologica, Università degli Studi di Pavia - Fondazione IRCCS Policlinico San Matteo, Pavia, Italy

<sup>4</sup> Clinica Ortopedica e Traumatologica, Università degli Studi di Pavia - Fondazione IRCCS Policlinico San Matteo, Pavia, Italy

<sup>5</sup> Department of Radiology, Fondazione IRCCS Policlinico San Matteo, Pavia, Italy

<sup>6</sup> Clinica Ortopedica e Traumatologica, Università degli Studi di Pavia - Fondazione IRCCS Policlinico San Matteo, Pavia, Italy

### Abstract

**Purpose:** muscle injuries have a high incidence in professional football and are responsible for the largest number of days lost from competition. Several *in vitro* studies have confirmed the positive role of platelet-rich plasma (PRP) in accelerating recovery and in promoting muscle regeneration, and not fibrosis, in the healing process. This study examines the results of intralesional administration of PRP in the treatment of primary hamstring injuries sustained by players belonging to a major league football club.

**Methods:** twenty-five hamstring injuries (grade 2 according to MRI classification) sustained by professional football players during a 31-months observation period were treated with PRP and analyzed. Sport participation absence (SPA), in days, was considered to correspond to the healing time, and we also considered the re-injury rate, and tissue healing on MRI. The mean follow-up was 36.6 months (range 22-42).

**Results:** there were no adverse events. The mean SPA for the treated muscle injuries was  $36.76 \pm 19.02$  days. The re-injury rate was 12%. Tissue healing, evaluated on MRI, was characterized by the presence of excellent repair tissue and a small scar.

**Conclusions:** this study confirmed the safety of PRP

in treating hamstring lesions in a large series of professional football players. PRP-treated lesions did not heal more quickly than untreated lesions described in the literature, but they showed a smaller scar and excellent repair tissue.

**Level of evidence:** Level IV, therapeutic case series.

**Keywords:** football, hamstring healing, injuries, muscle, platelet-rich plasma.

### Introduction

Muscle injuries are the most common injuries in modern sports traumatology. They are particularly common in football, accounting for 31% of all injuries sustained by professional male soccer players (1, 2). In general, return to competition after these injuries requires less time than after tendon or ligament injuries, however, because of their high frequency, muscle injuries are responsible for the largest number of days lost from competition by football players: they account for 27-37% of the total time away from competition due to injury (2, 3).

A professional football club, to pursue its sporting and business objectives, needs to be able to count on the availability of all its players; therefore, club physicians, as well as implementing prevention protocols, have to ensure that injured players can return to the field as quickly as possible without impaired function. The prevention of re-injuries is crucial too, given that these lead to even longer lay-offs (1, 3-5).

### Corresponding Author:

Loris Peticarini, MD

Department of Orthopaedics and Traumatology, IRCCS Policlinico San Matteo

Viale Golgi 19, 27100 Pavia, Italy

E-mail: loris.peticarini@gmail.com

In recent years, there has been a growing suggestion that platelet-rich plasma (PRP), used in the treatment of muscle injuries, might be an useful tool for club physicians seeking to address these issues.

When activated, platelets release growth factors (GFs) contained in their  $\alpha$ -granules, such as platelet-derived growth factor (PDGF), transforming growth factor (TGF)- $\beta$ , fibroblast growth factor (FGF), insulin-like growth factor (IGF)-1 and -2, and vascular endothelial growth factor (VEGF) (6-9).

Released in physiological proportions, these GFs could enhance some aspects of myogenesis and mitigate inflammation. FGF and IGF-1 increase the proliferation and fusion of myoblasts and can improve the strength of injured muscle (6). FGF and VEGF stimulate angiogenesis during muscle healing (8). TGF- $\beta$  influences the organization of the extracellular matrix and supports the actions of other GFs (9). PDGF and IGF-1 stimulate mitogenesis of mesenchymal cells and chemotaxis and mitogenesis of fibroblasts. IGF-1 also promotes collagen synthesis and inhibits myoblast apoptosis (10). Gigante et al. (11), in an animal study, showed that PRP can stimulate muscle regeneration, enhance vascularization and reduce fibrosis in the early phase of the healing process and that it does not induce calcification or metaplasia (11).

Despite promising pre-clinical studies, there are no large clinical studies supporting the safety and potential of PRP in modulating muscle healing. Until 2010 it was impossible to conduct clinical studies of the use of PRP in professional athletes as the intramuscular administration of PRP was still one of the practices banned by the World Anti-Doping Agency (WADA). This ban was lifted in 2011 because of the lack of evidence of increased sports performance after intramuscular administration of PRP (12).

In 2010, a consensus protocol drawn up by the International Olympic Committee stated that scientific evidence supporting the use of PRP in the treatment of muscle injuries was weak (13). Nevertheless, the use of PRP in the management of muscle injuries looks set to become widespread.

The aim of our study is to describe the use of PRP in the treatment of hamstring injuries by the medical staff at a top-league professional football club.

## Methods

### *Study design and patient population*

The present study consisted of a cohort of 57 football players from a single top-league football club who were monitored for muscle injuries sustained over a 31-month period (from January 2011 to July 2013). The age, leg dominance and injury circumstances of each injured player were recorded. The medical staff recorded every muscle injury, direct or indirect, on a standard form. Muscle injury was diagnosed on the basis of history, clinical examination, ultrasound (US) examination and magnetic resonance imaging (MRI). In most cases, the injury event was directly witnessed or captured on video. The player was interviewed about the pain location and examined for any ecchymosis. Palpation of the site of injury was performed in order to identify the most painful point and any palpable defect. Active mobility of the relative joints was also evaluated.

US was routinely performed as it provides a quick, first-line instrumental evaluation. It allowed the injury to be located in the muscle and its extent to be evaluated grossly. In addition, an MRI scan was always performed within 24 to 72 hours of the injury event to obtain a precise evaluation of the injury. For this purpose, we used 1.5 Tesla superconductive MRI unit (Magnetom Symphony, Siemens, Erlangen, Germany). Sequences included axial, coronal and sagittal T1- and T2-weighted images with saturation (proton density fat saturation, PDFS) and Short tau inversion recovery (STIR) sequences. STIR sequences have high sensitivity and are helpful for identifying lesions; T2 PDFS sequences instead have lower sensitivity but high spatial resolution. A muscle was considered injured when it showed high signal intensity, as compared with the uninjured side, on STIR images. MRI allowed precise evaluation of the intramuscular location of the injury and also made it possible to quantify the lesion and any surrounding edema or hematoma.

Each lesion was classified using the ultrasound-based classification of Peetrons (14) and the MRI-based one of Stoller (15). We chose to divide grade 2 on the MRI classification into three subcategories because, from our clinical experience, the prognosis of these injuries differs according to the proportion of the muscle

diameter showing loss of muscle fiber integrity:

- grade 2a: loss of muscle fiber integrity involving less than 1/3 of the muscle diameter;
- grade 2b: loss of muscle fiber integrity involving 1/3 to 2/3 of the muscle diameter;
- grade 2c: loss of muscle fiber integrity involving more than 2/3 of the muscle diameter but < 100%.

Only grade 2 hamstring injuries (divided into subcategories a, b and c) were included in the study. Exclusion criteria were: hamstring muscle injuries of a grade other than grade 2, re-injuries or injuries of other muscles. Tendon lesions, avulsions or muscle lesions concomitant with joint sprains were also excluded.

### *Intervention*

All the patients provided informed consent prior to undergoing treatment. A 35-ml sample of venous blood was drawn from the cubital vein into a specimen tube containing K<sub>2</sub>EDTA (spray dried) to prevent early clotting. After collection, the samples were centrifuged for 15 minutes at 1000 rpm to separate the plasma (frosted/cloudy) from the cells (erythrocytes). After separation of the erythrocytes in the lower layer and the buffy coat rich in leucocytes in the upper layer, 2.5-3 ml of PRP was extracted from the layer just above the erythrocytes. After calcium gluconate had been added to the PRP (0.2 ml per ml), the solution was immediately injected into the lesion site. The skin was sterilely draped and the planned injection site was sterilized with a 2% chlorhexidinegluconate solution. A needle was inserted through the skin and directed into the lesion under ultrasonographic guidance.

The first injection was always performed at between 48 and 72 hours after the injury, which corresponds to the early regenerative phase of muscle healing.

Treatment was administered according to the following protocol:

- grade 2a lesions: two injections, the second administered after 7 days ( $\pm 1$  days). MRI at days 14 and 21 after the first injection and at the end of follow-up;
- grade 2b or 2c lesions: three injections, administered at 7 day intervals. MRI at days 14, 21 and 28 after the first injection and at the end of follow-up.

The rehabilitation protocol followed the classification of the lesions. The only precaution required of the football players treated with PRP was that they

observe rest on the day of the injection. The player's progression through the rehabilitation program was decided step by step by the medical staff on the basis of the clinical and radiological evidence of healing on the US and MRI examinations.

### *Outcome measurements*

Every patient was prospectively monitored to allow recording of the time taken to heal. The mean follow-up was 36.6 months (range 22-42).

Both MRI and US were employed to evaluate the healing process, looking for the following features: reduced vascularity and a progressive reduction of T2 signal intensity, tissue repair resulting in the formation of a stable scar, and reduction of the surrounding oedema or hematoma. All the MRI studies were analyzed by two radiologists to classify the injuries. There were no instances of differences in interpretation that caused a change in grading and consequently in the therapeutic indication. On this basis, it was deemed that there was no intra- and inter-individual variability between the observers.

From a clinical standpoint, a patient was considered healed when he was once again available to play. Thus, sport participation absence (SPA), in days, was considered to correspond to the time necessary for healing (16). This time includes the time devoted to rehabilitation and to reconditioning, i.e. regaining complete fitness and sport-specific skills.

New injuries sustained, during the follow-up period, in any muscle site affected by an index injury were considered re-injuries.

Continuous data were reported as mean and standard deviation (SD) and as frequency and percentage when categorical.

## **Results**

In the period considered, the squad of 57 footballers had 17,325 hours of total exposure to sporting activity: 14,768 (85.2%) training hours and 2,557 (14.8%) match hours. During this period, 109 muscle injuries were recorded. This corresponds to 1 injury every 159 hours of exposure, and 1.9 injuries per athlete. The total number of hamstring injuries treated was 25, and they occurred in 18 players. The treated players had a

mean age of 24.2 years (range, 18-34 years). The right leg was affected in 13 players (72.2%), the left in 5 (27.8%).

One player was a goalkeeper, 4 were defenders, eight were midfielders, and 5 were forwards. Eight (44.5%) of the players were black and 10 (55.5%) were white. Of the 25 hamstring injuries treated, 21 were in the biceps femoris, in the semimembranosus and one in the semitendinosus. The biceps femoris strains were classified as 2a in 15 cases, 2b in 3 cases and 2c in 3 cases, while the semimembranosus strains were 2a in 2 cases and 2c in 1 case. The only semitendinous lesion was classified as 2a (**Tab. 1**). There were no adverse events.

Overall, the hamstring injuries resulted in a mean SPA of  $36.7 \pm 19$  days. The mean SPA for biceps femoris injuries was  $31.7 \pm 14.3$  days for grade 2a,  $61.3 \pm 8.5$  days for grade 2b, and  $49.3 \pm 13$  days for grade 2c lesions. For the semimembranosus injuries it was  $15.5 \pm 6.4$  days for grade 2a and 69 days for grade 2c lesions. The SPA for the semitendinous injury (grade 2a) was 11 (**Tab. 2**). **Table 3** shows the mean SPA values for each muscle region involved (muscle belly,

myotendinous junction and myofascial region). In each player the last MRI performed showed a minimal muscle scar, disappearance of edema and excellent repair tissue (**Fig. 1**).

**Table 1.** Incidence of hamstring injuries according to the muscle involved.

Injury site	N	%
Biceps femoris	21	84
2a	15	60
2b	3	12
2c	3	12
Semimembranosus	3	12
2a	2	8
2b	-	-
2c	1	4
Semitendinosus	1	4
2a	1	4
2b	-	-
2c	-	-
Overall	25	100
2a	18	72
2b	3	12
2c	4	16

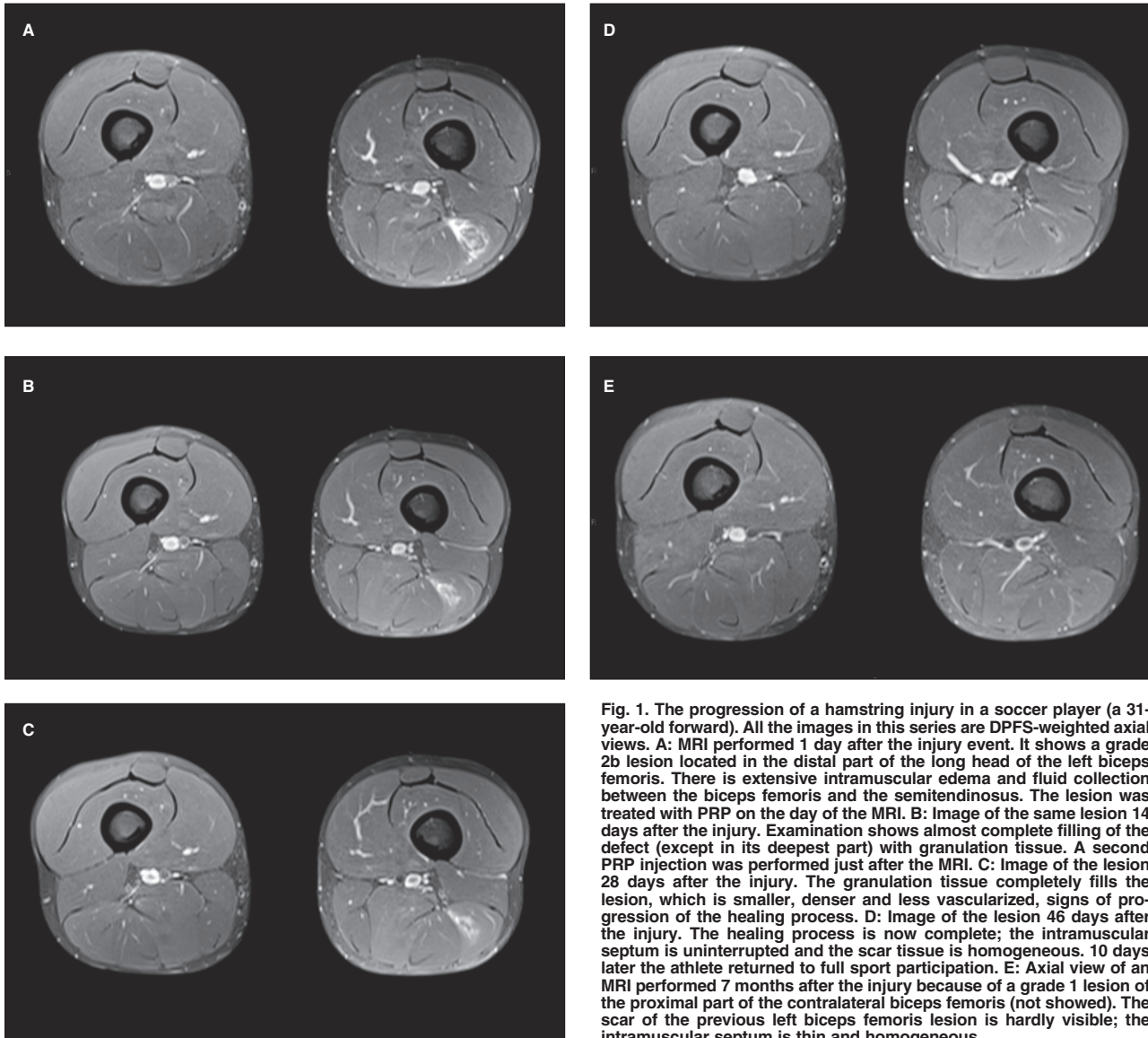
**Table 2.** Mean sport participation absence (days) according to the injury site and grade.

Injury site	Injury grade			Overall
	2a	2b	2c	
Biceps femoris	$28.9 \pm 12.9$	$61.3 \pm 8.5$	$49.3 \pm 13$	<b><math>36.5 \pm 17.3</math></b>
Semimembranosus	$15.5 \pm 6.4$	-	69	<b><math>33.3 \pm 3.2</math></b>
Semitendinosus	11	-	-	<b>11</b>
<b>Overall</b>	<b><math>26.4 \pm 13.1</math></b>	<b><math>61.3 \pm 8.5</math></b>	<b><math>54.2 \pm 14.5</math></b>	<b><math>35.1 \pm 18.9</math></b>

**Table 3.** Mean sport participation absence (days) according to the muscle region involved.

Location	Injury grade			Overall
	2a	2b	2c	
MTJ	N=8 ( $28.4 \pm 15.4$ )	N=3 ( $61.3 \pm 8.5$ )	N=4 ( $54.2 \pm 14.5$ )	N=15 ( $41.9 \pm 20.1$ )
Muscle belly	N=1 (20)	-	-	N=1 (20)
Myofascial region	N=9 ( $25.4 \pm 12.2$ )	-	-	N=9 ( $25.4 \pm 12.9$ )

MTJ = myotendinous junction



**Fig. 1.** The progression of a hamstring injury in a soccer player (a 31-year-old forward). All the images in this series are DPFS-weighted axial views. **A:** MRI performed 1 day after the injury event. It shows a grade 2b lesion located in the distal part of the long head of the left biceps femoris. There is extensive intramuscular edema and fluid collection between the biceps femoris and the semitendinosus. The lesion was treated with PRP on the day of the MRI. **B:** Image of the same lesion 14 days after the injury. Examination shows almost complete filling of the defect (except in its deepest part) with granulation tissue. A second PRP injection was performed just after the MRI. **C:** Image of the lesion 28 days after the injury. The granulation tissue completely fills the lesion, which is smaller, denser and less vascularized, signs of progression of the healing process. **D:** Image of the lesion 46 days after the injury. The healing process is now complete; the intramuscular septum is uninterrupted and the scar tissue is homogeneous. 10 days later the athlete returned to full sport participation. **E:** Axial view of an MRI performed 7 months after the injury because of a grade 1 lesion of the proximal part of the contralateral biceps femoris (not showed). The scar of the previous left biceps femoris lesion is hardly visible; the intramuscular septum is thin and homogeneous.

Re-injuries were recorded for 3 (12%) of the 25 treated hamstring injuries (all 3 were biceps femoris injuries). All the recurrences were grade 2a lesions. One re-injury was not treated as the patient refused treatment, and the other 2 were treated with a new PRP injection.

The new injuries occurred  $10 \pm 1$  days after the return to sport participation. In the untreated re-injury the SPA was 42 days, while in the treated lesion it was 15 days in one case and 26 days in the other.

## Discussion

This study presents the results referring to the largest series of PRP-treated hamstring injuries sustained by top-level professional football players. The recurrence rate was 12%, and the re-injuries involved only the biceps femoris. It is known that the incidence of re-injuries is higher after more severe lesions (17, 18). In our experience, follow-up MRI of PRP-treated lesions revealed minimal muscle scarring, which suggests that



the healed tissue could have better contracting features resulting in a lower incidence of injuries of muscle scars.

Ekstrand et al. (1) prospectively followed up 51 male professional football teams (2,299 players) for nine years prior to 2010 (the year when the WADA dropped its ban on the use of PRP in the treatment of muscle injuries in professional sport). They reported 2,908 muscle injuries and a re-injury rate of 16%. In another paper, the same Author examined 31 major league football teams during a season and reported 393 thigh injuries (19); of these, 49 (12%) were re-injuries, defined as injury of the same type and at the same site as an index injury occurring no more than two months after a player's return to full participation following the index injury.

In the present study, the mean SPA following re-injuries was comparable to that following the index injuries. This is in contrast with previous reports which showed longer absences for re-injuries than for non-re-injuries (1, 3, 5). Ekstrand et al. (1) demonstrated that re-injuries cause 30% longer absences than index injuries. Our finding may have been caused by factors other than the PRP treatment. The medical staff in question has decades of experience in treating muscle injuries and has developed specific rehabilitation protocols for re-injuries. Moreover, the high number of follow-up MRI examinations performed for each lesion (mean 1.78) allowed close monitoring of the healing process.

In the present study, the low rate of re-injuries seems to indicate the presence of good quality of healing tissue in PRP-treated injuries. This has been demonstrated in animal studies (11), but needs to be confirmed in further clinical studies. There exist few published clinical studies on muscle injuries treated with PRP. Wright-Carpenter et al. (20) used autologous conditioned serum (ACS) to treat 18 professional sportsmen with a variety of muscle strains. ACS contains essentially activated PRP, which produces a lower yield of growth factors than most PRP. The study was retrospective, non-randomized and non-blinded. As control group, the Author used 11 patients treated with Actovegin (Nycomed, Zurich, Switzerland), a deproteinized dialysate from bovine blood, and Traumeel, a homeopathic anti-inflammatory drug containing extracts of arnica, calendula and camomile. An almost one-week shorter recovery time from injury was reported in the ACS group.

Complete functional recovery was obtained in half the expected time for each type of lesion. Moreover, no scar formation or re-injuries were recorded. Bubnov et al. (21) evaluated the efficacy of ultrasound-guided PRP treatment, comparing it with traditional conservative therapy. Thirty patients with 34 lesions were enrolled and randomly assigned to the conservative therapy or the PRP treatment group. The patients in the treatment group showed faster pain relief; furthermore, after 1-2 weeks of PRP treatment, strength and range of motion recovery were significantly greater than in the conservative therapy group.

In our series, the role of PRP in accelerating muscle healing, as demonstrated or theorized by other studies (20, 21), was not confirmed. The present study showed a mean SPA of  $36.8 \pm 19$  days for PRP-treated hamstring lesions. In particular, the recovery time was  $38.5 \pm 17.3$  days for the biceps femoris,  $33.3 \pm 31.2$  days for the semimembranosus, and 11 days for the semitendinosus muscles. In the setting of professional sport it is not possible to have a large untreated group since the medical staff has to offer the players the best treatment available, or rather the one they consider to be the best for the specific patient. Also, our results are difficult to compare with data present in the literature because most previous studies did not use a grading system, or because they took healing time to correspond to the time to the end of the rehabilitation stage, without considering the time needed for reconditioning (regaining complete fitness and sport-specific skills). Since the objective of every treatment in this setting is to make the player available for match selection and not just for training, we believe that SPA is a more suitable parameter to use for defining healing time.

In the study by Ekstrand et al. on the epidemiology of muscle injuries in professional football players, injuries were found to lead to a mean absence of  $14.4 \pm 18.5$  days (1); the mean absence was  $14.3 \pm 14.9$  days for hamstring injuries. However, their study included all muscle injuries, and also considered grade 0 and 1 lesions, with no sub-classification according to severity. A recent study on hamstring muscle injuries in professional football players (22) presented data on lay-off time (time until the player was again available for match selection) in relation to severity, graded according to the Peetrons classification (14). The lay-off time was  $8 \pm 3$  days for grade 0 lesions,  $17 \pm 10$  days for grade 1 lesions,  $22 \pm 11$

days for grade 2 lesions, and  $73 \pm 60$  days for grade 3 lesions. This classification is quite different from the one we used; only grade 3 is identical to ours, therefore only the lay-off time for grade 3 lesions is comparable between the two studies. The main limitation of the present study is the absence of a control group. Other limitations are the use of a selected population (professional football players from a single top-league club), the short observation period (mean 36.6 months), and the lack of standardized targets for considering the healing process finished.

In conclusion, in professional football, treatment of acute hamstring injuries with intralesional injections of PRP is feasible, simple and safe. It reduces the incidence of re-injuries in the short term. PRP treatment helps to promote a stable muscle scar that shows no new injuries. We are not able to confirm a faster recovery of PRP-treated muscle lesions compared to untreated ones.

## References

- Ekstrand J, Häggglund M, Waldén M. Epidemiology of muscle injuries in professional football (soccer). *Am J Sports Med.* 2011;39:1226-1232.
- Häggglund M, Waldén M, Ekstrand J. Injury incidence and distribution in elite football - a prospective study of the Danish and the Swedish top divisions. *Scand J Med Sci Sports.* 2005;15:21-28.
- Ekstrand J, Häggglund M, Waldén M. Injury incidence and injury patterns in professional football: the UEFA injury study. *Br J Sports Med.* 2011;45:553-558.
- Häggglund M, Waldén M, Ekstrand J. Risk factors for lower extremity muscle injury in professional soccer: the UEFA Injury Study. *Am J Sports Med.* 2013;41:327-335.
- Waldén M, Häggglund M, Ekstrand J. Injuries in Swedish elite football - a prospective study on injury definitions, risk for injury and injury pattern during 2001. *Scand J Med Sci Sports.* 2005;15:118-125.
- Kasemkijwattana C, Menetrey J, Bosch P, et al. Use of growth factors to improve muscle healing after strain injury. *Clin Orthop Relat Res.* 2000;(370):272-285.
- Menetrey J, Kasemkijwattana C, Day CS, et al. Growth factors improve muscle healing in vivo. *J Bone Joint Surg Br.* 2000;82:131-137.
- Efthimiadou A, Asimakopoulos B, Nikolettos N, et al. Angiogenic effect of intramuscular administration of basic and acidic fibroblast growth factor on skeletal muscles and influence of exercise on muscle angiogenesis. *Br J Sports Med.* 2006;40:35-39.
- Hammond JW, Hinton RY, Curl LA, et al. Use of autologous platelet-rich plasma to treat muscle strain injuries. *Am J Sports Med.* 2009;37:1135-1142.
- Engert JC, Berglund EB, Rosenthal N. Proliferation precedes differentiation in IGF-I-stimulated myogenesis. *J Cell Biol.* 1996;135:431-440.
- Gigante A, Del Torto M, Manzotti S, et al. Platelet rich fibrin matrix effects on skeletal muscle lesions: an experimental study. *J Biol Regul Homeost Agents.* 2012;26:475-484.
- WADA. The World Anti-Doping Code. The Prohibited List 2011. World Anti-Doping Agency, Montreal, September 2010.
- Engelbrecht L, Steffen K, Alsousou J, et al. IOC consensus paper on the use of platelet-rich plasma in sports medicine. *Br J Sports Med.* 2010;44:1072-1081.
- Peetrons P. Ultrasound of muscles. *Eur Radiol.* 2002;12:35-43.
- Stoller DW. MRI in Orthopaedics and Sports Medicine. 3rd edition. Wolters Kluwer/Lippincott, Philadelphia. 2007.
- Balius R, Maestro A, Pedret C, et al. Central aponeurosis tears of the rectus femoris: practical sonographic prognosis. *Br J Sports Med.* 2009;43:818-824.
- Orchard J, Best TM, Verrall GM. Return to play following muscle strains. *Clin J Sport Med.* 2005;15:436-441.
- Malliaropoulos N, Papacostas E, Kiritsi O, et al. Posterior thigh muscle injuries in elite track and field athletes. *Am J Sports Med.* 2010;38:1813-1819.
- Ekstrand J, Askling C, Magnusson H, et al. Return to play after thigh muscle injury in elite football players: implementation and validation of the Munich muscle injury classification. *Br J Sports Med.* 2013;47:769-774.
- Wright-Carpenter T, Klein P, Schäferhoff P, et al. Treatment of muscle injuries by local administration of autologous conditioned serum: a pilot study on sportsmen with muscle strains. *Int J Sports Med.* 2004;25:588-593.
- Bubnov R, Yevseenko V, Semeniv I. Ultrasound guided injections of platelets rich plasma for muscle injury in professional athletes. Comparative study. *Med Ultrason.* 2013;15:101-105.
- Ekstrand J, Healy JC, Waldén M, et al. Hamstring muscle injuries in professional football: the correlation of MRI findings with return to play. *Br J Sports Med.* 2012;46:112-117.