

Laser-Assisted Bypass of the Internal Carotid Artery Prior to Treatment of an Extensive Angiofibroma*

Kees Graamans, M.D., Ph.D. and Cornelis A.F. Tulleken, M.D., Ph.D.

The publisher regrets an error in the publication of the authors' first two figures. The correct illustrations are given below.

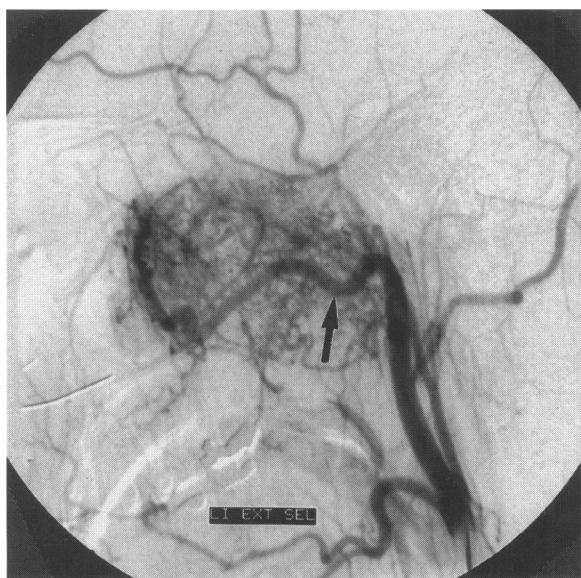


Figure 1. Conventional angiogram of the left external carotid artery. The internal maxillary artery (arrow) is an important feeder artery for the angiofibroma.

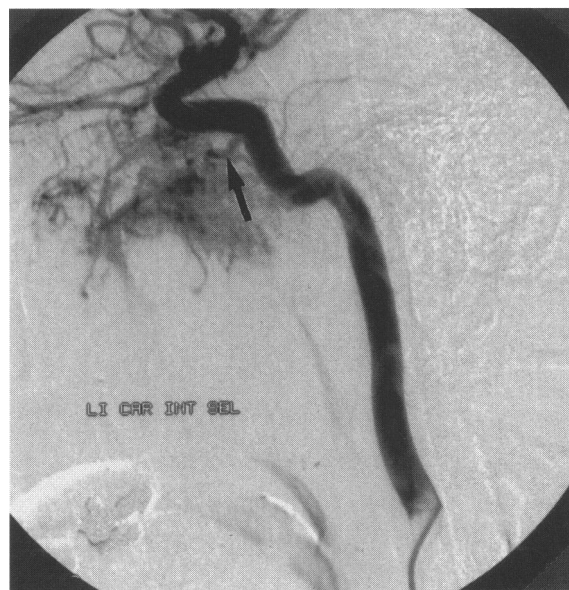

Figure 2. Left internal carotid artery angiogram. The inferolateral trunk (arrow) is dilated and contributes significantly to the blood supply of the tumor.

*Previously published in *Skull Base Surgery*, volume 8, Number 4, 1998, pp 205–210. Copyright © 1999 by Thieme Medical Publishers, Inc., 333 Seventh Avenue, New York, NY 10001, USA. Tel.: +1 (212) 760-0888 x132. All rights reserved.