

Esophageal voice prosthesis mistaken for impacted foreign body

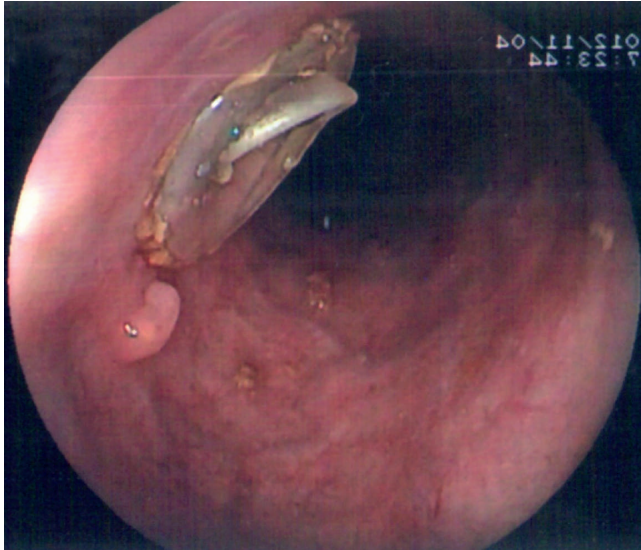


Fig. 1 Foreign-body-like appearance of the voice prosthesis during endoscopy.

A 66-year-old man presented with dysphagia and weight loss of more than 20% in a 3-month period. His past medical history included total laryngectomy and left radical neck dissection for laryngeal cancer in 1999. Later he underwent right radical neck dissection and insertion of an esophageal Blom–Singer voice prosthesis in 2000. The patient had adjuvant chemoradiotherapy. He had lost 11 kg within the last 3-month period. Upper gastrointestinal endoscopy revealed a tumoral mass obstructing the esophageal lumen at 28 cm distal to the incisors. Meanwhile, the endoscopist also noticed a foreign-body-like object 14 cm from the incisors (● **Fig. 1**) and nearby a small papillomatous lesion. The material of the object was completely unknown to us and a brief consultation with a laryngologist prevented us from taking it out with a snare. The object was a voice prosthesis. There has been an increasing tendency for voice rehabilitation after total laryngectomy. Techniques used are the esophageal voice, electronic devices, and the voice prosthesis. In the last, the voice prosthesis, acting as a one-way valve, enables pulmonary airflow from the trachea to enter the esophagus, while preventing

backflow of esophageal contents into the trachea [1]. Provox is one such prosthesis and is made of silicone. This prosthesis has been in use since the 1980s. Tracheoesophageal prosthetic voice replacement has become widely accepted internationally [2].

It is essential for endoscopists to be familiar with this prosthetic device so that they do not remove it by mistake. Consultation with a laryngologist should be helpful in the appraisal of any material in an image encountered during endoscopic evaluation of laryngectomized patients.

Endoscopy_UCTN_Code_CCL_1AB_2AC_3AH

K. Karakaya¹, A. U. Emre¹, O. Tascilar¹, H. B. Ucan¹, O. Irkörüçü¹, E. Tas², G. K. Cakmak¹, Y. Ustundag³, M. Comert¹

¹ Department of General Surgery, Zonguldak Karaelmas University, Zonguldak, Turkey

² Department of Otorhinolaryngology, Zonguldak Karaelmas University, Zonguldak, Turkey

³ Department of Gastroenterology, Zonguldak Karaelmas University, Zonguldak, Turkey

References

- 1 Singer MI, Blom ED. An endoscopic technique for voice restoration after total laryngectomy. *Ann Otol Rhinol Laryngol* 1980; 89: 529–533
- 2 Oh CK, Meleca RJ, Simpson ML, Dworkin JP. Fiberoptic examination of the pharyngoesophageal segment in tracheoesophageal speakers. *Arch Otolaryngol Head Neck Surg* 2002; 128: 692–697

Bibliography

DOI 10.1055/s-2007-995714

Endoscopy 2009; 41: E183

© Georg Thieme Verlag KG Stuttgart · New York · ISSN 0013-726X

Corresponding author

K. Karakaya, MD

Zonguldak Karaelmas Universitesi

Tıp Fakültesi

Genel Cerrahi AD

67600 Kozlu

Zonguldak

Turkey

Fax: +90-372-2610155

kkarakaya@hotmail.com