

A novel technique for endoscopic reanastomosis in a patient with a completely strictured colorectal anastomosis

Stricture, depending on its definition, is a complication in 0%–30% of colorectal anastomoses [1]. This article describes a novel technique for endoscopic reanastomosis in a completely strictured colorectal anastomosis with no visible lumen either at endoscopy or at radiography; to my knowledge this is the first publication of an entirely endoscopic technique. In a 72-year-old man with carcinoma in the distal sigmoid, a stapled side-to-end colorectal anastomosis was performed and defunctioned with a loop ileostomy. Histopathology showed a moderately dif-

ferentiated adenocarcinoma T3 N1 M0, which was considered microscopically radical.

An anastomotic dehiscence was detected at endoscopy 2 weeks postoperatively. Endoscopic lavage was initiated as an inpatient procedure for 2 weeks, then continued as an outpatient procedure for the following 3 months, thereafter pelvic computed tomography (CT) showed no abscess and the dehiscence was healed at endoscopy. At follow-up 6 months later, transanal water-soluble enema and water-soluble contrast through the effer-

ent limb of the diverting loop ileostomy revealed no lumen at all in the anastomosis (● Fig. 1). Endoscopy showed a completely intact mucosa and no lumen whatsoever to the proximal bowel (● Fig. 2). Following intravenous analgesia (alfentanil) and sedation (midazolam), a gastroscope (Olympus GIF XTQ 160, Olympus Optical Co. Ltd., Tokyo, Japan) was used for transrectal puncture of the descending colon during fluoroscopic guidance with an Echotip-19® Ultra Endoscopic Ultrasound Needle (Cook Ireland Ltd, Limerick, Ireland) extended for 20 mm (● Fig. 3). Water-soluble contrast was injected, thereby verifying the position of the needle in the descending colon (● Fig. 4). A 450 cm long 0.035-inch guide wire (Jagwire, Boston Scientific Nordic AB, Helsingborg, Sweden) was inserted through the needle to reach the transverse colon (● Fig. 5). A CRE™ Wire-guided Balloon Dilator (Boston Scientific

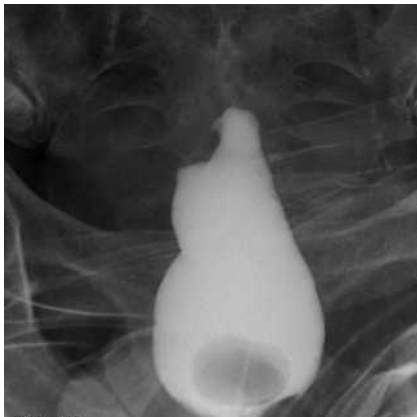

Fig. 1 Radiograph showing no lumen at all in the anastomosis on transanal water-soluble enema.

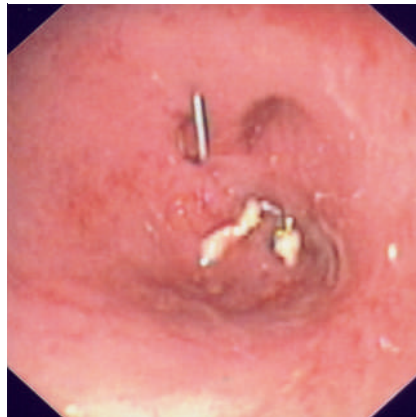


Fig. 2 Endoscopic view showing some staples in the anastomotic area, a completely intact mucosa and no lumen whatsoever to the proximal bowel.

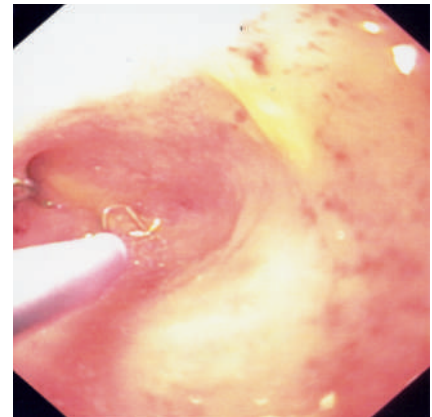


Fig. 3 Endoscopic view showing transrectal puncture of the descending colon using an Echotip-19® Ultra Endoscopic Ultrasound Needle.

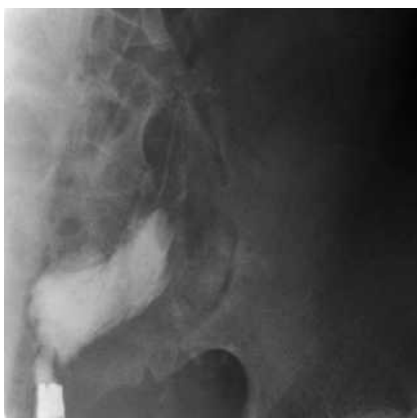

Fig. 4 Radiograph showing the gastroscope, transrectal puncture of the descending colon, and injection of water-soluble contrast verifying the position of the needle in the descending colon.

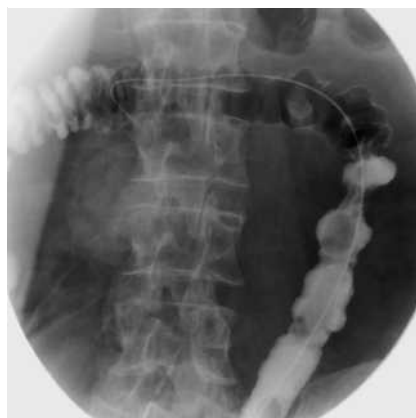

Fig. 5 Radiograph showing the 450 cm long guide wire reaching the transverse colon. The colon is outlined with water-soluble contrast injected through transrectal puncture of the descending colon.

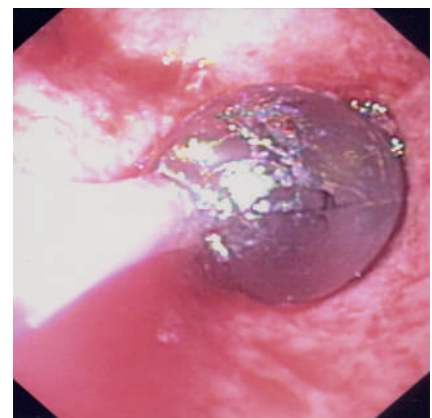


Fig. 6 Endoscopic view showing the Wire-guided Balloon Dilator in place.

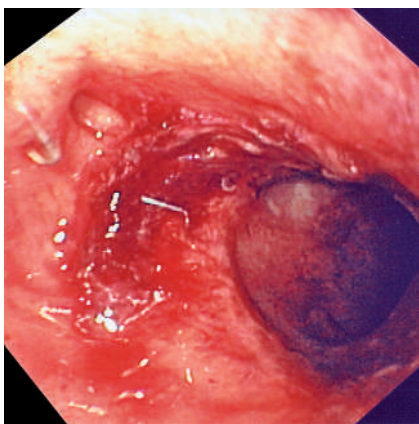


Fig. 7 Endoscopic view showing the newly created colorectal anastomosis.

Nordic AB, Helsingborg, Sweden) was used to dilate the puncture hole to 15 mm (3 atm), a procedure lasting 10 minutes (● Fig. 6), thus establishing an entirely endoscopically created colorectal anastomosis (● Fig. 7). The GIF XTQ 160 could then pass through the newly created anastomosis without difficulty. The anastomosis was dilated again using a CRE™ Wireguided Balloon Dilator at 6, 9, and 20 weeks. Both ileostomy closure and follow-up 12 months later were uneventful.

Previous publications describe either different endoscopic techniques for cases where some lumen exists [2–6] or, in a case with no lumen, a combined endo-

scopic–transanal technique [7]. The difficulty with my technique is that the position of the needle tip, in the colon proximal to the strictured anastomosis, must be confirmed by fluoroscopy with absolute certainty before insertion of the guide wire and balloon dilation. The time to loop closure was due to logistic factors not related to the procedure. An earlier closure had avoided dilations at 9 and 20 weeks.

The technique is a minimally invasive, outpatient procedure, feasible for an experienced endoscopist, with limited procedure-related risk because the position of the needle is carefully checked by fluoroscopy before the guide wire is introduced. The whole procedure is performed over the guide wire, thus minimizing the risk of perforation. A redo anastomosis implies major surgery, an inpatient procedure, general anesthesia, laparotomy to remove the anastomosis and refashion a new anastomosis, and altogether much greater risk.

Endoscopy_UCTN_Code_TTT_1AQ_2AF

G. Dafnis

Colorectal Unit, Department of Surgery and Urology, Eskilstuna County Hospital, Eskilstuna, Sweden

References

- 1 Bannura GC, Cumsille MA, Barrera AE et al. Predictive factors of stenosis after stapled colorectal anastomosis: prospective analysis of 179 consecutive patients. *World J Surg* 2004; 28: 921–925
- 2 Luck A, Chapuis P, Sinclair G et al. Endoscopic laser stricturotomy and balloon dilatation for benign colorectal strictures. *ANZ J Surg* 2001; 71: 594–597
- 3 Suchan KL, Muldner A, Manegold BC. Endoscopic treatment of postoperative colorectal anastomotic strictures. *Surg Endosc* 2003; 17: 1110–1113
- 4 Piccinni G, Nacchiero M. Management of narrower anastomotic colonic strictures. Case report and proposal technique. *Surg Endosc* 2001; 15: 1227
- 5 Forshaw MJ, Maphosa G, Sankararajah D et al. Endoscopic alternatives in managing anastomotic strictures of the colon and rectum. *Tech Coloproctol* 2006; 10: 21–27
- 6 Anvari M. Endoscopic transanal rectal stricturoplasty. *Surg Laparosc Endosc* 1998; 8: 193–196
- 7 Reissman P, Noguerras JJ, Wexner SD. Management of obliterating stricture after coloanal anastomosis. *Surg Endosc* 1997; 11: 385–386

Bibliography

DOI 10.1055/s-2007-995541

Endoscopy 2008; 40: E79–E80

© Georg Thieme Verlag KG Stuttgart · New York · ISSN 0013-726X

Corresponding author

G. Dafnis MD, PhD

Colorectal Unit
Department of Surgery and Urology
Eskilstuna County Hospital
SE-631 88 Eskilstuna
Sweden
Fax: +46-150-51509
george.dafnis@telia.com