

Extravasation of sclerosant after injection of N-butyl-2-cyanoacrylate for a bleeding gastric Dieulafoy lesion

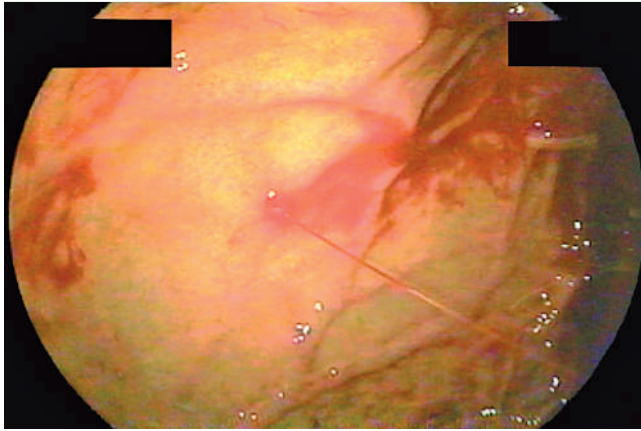


Fig. 1 An actively spurting Dieulafoy lesion in the gastric fundus.

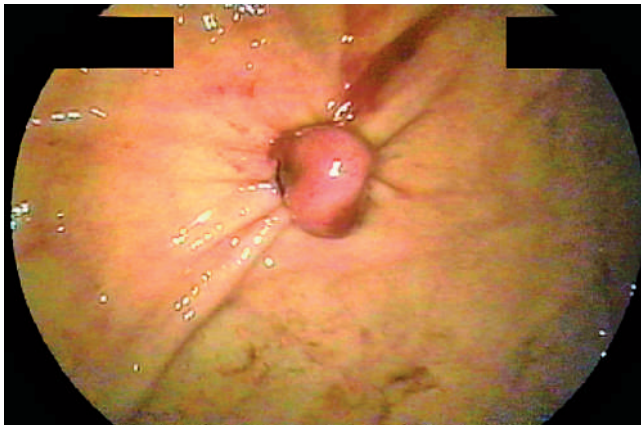

Fig. 2 The bleeding was controlled immediately after endoscopic band ligation.

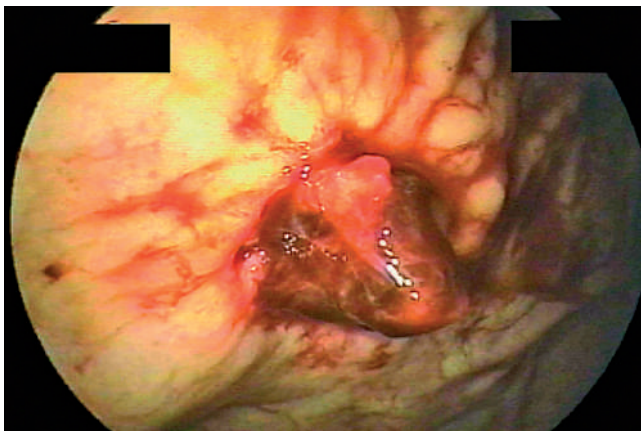


Fig. 3 Repeat endoscopy revealed active oozing from the base of the ligated area.

A 79-year-old woman was admitted because she had been passing tarry stools for 2 days. Emergency endoscopy revealed an actively spurting Dieulafoy lesion in the gastric fundus (▶ Fig. 1). Because of the technical difficulty of applying hemoclips in this case we performed rubber-band ligation, which resulted in immediate hemostasis (▶ Fig. 2). Twelve hours later, fresh blood reappeared in the nasogastric aspirate. A repeat endoscopy showed active oozing from the base of the ligated area (▶ Fig. 3). Despite the injection of 12 mL of diluted epinephrine, the bleeding persisted. After discussing the situation with the patient she agreed to receive a sclerosant injection, and the bleeding stopped after an injection of a mixture of 0.5 mL of N-butyl-2-cyanoacrylate and lipiodol. The patient complained of dull epigastric pain after the injection, and a chest radiograph showed radiopaque material along the left diaphragm (▶ Fig. 4). Abdominal computed tomography confirmed that there was extravasation of sclerosant along the left subphrenic area (▶ Fig. 5). The patient was free of any signs of infection and was discharged on day 6 of her hospital day. She remained well over the following 2 years.

Endoscopic therapy is now a mainstay of treatment for Dieulafoy lesions. Several authors have documented hemostasis rates for endoscopic band ligation of 80%–100% in case series of patients with Dieulafoy lesions [1,2]. However, the optimal rescue therapy after failed endoscopic band ligation is not known. In the present case, injection therapy with diluted epinephrine failed to control the bleeding. Hemoclipping or coagulation therapy would have been technically difficult. It was believed that repeated band ligation would increase the risk of gastric perforation [3], and so Histoacryl injection was chosen as the last resort before surgery [4]. Despite the successful hemostasis, the complication of injection-site leakage and resultant transient abdominal pain are concerning. This might have been caused by direct penetration of the gastric wall by the injection needle. The short-term outcome of sclerosant extravasation in this case and in another reported case [5] was good, but it is still not clear what the long-term effects of this complication are.

Endoscopy_UCTN_Code_CPL_1AH_2AC

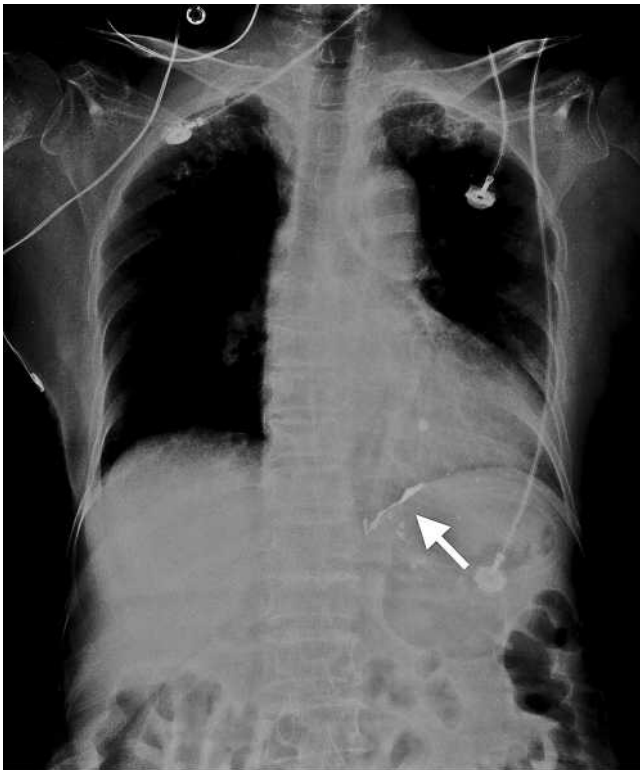


Fig. 4 The chest radiograph showed radiopaque material along the left diaphragm (arrow).

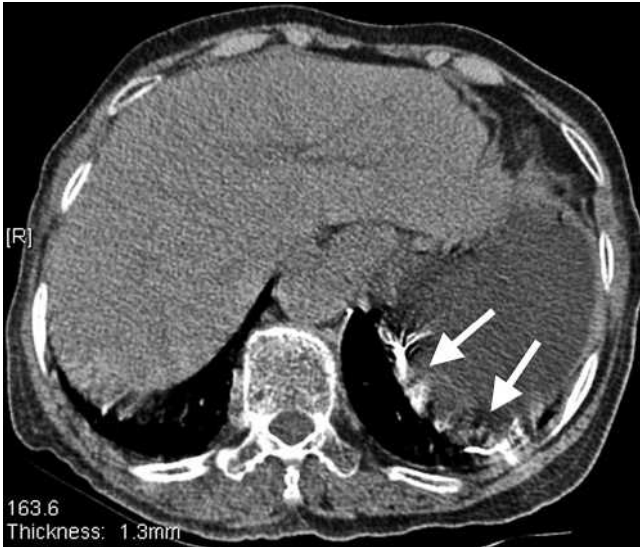

Fig. 5 Abdominal computed tomography showed extravasation of sclerosant along the left subphrenic area (arrows).

M.-S. Soon, Y.-Y. Chen, H.-H. Yen
 Department of Gastroenterology,
 Changhua Christian Medical Center,
 Changhua, Taiwan, ROC

References

- 1 Nikolaidis N, Zezos P, Giouleme O *et al*. Endoscopic band ligation of Dieulafoy-like lesions in the upper gastrointestinal tract. *Endoscopy* 2001; 33: 754–760
- 2 Park CH, Joo YE, Kim HS *et al*. A prospective, randomized trial of endoscopic band ligation versus endoscopic hemoclip placement for bleeding gastric Dieulafoy's lesions. *Endoscopy* 2004; 36: 677–681
- 3 Chen WC, Hou MC, Tsay SH *et al*. Gastric perforation after endoscopic ligation for gastric varices. *Gastrointest Endosc* 2001; 54: 99–101
- 4 Yok KY, Kum CK, Goh PM. Endoscopic hemostasis of upper gastrointestinal bleeding with Histoacryl: last resort before surgery. *Endoscopy* 1996; 28: 256–258
- 5 Cheng HC, Cheng PN, Tsai YM *et al*. Sclerosant extravasation as a complication of sclerosing endotherapy for bleeding gastric varices. *Endoscopy* 2004; 36: 239–241

Bibliography

DOI 10.1055/s-2007-966882
Endoscopy 2008; 40: E51–E52
 © Georg Thieme Verlag KG Stuttgart · New York ·
 ISSN 0013-726X

Corresponding author

H.-H. Yen, MD
 Changhua Christian Medical Center
 135 Nanhsiao Street
 Changhua 500
 Taiwan
 Fax: +886-4-7228289
 91646@cch.org.tw