

Transjugular intrahepatic portosystemic shunt and endoscopic submucosal dissection for treatment of early gastric cancer in a cirrhotic patient

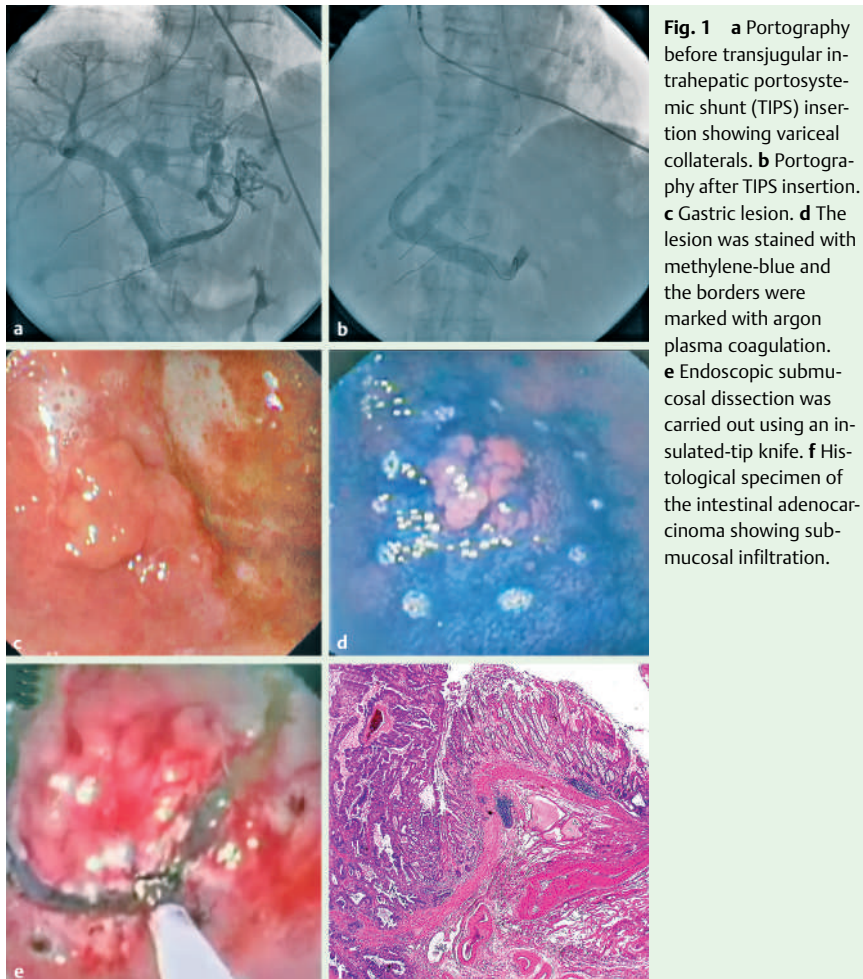


Fig. 1 **a** Portography before transjugular intrahepatic portosystemic shunt (TIPS) insertion showing variceal collaterals. **b** Portography after TIPS insertion. **c** Gastric lesion. **d** The lesion was stained with methylene-blue and the borders were marked with argon plasma coagulation. **e** Endoscopic submucosal dissection was carried out using an insulated-tip knife. **f** Histological specimen of the intestinal adenocarcinoma showing submucosal infiltration.

Video 1

X-ray-guided transjugular intrahepatic portosystemic shunt implantation followed by endoscopic submucosal dissection of the gastric cancer.

Portal hypertension is a main source of morbidity and mortality in cirrhotic patients undergoing gastric surgery. Therefore, these patients are often rejected for gastric surgery, and portal decompression is essential prior to further invasive treatment [1–2].

A 63-year-old patient was admitted to our institution with acute variceal bleeding due to Child-B cirrhosis. Variceal bleeding was controlled by endoscopic band ligation. During endoscopy an intestinal adenocarcinoma (cT1N0M0) was incidentally detected. The patient was rejected for gastrectomy due to severe portal hypertension and subsequent high peri-operative risk. Because of its minimal invasiveness, transjugular intrahepatic portosystemic shunt (TIPS) combined with endoscopic submucosal dissection (ESD) seemed an appropriate treatment option (● Fig. 1a–e, ● Video 1). Histologically, R0 resection was achieved but submucosal infiltration was visible (● Fig. 1f). Biopsies 6 months after ESD showed no residual cancer. At follow-up 1 year later, the gastric cancer had reoccurred and was already metastatic. No hydropic decompensation, variceal bleeding, or episode of hepatic encephalopathy had occurred in the meantime.

TIPS combined with ESD seemed safe and effective in this patient not eligible for gastric surgery [1–5]. The treatment decision was based on the favorable results of ESD in early gastric cancer [3–5]. TIPS implantation was performed to minimize the bleeding risk at ESD. Despite R0 resection the gastric cancer reoccurred 1 year later. Thus, gastrectomy and radical lymph node dissection might have brought additional benefit [2]. For curative endoscopic therapy, a maximum submucosal infiltration of 500 µm is recommended. Infiltration depth evaluated by endoscopic ultrasound (EUS) has unfortunately not shown a consistent high level of accuracy [5]. Application of 30-MHz EUS probes, optical coherence tomography or confocal laser microscopy might be able to overcome these limitations [5]. Because of the rare coincidence of gastric cancer and Child-B cirrhosis, no established treatment guidelines exist, and specific treatment has to consider the perioperative risk on an individual patient basis.

Endoscopy_UCTN_Code_TTT_1AO_2AG

D. von Renteln¹, B. Riecken¹,
H. Muehleisen², K. Caca¹

¹ Medizinische Klinik I, Klinikum Ludwigs-
burg, Ludwigsburg, Germany

² Pathologisches Institut, Klinikum Lud-
wigsburg, Ludwigsburg, Germany

References

- 1 *Mansour A, Watson W, Shayani V et al.* Abdominal operations in patients with cirrhosis: still a major surgical challenge. *Surgery* 1997; 122: 730–736
- 2 *Lee JH, Kim J, Cheong JH et al.* Gastric cancer surgery in cirrhotic patients: result of gastrectomy with D2 lymph node dissection. *World J Gastroenterol* 2005; 11: 4623–4627
- 3 *Onozato Y, Ishihara H, Iizuka H et al.* Endoscopic submucosal dissection for early gastric cancers and large flat adenomas. *Endoscopy* 2006; 38: 980–986
- 4 *Neuhaus H, Costamagna G, Deviere J et al.* Endoscopic submucosal dissection (ESD) of early neoplastic gastric lesions using a new double-channel endoscope (the 'R-scope'). *Endoscopy* 2006; 38: 1016–1023
- 5 *Vieth M, Rosch T.* Endoscopic mucosal resection and the risk of lymph-node metastases: indications revisited? *Endoscopy* 2006; 38: 175–179

Bibliography

DOI 10.1055/s-2007-966800
Endoscopy 2008; 40: E32–E33

© Georg Thieme Verlag KG Stuttgart · New York ·
ISSN 0013-726X

Corresponding author

K. Caca, MD

Medizinische Klinik I
Klinikum Ludwigsburg

Ludwigsburg

Germany

Fax: +49-7141-997463

karel.caca@kliniken-lb.de