

Gastrointestinal Bleeding from the Papilla of Vater

Among the rare causes of gastrointestinal bleeding is hemorrhage from the papilla of Vater (1–4). We describe here the case of a 46-year-old man who had suffered an attack of biliary pancreatitis (treated with endoscopic papillotomy and cholecystectomy) four years previously, which finally led to the formation of a pancreatic pseudocyst of about 6×6 cm. He was well until three months before presentation, when he developed several episodes of melena with a hemoglobin drop to a minimum of 4.7 g/dl. After the visualization of blood in the duodenum on upper gastrointestinal endoscopy (leading to the suspicion of hemorrhage from the papilla) at another institution, he was transferred to us with a hemoglobin level of 9.7 g/dl following transfusion of 7 units of blood. CT and angiography confirmed an aneurysmal broadening of the splenic artery as a source of hemorrhage into the adjacent pseudocyst (Figure 1). The patient was treated with a metal spiral implanted under fluoroscopic control, obstructing the splenic artery proximal to the aneurysm (Figure 2). The bleeding stopped, but several small splenic infarctions developed. The patient was discharged free of symptoms on the eighth day. He is still well after a further eleven months, without any bleeding episodes. This case confirms previous reports in the literature which also involved aneurysms of parapancreatic vessels and pancreatic pseudocysts (1–4). Bleeding from the papilla should be considered in cases in which a bleeding source cannot be identified on endoscopy in patients with upper gastrointestinal bleeding, and should prompt radiological procedures.

P. Born¹, W. Bautz², B. Zimmerhackl¹, U. Schweigart¹, M. Classen¹

¹Department of Internal Medicine II and ²Department of Radiology, Technical University of Munich, Germany

References

1. Martin WR, Kohler B, Riemann JF: Diagnostik seltener Blutungsursachen am oberen Gastrointestinaltrakt. Dtsch. med. Wschr. 1991; 166: 522–527.
2. De Mas, R, Kohler B, Ante D, Schönleben K, Riemann JF: Hämorrhagischer Hämoperitonismus nach Ruptur eines A. hepatica-Aneurysmas. Z. Gastroenterol. 1989; 27: 735–738.
3. Ribbans WJ, Pounder RE, Lindsay I: Haemorrhage through the ampulla of Vater. Postgrad. Med. J. 1985; 61: 533–535.
4. Bowers J, Koehler PR, Hammar SP, Nelson JA, Tolman KG: Rupture of a Splenic Artery Aneurysm into the Pancreatic Duct. Gastroenterology 1976; 70: 1152–1155

Corresponding Author

P. Born, M.D.
 Department of Internal Medicine II
 Klinikum rechts der Isar
 Technical University of Munich
 Ismaninger Str. 22
 81675 München
 Germany

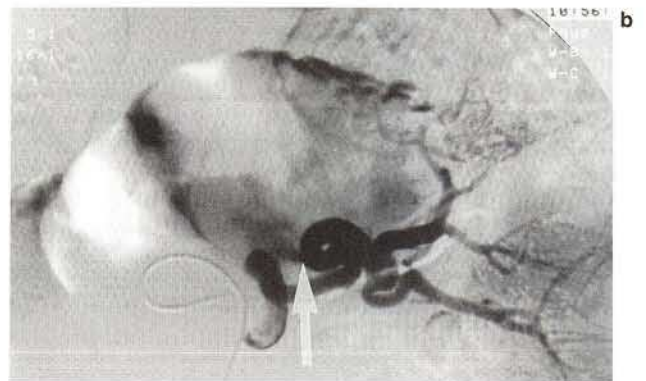
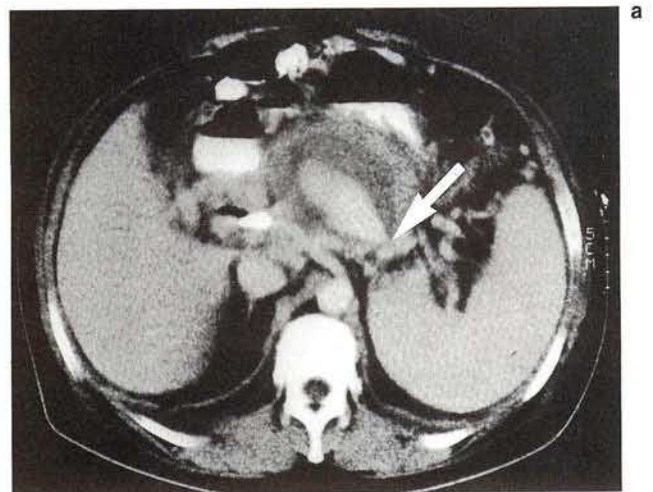


Figure 1: Spiral CT with intravenous contrast shows hemorrhage from the splenic artery into a pancreatic pseudocyst (a), which was confirmed by angiography (b). Arrow: blood leakage from the vessel.

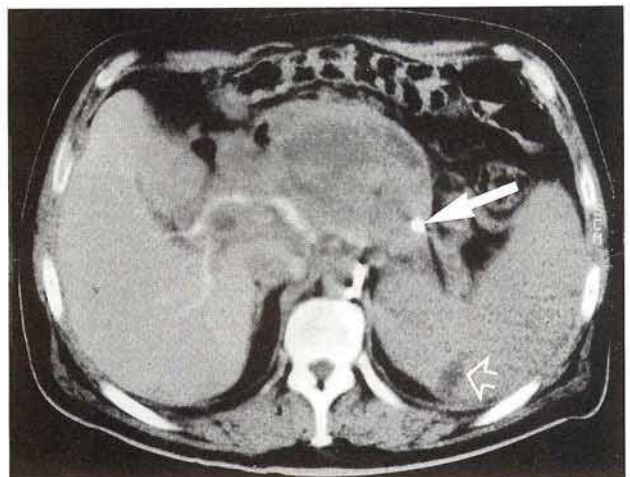


Figure 2: CT following splenic artery embolization with a spiral (closed arrow), leading to cessation of bleeding. The open arrow indicates splenic infarction.