

A Case of Colonic Actinomycosis Difficult to Distinguish from Advanced Colonic Carcinoma

We report here the case of a 58-year-old man who presented with right hypochondralgia, fever, and anorexia. The barium enema examination revealed a narrowing of the intestine near the hepatic flexure of the ascending colon. At colonoscopy, an elevated-type lesion was observed in the ascending colon. It extended to about one-third of the intestinal lumen in circumference, with low elevation, and the border was not clear. It showed a red irregular surface without erosion. A small, irregular-shaped ulcer was noted in the center of the lesion (Figure 1).

The patient underwent surgery for resection of the lesion. The formalin-fixed specimen showed an abscess. Histologically, fibrous granulation accompanied by increased forming cells was observed from the bottom of the ulcer to the fatty tissue of the serosa. There was a microabscess in the granulation and, since colonies giving positive tests on periodic acid-schiff (PAS) staining were detected in it, a diagnosis of actinomycosis was made (Figure 2).

Actinomycetes are Gram-positive, normal endogenous anaerobic oral flora, and *Actinomyces israelii* is known to be infectious to humans. Colonic actinomycosis is induced by abdominal surgery, tumor, injury, and perforation of a viscus. Actinomycetes acquire pathogenicity through invasion from tears in the intestinal mucosa, and generate inflammatory granulation (1,2). Narrowing of the intestine is caused by the pressure of the lesion. Thus the findings in the barium enema and colonoscopy are similar to those of neoplastic lesions (3-5). In order to establish the diagnosis, it is necessary either to detect colonies called sulfur granules histologically in the abscess, or to demonstrate the existence of actinomycetes in the culture bacteriologically.

With regard to chronic inflammatory granulomatous diseases showing similar morphological findings to those of advanced colonic carcinoma, the possibility of actinomycosis should be taken into account when making a differential diagnosis, although the incidence of this is not high. In particular, in the case of an abscess-like lesion with strong inflammatory findings, it is important to look for colonies characteristic of actinomycosis.

References

1. Putman HC Jr, Dockerty MB, Waugh JM: Abdominal actinomycosis. *Surgery* 1950; 28: 781-800.
2. Gingold BS, Fazio VW: Abdominal actinomycosis: a complication of colonic perforation. *Dis Colon Rectum* 1978; 21: 374-376.
3. Cowgill R, Quan SHQ: Colonic actinomycosis mimicking carcinoma. *Dis Colon Rectum* 1978; 21: 45-46.
4. Thompson JR, Watts R, Thompson WC: Actinomycetoma masquerading as an abdominal neoplasm. *Dis Colon Rectum* 1982; 25: 368-370.

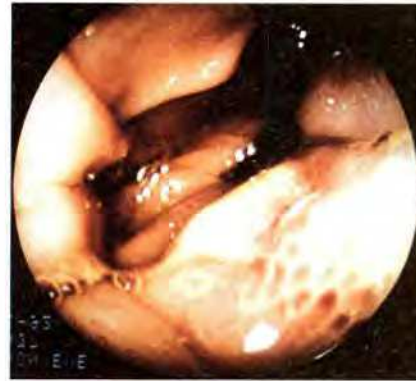

Figure 1: Colonoscopy showed an elevated-type red lesion accompanying a small ulcer in the center.

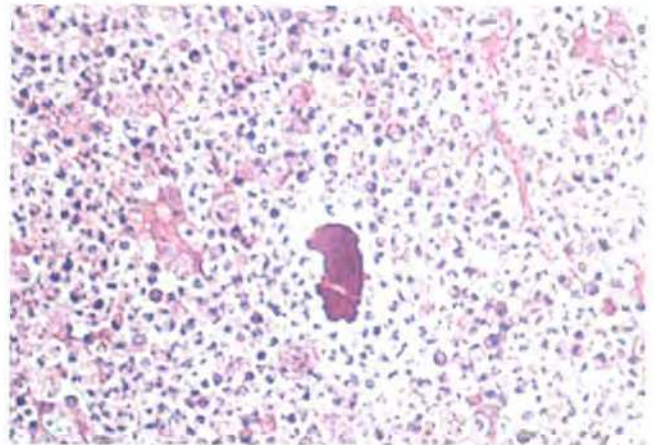


Figure 2: Bacterial colonies were detected in a microabscess in the granulation (staining: PAS).

5. Sechas M, Christeas N, Balaroutsos C: Actinomycosis of the colon: report of two cases. *Dis Colon Rectum* 1972; 15: 366-369.

S. Higaki, S. Matsuura, N. Awaya, N. Mitani, M. Tada, K. Okita
First Department of Internal Medicine, Yamaguchi University
School of Medicine, Yamaguchi, Japan

Corresponding Author

S. Higaki, M.D.
First Department of Internal Medicine
Yamaguchi University School of Medicine
1144 Kogushi
Ube
Yamaguchi 755
Japan
Fax: +81-836-222240