

A New Endoscopic Resection Technique for Early Gastric Cancer, Using an Endoscopic Ligating Device Designed to Treat Esophageal Varices: Preliminary Report of Four Cases

Endoscopic resection of some gastric lesions located in the lesser curvature, posterior wall, cardia, or fundus is still challenging even for experienced endoscopists, because the position of the lesions makes it difficult to manipulate cutting devices with face-on views (1). To overcome these drawbacks in conventional methods, we have developed a new technique for endoscopic resection of early gastric cancer using an endoscopic ligating device that has recently been employed for treatment of esophageal varices (2).

Four patients underwent endoscopic removal of early gastric cancer. The gastric lesion was observed, and a hypertonic saline-epinephrine solution was injected into the submucosa (3). The lesion was then elevated together with the surrounding mucosa. After sliding the overtube into the esophagus, the endoscope was withdrawn, and a forward-viewing endoscope with an endoscopic ligating device was inserted through the overtube (Figure 1). Suction was applied, forcing protrusion of the mucosal lesion into the housing at the tip of the ligating device. A rubber band was then placed around the base of the lifted tissue, creating a pedunculated polyp containing the lesion plus a margin of normal mucosa several millimeters thick (Figure 2). The lesion was then easily excised using snare cautery, with a face-on view. In three of the patients, complete resections were confirmed histologically with 1 mm at least of tumor-free margin. In the remaining patient, complete resection could not be achieved, since a former biopsy had caused scar formation at the site, resulting in failure to inject the hypertonic saline-epinephrine solution and leaving a residual tumor. This patient subsequently underwent gastrectomy.

The technique is simple and quick, taking only 40 minutes on average to complete the resection, and not involving any specific skill in handling the endoscope. It is not always necessary to approach the lesion with the endoscope from the best position, because the lesion can be captured from any direction with the suction force. Although this method requires exchange of the endoscope, placement of the overtube in the upper esophagus reduces the pain for the patient and saves time. An area of mucosa up to 10 mm in diameter can be resected, and additional resections are possible. Only a uniform depth of the mucosal and submucosa layers is removed, without involving the muscular layer (4).

T. Yokoyama¹, K. Usui¹, M. Tsujimoto¹, H. Kitamura², S. Kawasaki², M. Makuuchi²

¹ Department of Surgery, Komoro-Kousei Hospital, Komoro, Japan

² First Department of Surgery, Shinshu University School of Medicine, Matsumoto, Japan

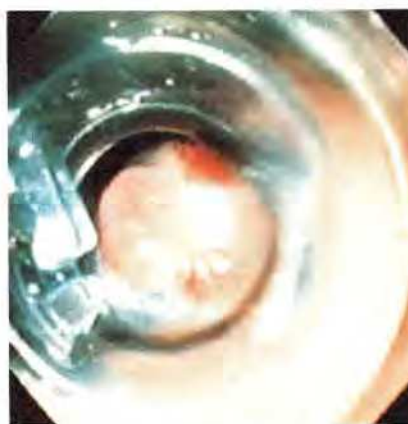


Figure 1: Inner view of the ligating device attached to the forward-viewing endoscope.

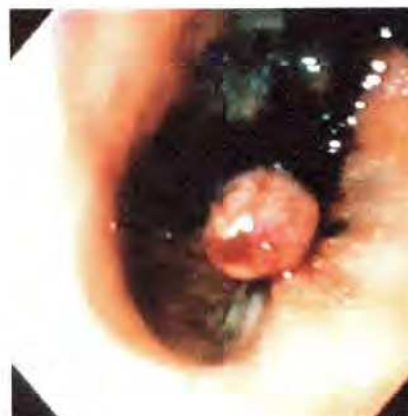

Figure 2: Pedunculated polyp created by application of a rubber band around the base of the lifted tissue.

References

1. Tada M, Murata M, Murakami F et al.: Development of the strip-off biopsy [in Japanese]. *Gastroenterol Endosc* 1984; 26: 833–839.
2. Stiegmann GV, Sun JH, Hammond WS: Results of experimental endoscopic esophageal varix ligation. *Am J Surg* 1988; 54: 105–108.
3. Hirao M, Masuda K, Asanuma T et al.: Endoscopic resection of early gastric cancer and other tumors with local injection of hypertonic saline-epinephrine. *Gastrointest Endosc* 1988; 34: 264–269.
4. Chaves DM, Sakai P, Mester M, et al.: A new endoscopic technique for the resection of flat polypoid lesions. *Gastrointest Endosc* 1994; 40: 224–226.

Corresponding Author

T. Yokoyama, M.D.
First Department of Surgery
Shinshu University School of Medicine
3-1-1 Asahi
Matsumoto
Nagano 390
Japan