

## Dysplastic Change in the Solitary Juvenile Polyp

We describe a case of solitary juvenile polyp showing dysplasia – further evidence that these lesions have malignant potential.

A 53-year-old woman with a six-month history of rectal bleeding, underwent colonoscopy. She had been previously well, with no family history of colonic polyps, carcinoma, or rectal bleeding. A polyp with a diameter of 1 cm in the lower sigmoid (Figure 1) was removed by snare diathermy. The rest of the colon was normal. Histology showed glands of varying size within abundant, oedematous, inflamed fibrovascular stroma. The glands towards the center of the polyp were cystically dilated, and contained pus cells (Figure 2). Although the overall configuration was typical of a juvenile polyp, the epithelial lining of the glands showed moderate dysplasia (Figure 3).

Although the malignant potential of multiple juvenile polyps is well established, solitary juvenile polyps have been held traditionally to have no malignant potential. However, Giardiello et al. (1) reviewed the literature and identified two cases of carcinoma arising within solitary polyps and three cases containing adenomatous epithelium, to which they added a fourth. There have also been reports of solitary juvenile polyps synchronous with adenomas or carcinomas. Although a follow-up study of 82 patients after resection of solitary juvenile polyps showed no increased risk of colorectal cancer (2), we report this case as a reminder that solitary juvenile polyps may undergo dysplastic change, and can present at any age. Furthermore, we could find no published endoscopic photographs of these polyps, which have a distinctive smooth and shiny appearance.

W. Dickey<sup>1</sup>, J. Alderdice<sup>2</sup>, B. McConnell<sup>1</sup>

<sup>1</sup> Dept. of Gastroenterology, Antrim Hospital, Antrim, Northern Ireland, United Kingdom

<sup>2</sup> Dept. of Histopathology, Antrim Hospital, Antrim, Northern Ireland, United Kingdom

## References

1. Giardiello FM, Hamilton SR, Kern SE, et al. Colorectal neoplasia in juvenile polyposis or juvenile polyps. *Arch Dis Child* 1991; 66: 971–5.
2. Nugent KP, Talbot IC, Hodgson SV, Phillips RKS. Solitary juvenile polyps: not a marker for subsequent malignancy. *Gastroenterology* 1993; 105: 698–700.

## Corresponding Author

W. Dickey, M. D.  
Dept. of Medicine  
Queen's University of Belfast  
Grosvenor Road  
Belfast BT126 BJ  
United Kingdom  
Fax: +44-1504-611218

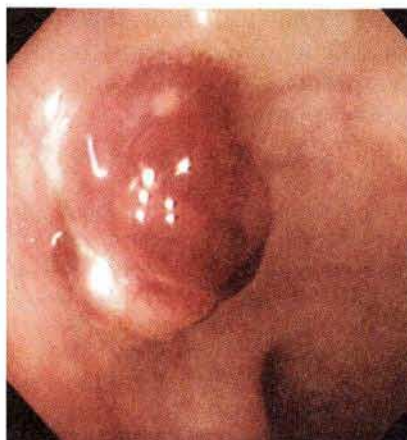

Figure 1: Solitary juvenile polyp in the lower sigmoid colon.

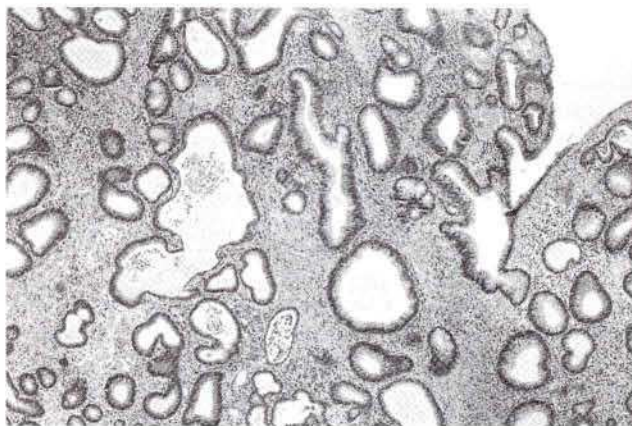


Figure 2: Irregularly dilated glands containing pus cells.

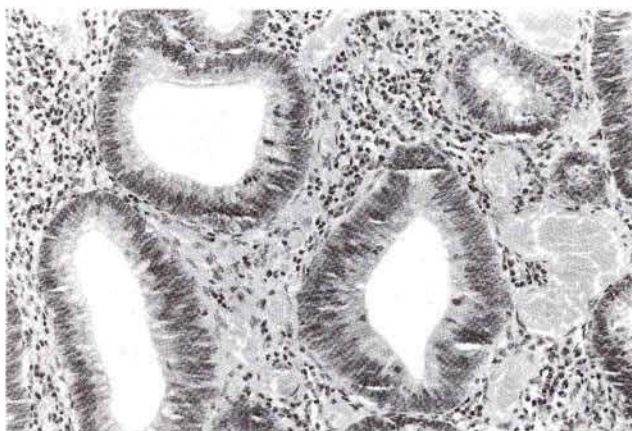

Figure 3: Moderately dysplastic glands within the polyp.