

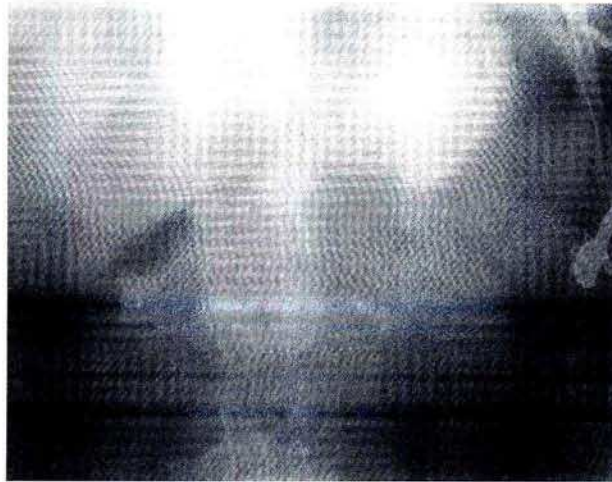
Gastric Stenosis After Potassium Chloride Ingestion

J. W. P. M. Peeters,
S. D. J. van der Werf

Dept. of Internal Medicine
and Gastroenterology,
Westeinde Hospital,
Haaglanden Medical Centre,
The Hague, The Netherlands

Corresponding Author

S. D. J. van der Werf, M.D., Ph.D.
Dept. of Internal Medicine
and Gastroenterology
Westeinde Hospital
2501 CK The Hague
The Netherlands
Fax: +70 (380) 7160
E-mail: Sdjv.d.Werf@d.d.s.nl



Epigastric pain and vomiting persisted in a 62-year-old depressive woman following an attempted suicide with a massive overdose of about 300 (2.4 mol) potassium chloride SR tablets. On admission, a supine abdominal radiograph revealed gastric distension caused by the presence of numerous tablets. During gastroscopy, a sticky, irretrievable mass was identified in a severely inflamed stomach



The duodenum was easily accessible. One month later, the necrotic mucosal lining had sloughed off, but a tight antral stenosis did not allow the passage of a pediatric gastro-scope (as shown by barium meal), necessitating partial gastric resection