

Treatment of a Submucosal Hemangioma of the Esophagus Using Simultaneous Video-Assisted Thoracoscopy and Esophagoscopy: Description of a New Minimally Invasive Technique

Hemangiomas of the esophagus are rare, representing only 3% of benign esophageal tumors (1,2). Previously, the resection of benign tumors of the esophagus was only possible via open thoracotomy. Recently, however, less invasive methods such as endoscopic resection have been introduced (3–5). We report here the case of an esophageal hemangioma successfully treated with a combination of video-assisted thoracoscopy and endoscopy.

The patient was a 35-year-old woman suffering from occasional heartburn, and recently also progressive dysphagia, but no weight loss. Esophagogastroscopy showed a submucosal tumor 3 cm in diameter 30 cm from the incisors. The mucosa overlying the tumor was normal, as were the biopsies. Video-assisted thoracoscopy was carried out using four trocar sites and with simultaneous flexible esophagoscopy to help locate the tumor and check the resection line in order to prevent stenosis (Figure 1). In addition, the stapler line was also checked in water with the aid of the thoracoscope by blowing air into the esophagus. The patient's postoperative course was uneventful. At the follow-up six months after the operation, she was asymptomatic, and neither esophagoscopy nor a barium study showed any stenosis (Figure 2).

Flexible esophagoscopy in conjunction with video-assisted thoracoscopy helps locate the tumor by distending the esophageal wall, and it is also useful during the dissection. In addition, the stapler can be applied and fired under simultaneous endoscopic supervision, controlling the mucosal continuity. The underlying tumor usually distends the mucosa, so that the risk of stenosis of the operated segment after resection is minimal. However, in cases in which a submucosal hemangioma consists of more than half of the circumference of the esophageal lumen, we still do not recommend carrying out resection with a stapler. Checking the resection line intraesophageally before firing the stapler is of the utmost importance in preventing a stenotic complications.

O. J. Rämö¹, J. A. Salo¹, R. Bardini², A. T. Nemlander¹, M. Färkkilä³, S. P. Mattila¹

¹ Dept. of Thoracic and Cardiovascular Surgery

² Dept. of Surgery, University of Padua, Padua, Italy

³ Dept. of Internal Medicine, Helsinki University Central Hospital, Helsinki, Finland

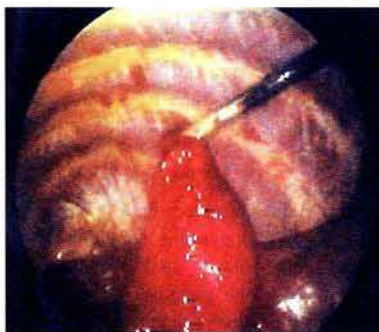


Figure 1: An esophageal myotomy was performed, but the tumor was adherent to the mucosa and could not be enucleated. The tumor was grasped by a thoracoscopic forceps and pulled laterally to create a margin wide enough for resection with a vascular endoscopic stapler (Endopath 35 Linear Vascular Cutter, Ethicon, Johnson and Johnson). The muscle layer was closed with interrupted sutures, and the overlying pleura with a running suture. The resection lines were checked, and closure of the stapler line was tested intraesophageally using simultaneous esophagoscopy.

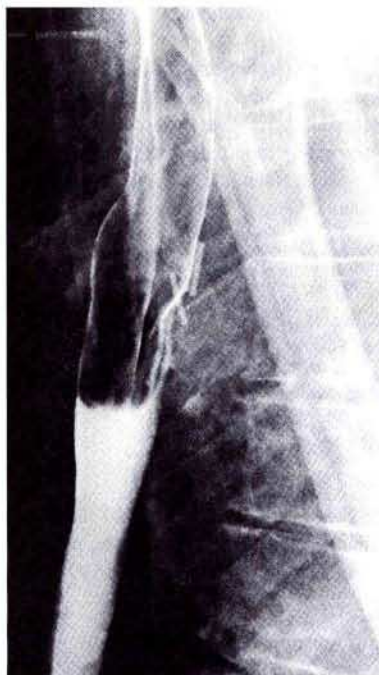

Figure 2: The barium study six months after the operation. No stenosis can be seen in the operated area (metal clips).

References

1. Attah EB, Hajdu SI. Benign and malignant tumors of the esophagus at autopsy. *J Thorac Cardiovasc Surg* 1968; 55: 396–404.
2. Cantero D, Yoshida T, Ito T, et al. Esophageal hemangioma: endoscopic diagnosis and treatment. *Endoscopy* 1994; 26: 250–3.
3. Salo JA, Kiviluoto T, Heikkilä L, et al. Enucleation of an intramural lipoma of the oesophagus by videothoracoscopy. *Ann Chir Gynaecol* 1993; 82: 66–9.
4. Bardini R, Segalin A, Ruol A, et al. Videothoracoscopic enucleation of esophageal leiomyoma. *Ann Thorac Surg* 1992; 54: 576.
5. Yoshikane H, Suzuki T, Yoshioka N, et al. Hemangioma of the esophagus: endosonographic imaging and endoscopic resection. *Endoscopy* 1995; 27: 267–9.

Corresponding Author

O. J. Rämö, M.D., Ph.D.
Dept. of Thoracic and Cardiovascular Surgery
Helsinki University Central Hospital
Haartmaninkatu 4
00290 Helsinki
Finland
Fax: +358-9-4059