

Cytomegalovirus Gastritis Simulating Cancer of the Linitis Plastica Type on Endoscopic Ultrasonography

Gastric cytomegalovirus (CMV) disease usually occurs in immunodepressed patients but has been described in previously healthy persons. In some cases, CMV disease simulates malignancy on gastric endoscopy [1–3].

A 53-year-old man was admitted to hospital with a three-day history of epigastric pain, vomiting and a 5-lb weight loss.

Gastrointestinal endoscopy revealed pan-gastric ulceration. Endoscopic ultrasonography (GF-UM 20; Olympus, Tokyo, Japan) showed a thickening of the stomach wall (15 mm) suggestive of gastric linitis (Figure 1). Gastric histological examination showed an ulcerated mucosa. Gastric percutaneous ultrasound-guided biopsy was negative, and a laparotomy was carried out for a large gastric biopsy. Histological

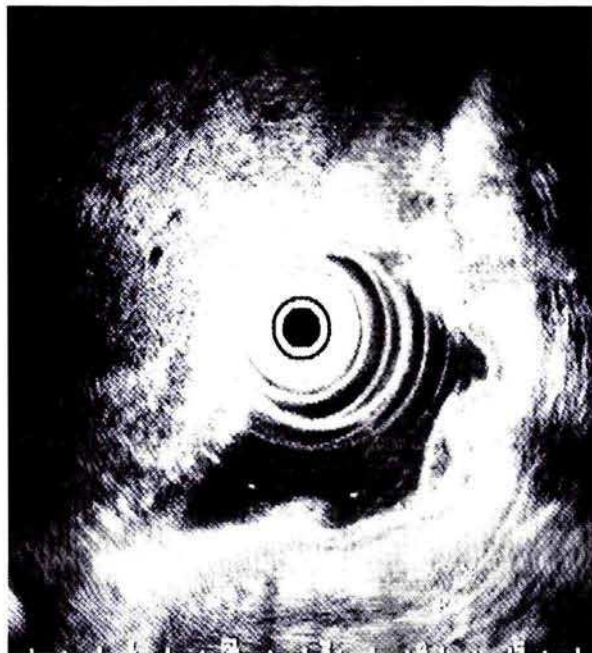

Figure 1 Endoscopic ultrasonogram obtained from the proximal stomach reveals an obvious thickening of gastric wall (+), predominantly of the submucosa layer (x)

examination of the surgical biopsy showed intranuclear inclusions compatible with CMV (Figure 2), and no malignant cells. CMV antibodies reacted with cytomegalic cells in immunohistochemical analysis. A thorough evaluation of the patient's immune system revealed no abnormalities. The outcome was favorable in the absence of specific antiviral therapy.

Cytomegalic cells were absent in the mucosal biopsy specimens but cytomegalic cells may be difficult to detect in gastrointestinal CMV disease [4]. CMV is a gastrointestinal pathogen but it can be a secondary invader; gastrointestinal CMV disease has been known to complicate the clinical course of a patient with a cancer [4]. In our patient, ultrasonography suggested gastric cancer of the linitis plastica type [5]. The yield from endoscopic biopsies is especially poor in infiltrative lesions. To exclude gastric malignancy, a surgical biopsy was done that showed cytomegalic cells and no malignant cells.

To our knowledge, the immunocompetent patient reported here represents the first instance of gastric CMV disease simulating cancer of the linitis plastica type on endoscopic ultrasonography.

J.-P. Lagasse¹, X. Causse¹, J.-L. Legoux¹, P. Leyman², D. Labarrière¹, H. Brun¹

¹ Dept. of Gastroenterology,
CHR D'Orléans, Orléans, France

² Dept. of Surgery,
CHR D'Orléans, Orléans, France

References

1. Garcia F, Garau J, Sierra M, Marco V. Cytomegalovirus mononucleosis-associated antral gastritis simulating malignancy. *Arch Intern Med* 1987; 147: 897-8
2. Andrade JS, Bampirra EA, Lima GF, Moreira EF, de Oliveira CA. Gastric cytomegalic inclusion bodies diagnosed by histologic examination of endoscopic biopsies in patients with gastric ulcer. *Am J Clin Pathol* 1983; 79: 493-6
3. Zucker GM, Otis C, Korow K, Navab F. Cytomegalovirus gastritis associated with pseudolymphoma. *J Clin Gastroenterol* 1994; 18: 222-6
4. Goodgame RW. Gastrointestinal cytomegalovirus disease. *Ann Intern Med* 1993; 119: 924-35

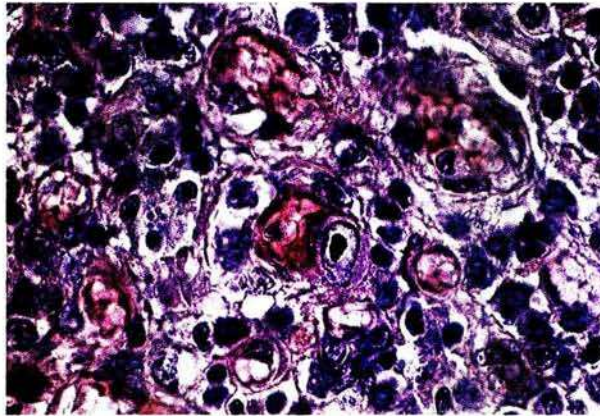


Figure 2 Photomicrograph of gastric surgical biopsy specimen. A large intranuclear inclusion body surrounded by clear halos is seen in the mucosal granulation tissue. (Hematoxylin and eosin; original magnification $\times 100$)

5. Tio TL. Large gastric folds evaluated by endoscopic ultrasonography. *Gastrointest Endosc Clin N Am* 1995; 5: 683-91

Corresponding Author

J.-P. Lagasse, M.D.
Service d'Hépatogastroentérologie
CHR D'Orléans, BP 6709
45067 Orléans Cedex 2, France
Fax: +33 (23) 8514694