

Gastrointestinal Involvement in Infections Caused by Varicella Virus

Varicella is a generally benign infectious disease. However, visceral dissemination may occur in immunodepressed patients, with complications usually in the form of encephalitis, pneumonitis, and, less frequently, myocarditis, nephritis, and hepatitis (1,2). An endoscopic diagnosis of gastric involvement is unusual.

We report here the case of a 50-year-old man diagnosed with multiple myeloma who underwent peripheral cell autotransplantation with chemotherapy and radiotherapy in 1994, and responded favorably. In 1995 he presented with epigastric pain, vomiting, and vesiculopapular eruption. Endoscopy revealed enlarged gastric folds with erosions in the body region; serpiginous ulcerations were observed in the antrum, together with erythematous macular zones (Figure 1) and small papular formations at the duodenal level (Figure 2). The biopsies revealed intranuclear inclusions with a ground-glass nuclear appearance and trinuclear forms of probable viral origin. Acyclovir treatment (10 mg/kg every eight hours i. v.) was started, with the diagnosis of disseminated varicella-zoster infection. At the follow-up endoscopy after 14 days, multiple gastric ulcers of different shapes and sizes were observed. Samples were collected for culture and viral DNA detection by polymerase chain reaction (PCR); the latter indicated varicella-zoster-specific DNA, thereby confirming the diagnosis of varicella-induced gastritis.

Varicella-zoster virus infection in immunodepressed individuals may give rise to severe problems, particularly in patients with hematological tumors. Some 50% of all patients who receive bone marrow transplants and survive for over six months are known to develop varicella-zoster virus infection (1). Gastric involvement is considered unusual (3,4). In the present patient PCR demonstrated the presence of specific varicella-zoster viral DNA in a gastric biopsy sample.

P. Rivera, P. Canelles, F. Quiles, E. Ortí, J. Cuquerella, E. Medina
Digestive Endoscopy Unit,
Valencia University General Hospital,
Valencia, Spain

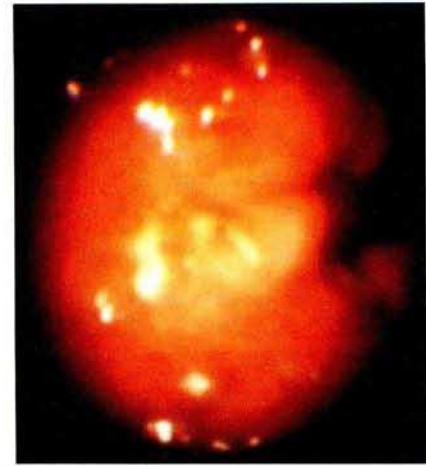


Figure 1: Ulceration of the gastric body region, with macular zone nearby.

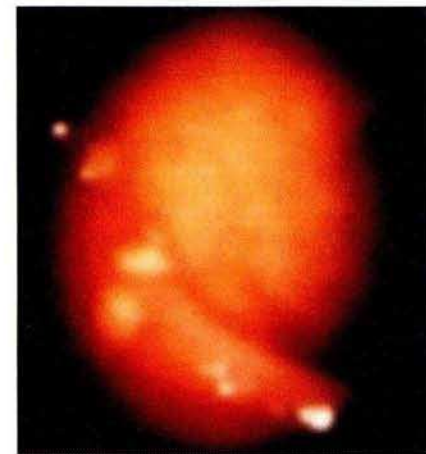


Figure 2: Papular formations at the bulbar level.

References

1. Atkinson K, Meyers JD, Storb R, et al. Varicella-zoster infection after marrow transplantation for aplastic anaemia or leukaemia. *Transplantation* 1980; 29: 47–50.
2. Fleisher G, Henry W, McSorley M, et al. Life-threatening complications of varicella. *Am J Dis Child* 1981; 135: 896–9.
3. Baker C, Gilsdorf J, South M, et al. Gastritis as a complication of varicella. *South Med J* 1973; 66: 539–41.
4. McCluggage WG, Fox JD, Baillie KE, et al. Varicella-zoster gastritis in a bone marrow transplant recipient. *J Clin Pathol* 1994; 47: 1054–6.

Corresponding Author
E. Medina, M.D.
C/Ciscar 40-13
46006 Valencia, Spain
Tel.: +34-6-3 74 31 65