

The prevalence of diverticular disease increases with age, and bleeding from colonic diverticula is the most common cause of acute lower gastrointestinal bleeding, accounting for approximately 40% of cases. The incidence of bleeding ranges from 5% to 50%. Because bleeding frequently stops spontaneously, the diagnosis is often presumptive and based on the exclusion of other sources of bleeding [1].

A 56-year-old man presented with painless hematochezia. He had no medical history of a bleeding tendency. Urgent colonoscopy demonstrated a large amount of fresh blood in the ascending colon, precluding adequate inspection of the mucosa. After extensive washing and instillation of water in the general area of the site, however, the bleeding diverticulum was clearly observed (Figure 1). We found that water instillation during the examination effectively enabled direct observation of the bleeding. The bleeding stopped after hemoclips were applied to the margin of the diverticulum (Figure 2). The patient remains well 12 months after the procedure.

Several endoscopic treatment modalities can be used to achieve hemostasis when a source of lower gastrointestinal bleeding is identified. Thermal-contact modalities, including a heat probe and bipolar or multipolar coagulation, and epinephrine injection can be used independently or together [2], but endoscopic placement of metallic clips might serve as a safe and effective treatment for diverticular hemorrhage [3]. The management of the patient presented here represents a case where effective detection and treatment of a bleeding colonic diverticulum was achieved.

Endoscopy_UCTN_Code_CCL_1AD_2AF

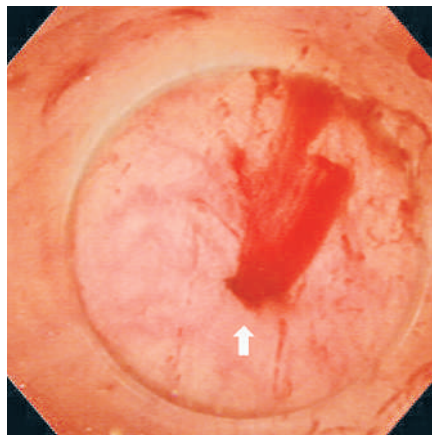


Figure 1 Bleeding from the diverticulum was clearly identified (arrow) using the water-instillation method.

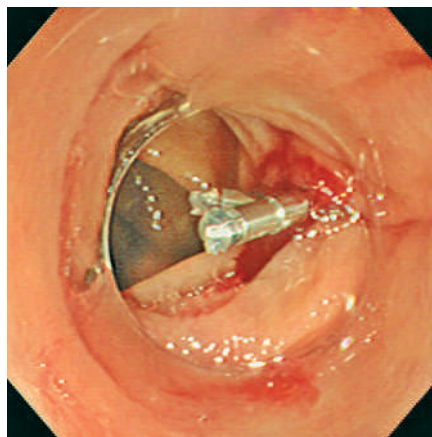


Figure 2 The bleeding stopped after two attempts at clip application.

**N. Ueno¹, H. Kawamura², Y. Abe²
H. Takahashi², M. Inamori²**

¹ Division of Endoscopy, Yokohama City University Hospital, Yokohama, Japan

² Third Department of Internal Medicine, Yokohama City University School of Medicine, Yokohama, Japan.

References

- ¹ Davila RE, Rajan E, Adler DG et al. ASGE Guideline: the role of endoscopy in the patient with lower-GI bleeding. *Gastrointest Endosc* 2005; 62: 656–660
- ² Jensen DM, Machicado GA. Diagnosis and treatment of severe hematochezia. The role of urgent colonoscopy after purge. *Gastroenterology* 1988; 95: 1569–1974
- ³ Binmoeller KF, Thonke F, Soehendra N. Endoscopic hemoclip treatment for gastrointestinal bleeding. *Endoscopy* 1993; 25: 167–170

Corresponding author

N. Ueno, MD

Division of Endoscopy
Yokohama City University Hospital
3-9 Fukuura
Kanazawa-ku
Yokohama 236-0004
Japan
Fax: +81-45-787-2511
Email: nu-1952@io.ocn.ne.jp