

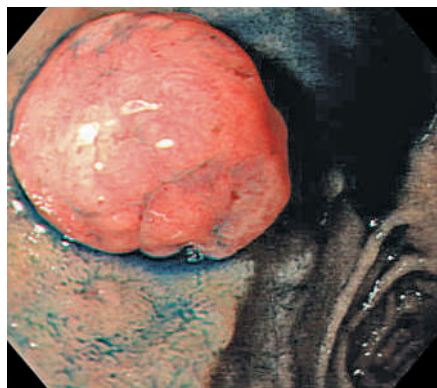Figure 1 The duodenal polypoid lesion at chromoendoscopy.

Brunner's gland adenoma is an extremely rare neoplasm, which may be confused with Brunner's gland hyperplasia or hamartoma. The present report describes a case of "true" Brunner's gland adenoma resected by surgery.

An 82-year-old man with a duodenal polyp was admitted to hospital for surgical treatment of newly diagnosed gastric cancer. Gastroduodenoscopy revealed a 12-mm subpedunculated polypoid lesion, covered with smooth, reddish mucosa, in the duodenal bulb (Figure 1). Distal gastrectomy was carried out for the gastric cancer and for the duodenal polypoid lesion.

Histologically, the duodenal polypoid lesion was found to consist of Brunner-like glands with moderate nuclear atypia. Nonneoplastic Brunner's gland hyperplasia was seen at the basal side of the polypoid lesion (Figure 2). Figure 2b shows the transition from the hyperplastic area to the adenomatous area. Immunohistochemically, the adenomatous Brunner-like glands were positive for MUC6, showing that they originated from Brunner's glands. The surface of the polypoid lesion was covered with gastric foveolar-like glands.

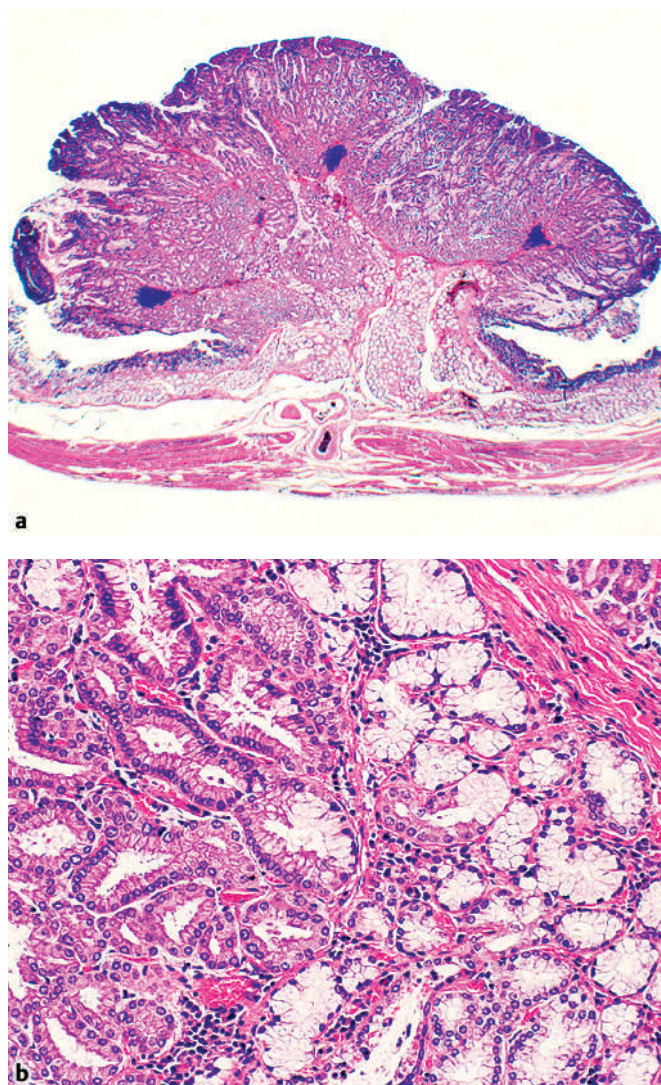


Figure 2 a, b The histological appearance of the polypoid lesion, showing the transition from the Brunner's gland hyperplastic area to the adenomatous area. a Hematoxylin–eosin, original magnification $\times 30$. b Hematoxylin–eosin, original magnification $\times 50$.

Brunner's gland adenoma is extremely rare, representing only 10.6% of benign duodenal tumors [1], which are themselves rare at 0.008% of all surgical and autopsy specimens. Matsumoto et al. reported a case of a large Brunner's gland adenoma removed by endoscopic polypectomy [2]. Fujimaki et al. reported a case of duodenal polypoid lesion consisting mainly of hyperplastic Brunner's glands, but with a focus of atypical glands consisting of cells with nuclear atypia [3]. There have been reports of neoplasia oc-

curing in Brunner's gland hyperplasia [4]. The present case shows a transition from a hyperplastic area in the Brunner's glands to an adenomatous area, showing that a "true" Brunner's gland adenoma can exist and suggesting its etiology.

Endoscopy_UCTN_Code_CCL_1AB_2AZ_3AB

**K. Suda¹, S. Hamada¹, M. Takahashi¹,
Y. Kumashiro², T. Yao², K. Sugimachi³,
D. Korenaga³, K. Takenaka³**

¹ Dept. of Internal Medicine, Fukuoka City Hospital, Fukuoka, Japan

² Dept. of Anatomic Pathology, Kyushu University, Fukuoka, Japan

³ Dept. of General Surgery, Fukuoka City Hospital, Fukuoka, Japan.

References

- ¹ Nakanishi T, Takeuchi T, Hara K, Sugimoto A. A great Brunner's gland adenoma of the duodenal bulb. *Dig Dis Sci* 1984; 29: 81 – 85
- ² Matsumoto T, Iida M, Matsui T et al. A large Brunner's gland adenoma removed by endoscopic polypectomy. *Endoscopy* 1990; 22: 192 – 193
- ³ Fujimaki E, Nakamura S, Sugai T, Takeda Y. Brunner's gland adenoma with a focus of p53-positive atypical glands. *J Gastroenterol* 2000; 35: 155 – 158
- ⁴ Doi K, Tada S, Fujimoto T et al. Successful endoscopic removal of a duodenal adenoma occurring in Brunner's gland hyperplasia. *Dig Endosc* 2004; 16: 148 – 151

Corresponding author

K. Suda, M.D.

Dept. of Internal Medicine
Fukuoka City Hospital
Yoshizuka-honmachi 13-1
Fukuoka 812-0046

Japan

Fax: +81-92-632-0900

Email: md199055@yahoo.co.jp