

A 27-year-old woman presented with a history of gastrointestinal bleeding. Her medical history was otherwise unremarkable. Esophagogastroduodenoscopy and colonoscopy of the terminal ileum were carried out after an episode of gastrointestinal bleeding, but the source of the bleeding remained unidentified. Double-balloon enteroscopy of the small intestine [1] was then conducted via the anal approach. Examination of the distal ileum disclosed a diverticulum with an ulceration at about 50 cm proximal to the ileocecal valve (Figure 1). Radiography showed a diverticulum 6 cm long in the ileum (Figure 2). Biopsy specimens from the diverticulum revealed gastric mucosa (Figure 3). The ulcer was thought to be caused by ectopic gastric mucosa.

Meckel first reported this type of abnormality in 1809, and its frequency in autopsy series has been reported to range from 0.2% to 3.0% [2]. In patients with small-intestinal bleeding, Meckel's diverticulum is the cause of the bleeding in 4.7–8.7% of cases [3]. Gastric mucosa has been found to be present in 62.4% of patients with ectopic mucosa [4]. The percentage of patients with ectopic gastric mucosa among those with diverticular bleeding has been reported to range from 77.8% to 98.0% [5]. With regard to the treatment for Meckel's diverticulum, surgery has been the routine procedure for patients with symptoms. However, in the present case, the Meckel's diverticulum was observed during double-balloon enteroscopy, and an ulcer was found at the orifice of the diverticulum. As the ulcer was in a healing stage, medical treatment was

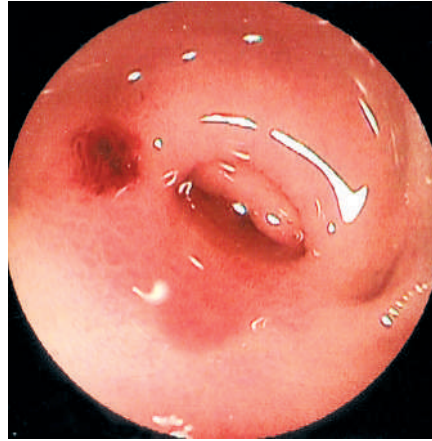


Figure 1 A healing stage ulcer was observed around the orifice of the blind sac.

continued. At the time of writing, the patient was doing well with medical treatment. However, careful observation of the patient is continuing, in view of the potential for future complications. If a complication occurs, surgical intervention will be carried out.

Endoscopy_UCTN_Code_CCL_1AC_2AF

**Y. Nakashima¹, I. Nakamura¹,
H. Miyatani¹, Y. Yoshida¹, F. Konishi²,
S. Yamada³**

¹ Dept. of Gastroenterology, Jichi Medical University, Omiya Medical Center, Omiya, Saitama, Japan

² Dept. of Surgery, Jichi Medical University, Omiya Medical Center, Omiya, Saitama, Japan

³ Dept. of Pathology, Jichi Medical University, Omiya Medical Center, Omiya, Saitama, Japan.

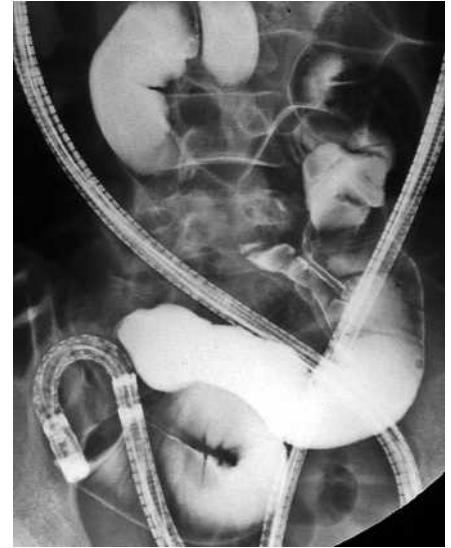


Figure 2 Infusing gastrographin showed a diverticulum of the ileum.

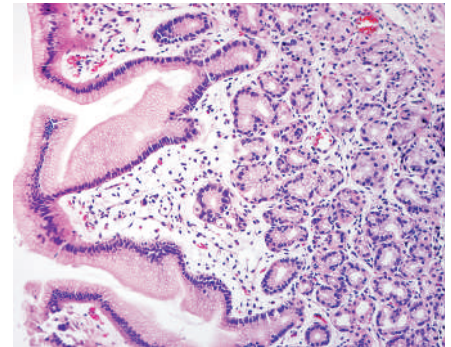


Figure 3 The biopsy specimens taken from the blind end of the diverticulum showed gastric fundic gland mucosa.

References

- ¹ Yamamoto H, Kita H, Sunada K et al. Clinical outcomes of double-balloon endoscopy for the diagnosis and treatment of small-intestinal diseases. *Clin Gastroenterol Hepatol* 2004; 2: 1010–1016
- ² Meckel JF. Über die Divertikel am Darmkanal. *Arch Physiol* 1809; 9: 421–453
- ³ Tanaka S, Orita K, Kunimai T et al. A Meckel diverticulum. Statistical consideration of 444 examples; in Japanese. *Geka Tiryo* 1971; 13: 818–826
- ⁴ Mackey WC, Dineen P. A fifty year experience with Meckel's diverticulum. *Surg Gynecol Obstet* 1983; 156: 56–64
- ⁵ Berman EJ, Schnider A, Potts WJ. Importance of gastric mucosa in Meckel's diverticulum. *JAMA* 1954; 156: 6–7

Corresponding author

Y. Nakashima, M.D.

Dept. of Gastroenterology
Jichi Medical School
Omiya Medical Center
1-847 Amanuma
Omiya
Saitama 330-8503
Japan
Fax: +81-48-6485188
Email: doc_naka@hotmail.co.jp