

A 75-year-old woman with severe mixed connective tissue disorder and hypertension presented with worsening diarrhea, nausea and vomiting. On admission she complained of 10–12 episodes of watery diarrhea which also occurred at night. The patient had suffered from diarrhea for 2 months, and during these last 2 months she had received antibiotic therapy twice, first to treat a pneumonia and then to treat a urinary tract infection. When she first developed diarrhea it was assumed that it was antibiotic-associated and she was given empiric therapy for *Clostridium difficile* infection. Her diarrhea had improved slightly, but the stool had remained soft until a week prior to the present admission, when worsening watery diarrhea had begun again. The bowel movements were associated with tenesmus but without passage of blood or mucus. The patient was taking the following medications: oral corticosteroids, CellCept, amlodipine, metoprolol, torsemid, and potassium chloride. She was admitted with clinical and laboratory evidence of dehydration. Physical examination was notable for a low-grade fever (37.9°C). The abdomen was tympanitic, with normal bowel sounds, tenderness to palpation in both lower quadrants, but no rebound pain. Digital rectal examination revealed liquid yellow, guaiac-positive stool. Laboratory values (normal values in parentheses) on admission were notable for white blood cell count of 12 800/ml (4.300–10.000/ml), hemoglobin 6.5 g/dl (12.0–16.0), albumin 2.3 g/dl (3.5–5.5), creatinine 208 µmol/ml (<120), and C-reactive protein of 230.2 (<5). Stool studies for ova and parasites, culture and sensitivity, fecal leukocytes, and *C. difficile* toxin were obtained. Stool tests for *C. difficile* toxin were negative on three occasions. Colonoscopy revealed multiple pseudomembranes (Figure 1). These were most prominent in the rectum and sigmoid but extended to the right colon. Histological findings were consistent with pseudomembranous colitis. There were no histologic findings suggestive of inflammatory bowel disease, ischemic coli-

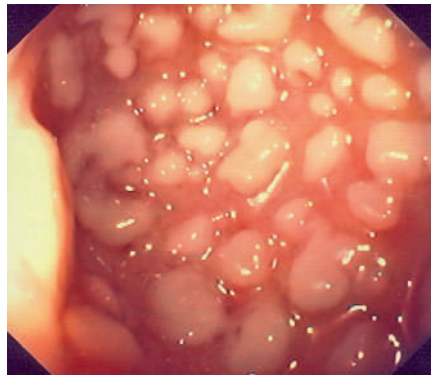


Figure 1 On colonoscopy, the colon mucosa was seen to be diffusely edematous and erythematous, and covered with multiple elevated, white-yellowish, small-sized plaques resembling those found in pseudomembranous colitis.

tis or viral infection [1]. Immunohistological stains were negative for cytomegalovirus (CMV). Based on the endoscopic findings, treatment with oral metronidazole was initiated. Immunosuppressive therapy was temporarily discontinued. Despite therapy with metronidazole, the patient had persistent diarrhea. Final stool culture results disclosed *Salmonella enterica* serotype *infantis* colitis. Antibiotic therapy was changed to ceftriaxone, after which she showed gradual improvement. Colonoscopy performed 4 weeks later was entirely normal. At follow-up, 4 months later, she did not have any diarrhea. Our case has potential important clinical implications because it demonstrates that pseudomembranous colitis may occur secondary to other microorganisms besides *C. difficile*. A *C. difficile* cytotoxin assay that has 94% to 100% sensitivity was negative on these occasions. A review of the literature revealed that there can be other etiologies for pseudomembranous colitis, such as CMV, *Shigella*, and *Plesiomonas shigelloides*, as well as ischemia, and medicines such as gold and diclofenac [2–5]. In a recent endoscopic study, Yuani et al. suggested that pseudomembranes can also be part of the spectrum of collagenous colitis itself [6]. Our case, like others, emphasizes that pseudomembranes may not be pathognomonic for *C. difficile* colitis. We believe that *Sal-*

monella colitis should be added to the list of potential etiologies of pseudomembranous colitis [2–5]. In summary, in the presence of pseudomembranous colitis and negative *C. difficile* assays, further investigations should be performed to try to establish an alternative etiology and institute appropriate therapy.

K. Mönkemüller¹, I. Patašūtė²,
F. Walther¹, U. Peitz¹, L. C. Fry¹,
P. Malfertheiner¹

¹ Department of Internal Medicine, Gastroenterology, Hepatology and Infectious Diseases, Universitätsklinikum Magdeburg, Otto-von-Guericke University, Magdeburg, Germany

² Department of Gastroenterology, Kaunas University of Medicine, Kaunas, Lithuania.

References

- Dignan CR, Greenson JK. Can ischemic colitis be differentiated from *C. difficile* colitis in biopsy specimens? *Am J Surg Pathol* 1997; 21: 706–710
- Battaglini MP, Rockey DC. Cytomegalovirus colitis presenting with the endoscopic appearance of pseudomembranous colitis. *Gastrointest Endosc* 1999; 50: 697–700
- Van Loon FP, Rahim Z, Chowdhury KA et al. Case report of *Plesiomonas shigelloides*-associated persistent dysentery and pseudomembranous colitis. *J Clin Microbiol* 1989; 27: 1913–1915
- Gentric A, Pennee YL. Diclofenac-induced pseudomembranous colitis. *Lancet* 1992; 340: 126–127
- Reinhart WH, Kappeler M, Halter F. Severe pseudomembranous and ulcerative colitis during gold therapy. *Endoscopy* 1983; 15: 70–72
- Yuan S, Reyes V, Bronner MP. Pseudomembranous collagenous colitis. *Am J Surg Pathol* 2003; 27: 1375–1379

Corresponding Author

P. Malfertheiner, M. D.

Universitätsklinikum Magdeburg,
Otto-von-Guericke University, Leipziger
Strasse 44, 39112 Magdeburg, Germany,
Fax: +49-391-6715159, E-mail:
Klaus.MoenkemueLLer@medizin.
uni-magdeburg.de

DOI: 10.1055/s-2006-925343