

Mucosal Tears Can Occur Spontaneously in Collagenous Colitis

A. Koulaouzidis¹, J. A. Henry²,
A. A. Saeed¹

¹ Combined Medical Gastroenterology
Unit, Queen Elizabeth Hospital,
Gateshead, UK

² Histocytology Department, Queen
Elizabeth Hospital, Gateshead, UK

Corresponding Author

A. Saeed, M.D.

1 Sheriff Mount South, Old Durham Road
Gateshead NE9 6SX, Tyne and Wear, UK
Fax: +44 191 3653
E-mail: asaheed@doctors.org.uk

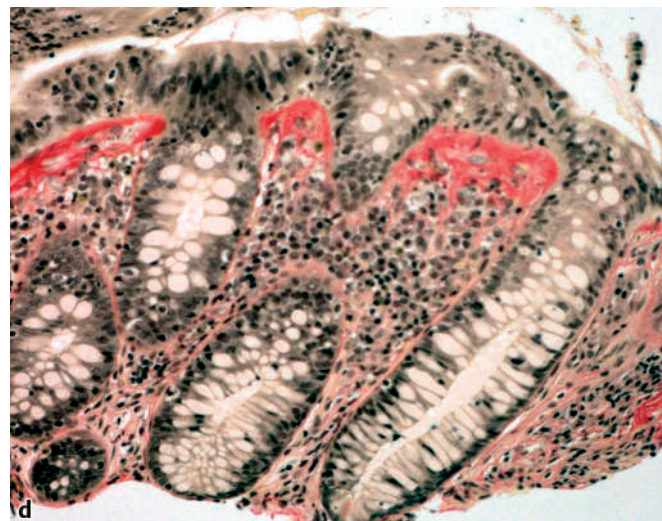
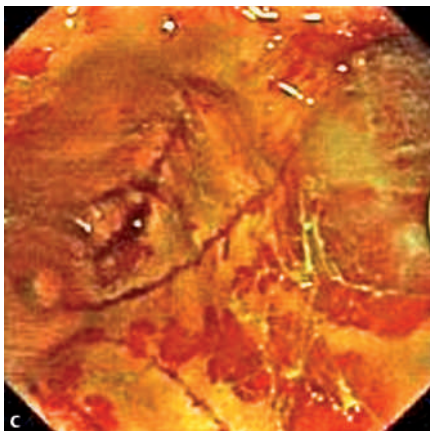
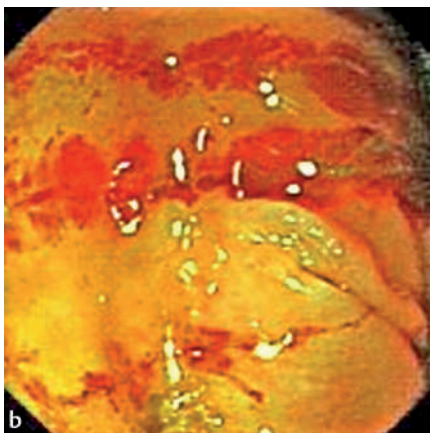
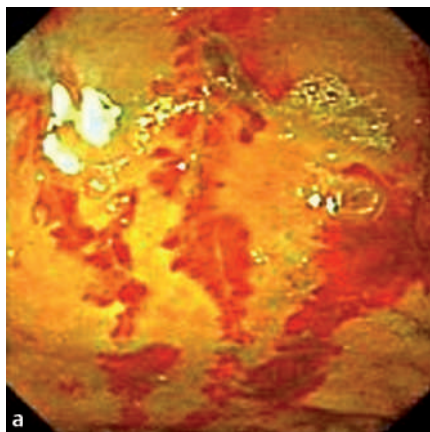


Figure 1 An 83-year-old lady with intractable non-bloody diarrhoea of over 3 months' duration, was found to be anaemic, with a haemoglobin value of 10.0 g/dl (normal range 11.5–16.5 g/dl) and mean corpuscular volume of 72.6 fl (normal 80–102 fl). Oesophagogastroduodenoscopy and duodenal biopsies were normal. At colonoscopy, the caecum was easily reached after gentle insufflation, and discrete linear mucosal breaks were found. We propose that these mucosal tears were spontaneous, not caused by scope trauma but by the stiffness of the colonic wall and normal contractions of the bowel. Mucosal tears in the caecum in collagenous colitis have not been described before. In addition, these tears probably caused this patient's iron-deficiency anaemia. **a–c** Mucosal tears. **d** Van Gieson stain; original magnification $\times 100$.