

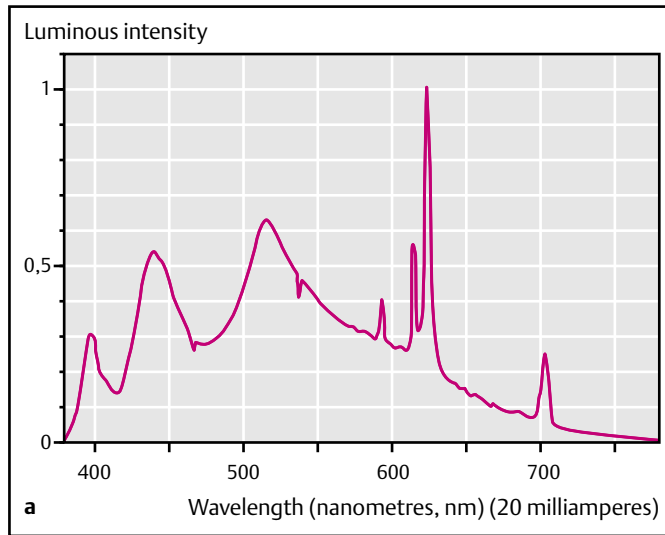
Figure 1 **a** The spectral characteristics of the new white light-emitting diode (LED) with the main peak of luminous intensity in the red range (600 nm). **b** Appearance of the prototype new white LED-illuminated endoscope (CCD, charge-coupled device).



In the conventional video endoscope system, a large light source apparatus and light-guiding fibre bundle are essential [1]. The capsule endoscope is mainly useful for disease of the small intestine [2]. Recently, the light-emitting diode (LED) has been rapidly developed as a new compact, powerful light source [3]. We have developed an new experimental prototype LED-illuminated gastrointestinal endoscope.

For many conventional white LEDs, the peak luminous intensity is at a wavelength of 450 nanometers (nm) in the blue range of the spectrum, and the color rendering in the clinically important red range at around 600 nm is thought to be insufficient. Our new white LED (developed by T. Taguchi) has its main peak of luminous intensity in the red range (Figure 1a) [4]. It is a one-chip type orange-yellow-green-blue white LED based on a near-ultraviolet light-emitting diode with the highest luminous efficiency (43%). The prototype scope was mounted with two packages of 12 elements of the new white LED (Figure 1b) (Fujinon Corporation, Saitama, Japan). We conducted esophagogastroduodenoscopy in the beagle, using painless procedures (at the Yamamoto Animal Hospital, Ube, Japan) with the approval of the institutional review board. The esophageal mucosa of

the beagle was observed clearly with sufficient luminous intensity. Color rendering in the red range was good, and the red areas on the gastric mucosa and blood vessels were observed in color tones that were satisfactory for endoscopic purposes (Figure 2a, b).

The use of LEDs may enable the miniaturization of the whole endoscope system and remove constraints on the design of its shape. In contrast to the capsule type, the LED-illuminated endoscope is expected to retain all the functions of the conventional endoscope such as operability and biopsy [5]. We believe the new LED-illuminated endoscope will help us to perform routine gastrointestinal endoscopy safely and effectively.

Acknowledgment

Supported by a grant from the Intelligent Cluster Project of the Ministry of Education, Culture, Sports, Science and Technology, Japan.

Competing interests: None

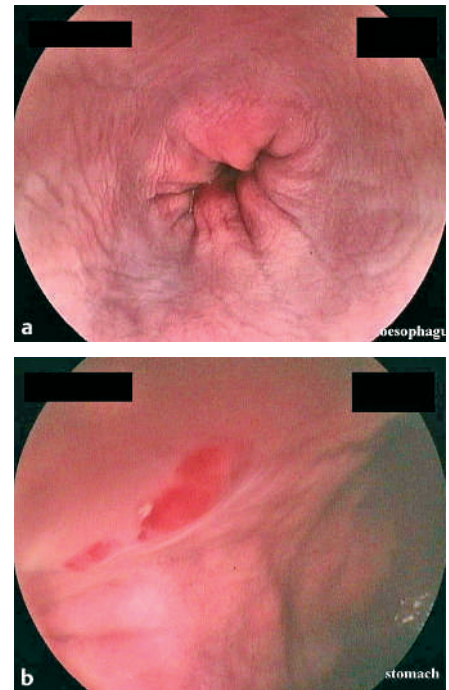


Figure 2 In vivo endoscopic images from a beagle, using the new white LED illumination: **a** the esophagus, and **b** the red areas of the gastric mucosa.

H. Yanai¹, K. Okita², K. Kikuchi³,
K. Tadatomo⁴, H. Nakamura²,
J. Nishikawa², T. Yoshida², T. Taguchi⁴

¹ Department of Gastroenterology and Hepatology, National Hospital Organization Kanmon Medical Center, Shimonoseki, Japan

² Department of Gastroenterology and Hepatology, Yamaguchi University School of Medicine, Ube, Japan

³ Fujinon Corporation, Saitama, Japan

⁴ Department of Electrical and Electronic Engineering, Faculty of Engineering, Yamaguchi University, Ube, Japan

References

- ¹ Schuman BM. Upper gastrointestinal endoscopy. In: Haubrich WS, Schaffner F, Berk JE (eds). *Bockus Gastroenterology*. Philadelphia: W. B. Saunders 1995: 295–309
- ² Pennazio M, Santucci R, Rondonotti E et al. Outcome of patients with obscure gastrointestinal bleeding after capsule endoscopy: report of 100 consecutive cases. *Gastroenterology* 2004; 126: 643–653
- ³ Nakamura S, Fasol G. *The blue laser diode*. Berlin: Springer-Verlag 1997: 216–221
- ⁴ Taguchi T. Present status of white LED lighting technology in Japan. *J Light Vis Env* 2003; 27: 1–6
- ⁵ Yanai H, Nakamura H, Okita K. Development of the white light-emitting diode-illuminated digestive endoscope [abstract]. *Gastrointest Endosc* 2004; 59: AB145

Corresponding Author

H. Yanai, M.D.

Department of Gastroenterology
and Hepatology
National Hospital Organization Kanmon
Medical Center
Ushiroda 1-1-1
Shimonoseki
Yamaguchi 751-8501
Japan
Fax: +81-832-34-1416
Phone: +81-832-22-6216
E-mail: yanaih@simonoseki2.hosp.go.jp