

A 77-year-old woman was admitted because she had been passing tarry stools for 1 week. She had a past medical history of hypertension, coronary artery disease, and uremia requiring dialysis. Following negative upper endoscopy and colonoscopy examinations, she underwent double-balloon enteroscopy. Several blood clots were found in the jejunum and a source of active bleeding was found after 2 hours' examination (Figure 1). Injection therapy with a total of 3 ml of 1 in 10 000 epinephrine in hypertonic saline resulted in initial hemostasis, but the bleeding recurred 2 days later. The patient required surgical intervention, when segmental ecchymosis of the intestine was observed, 280 cm from the ileocecal valve (Figure 2). The remaining small intestine was unremarkable. Subsequent histological examination revealed ischemic necrosis, involving only 1.5 cm of the resected intestine, which we believed corresponded with the injection site. The patient experienced no further bleeding over a 6-month period after the operation.

Since the introduction of double-balloon enteroscopy [1], endoscopists have been expected to perform an increasing number of diagnostic and therapeutic procedures involving the small intestine using this technique [2,3]. However, experience of therapeutic endoscopy in the small intestine is limited and we experienced two problems related to the procedure in this patient. Firstly, endoscopic examination for the investigation of active small-bowel bleeding is particularly difficult: prolonged procedure times and large volumes of irrigation fluids may be required, and patient intolerance and fluid overload are potential problems. Secondly, injection therapy, using a variety of solutions, has been deployed in order to control peptic ulcer bleeding [4]. In this patient, the finding of intestinal necrosis at the injection site highlighted the problems of the optimal volume and the safety of solutions used for injection therapy in the small intestine. Advanced age, atherosclerotic vascular disease, anemia, hypox-

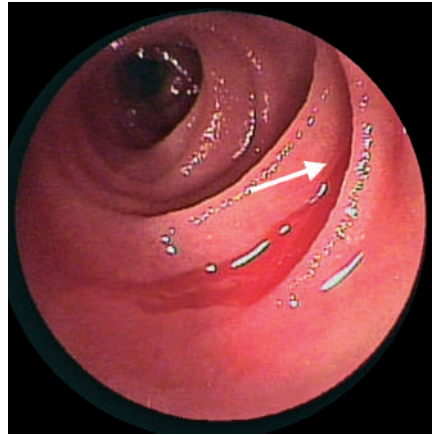


Figure 1 Endoscopic view showing active bleeding from a mucosal fold (arrow). The adjacent intestinal mucosa was intact. It was difficult to visualize the source of bleeding, but it was presumed to be a bleeding angiodysplastic lesion.

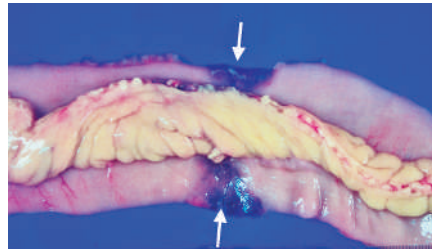


Figure 2 Macroscopic view of the resected small intestine. Note the band-like ischemic change (arrows).

emia, and shock are all associated with intestinal necrosis following injection therapy [5]. In addition, the thinner wall of the small intestine may make this complication more likely during double-balloon enteroscopy. Therapeutic endoscopists should be aware of this complication. Further studies are necessary to evaluate the safety of endoscopic procedures when applied to the small intestine.

Competing Interests: None

H.-H. Yen¹, Y.-Y. Chen¹, W.-W. Su¹, M.-S. Soon¹, Y.-M. Lin²

¹ Department of Gastroenterology, Changhua Christian Medical Center, Changhua, Taiwan

² Department of Pathology, Changhua Christian Medical Center, Changhua, Taiwan

References

- 1 Yamamoto H, Sekine Y, Sato Y et al. Total enteroscopy with a nonsurgical steerable double-balloon method. *Gastrointest Endosc* 2001; 532: 216–220
- 2 Yamamoto H, Kita H, Sunada K et al. Clinical outcomes of double-balloon enteroscopy for the diagnosis and treatment of small-intestinal diseases. *Clin Gastroenterol Hepatol* 2004; 2: 1010–1016
- 3 May A, Nachbar L, Ell C. Double-balloon enteroscopy (push-and-pull enteroscopy) of the small bowel: feasibility and diagnostic and therapeutic yield in patients with suspected small bowel disease. *Gastrointest Endosc* 2005; 62: 62–70
- 4 Nelson DB, Barkun AN, Block KP et al. Technology status evaluation report: endoscopic hemostatic devices. May 2001. *Gastrointest Endosc* 2001; 54: 833–840
- 5 Hilzenrat N, Lamoureux E, Alpert L. Gastric ischemia after epinephrine injection for upper GI bleeding in a patient with unsuspected amyloidosis. *Gastrointest Endosc* 2003; 58: 307–308

Corresponding Author

Y.-Y. Chen, M.D.

Changhua Christian Medical Center
135 Nanshiao Street
Changhua
500 Taiwan

Fax: +886-4-7228289

E-mail: 27716@cch.org.tw