

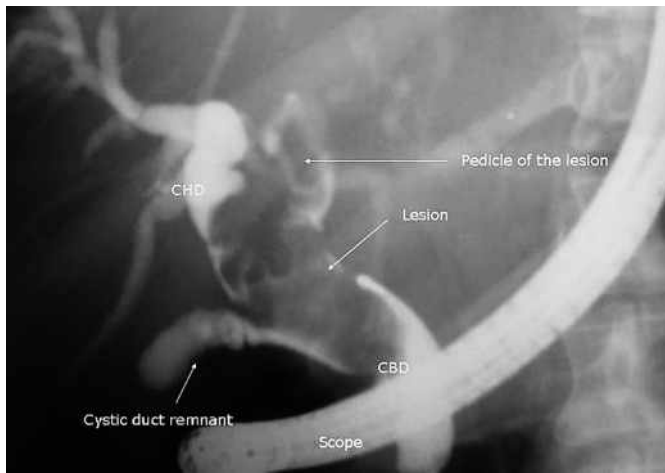Figure 1 A 42-year-old woman presented with jaundice, right upper quadrant pain and pruritus. Laboratory test findings were: hemoglobin (Hb) 11.1; bilirubin 4.6; aspartate aminotransferase (AST) 34; alanine aminotransferase (ALT) 38; prothrombin time (PT) 16; and alkaline phosphatase 1083. Abdominal sonography revealed dilatation of the intra- and extrahepatic biliary ducts. Endoscopic retrograde cholangiopancreatography (ERCP) showed dilated bile ducts with a large lobulated filling defect in the proximal portion of the common bile duct toward the intrahepatic ducts. CBD, common bile duct; CHD, common hepatic duct.

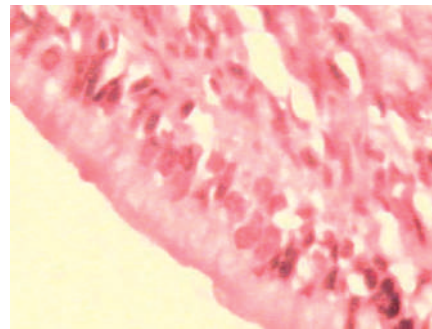


Figure 3 Histological investigation demonstrated a choledochal cystadenoma.

**A. Hedayat¹, R. Sotoudehmanesh²,
M. Khatibian², H. Mahmoudzadeh¹,
M. Sotoudeh³**

¹ Department of Surgery, Tehran University of Medical Sciences, Tehran, Iran

² Digestive Disease Research Center, Tehran University of Medical Sciences, Tehran, Iran

³ Department of Pathology, Shariati Hospital, Tehran University of Medical Sciences, Tehran, Iran

Corresponding Author

R. Sotoudehmanesh, M.D.
Digestive Disease Research Center,
Shariati Hospital
North Kagar Avenue, 14114 Tehran, Iran
Fax: +98-21-8012992
E-mail: setoodeh@ams.ac.ir

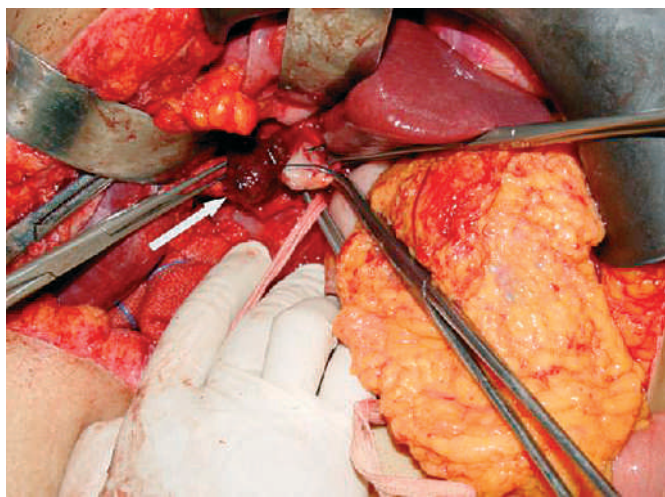


Figure 2 During surgery a pedunculated mass lesion was seen extending from the left hepatic duct to the mid-portion of the CBD.