

A 78-year-old woman developed severe gastric retention after a transhiatal esophagectomy with gastric tube reconstruction.

A diagnostic upper endoscopy revealed an obliteration of the middle part of the gastric tube, with gastric folds that resembled a spiral (Figure 1). The stenosis itself was elastic and could be passed easily (Figure 2). The behavior on dilation with a balloon, with immediate recoil after desufflation, was very suggestive of a volvulus of the gastric tube. Compression from a mediastinal mass was ruled out by means of computed tomography (CT) scan.

The general condition and age of the patient prompted us to position a self-expandable uncovered Ultraflex stent (Microvasive, Natick, Massachusetts, USA). After performing successfully for 2 years, the uncovered stent became displaced and was endoscopically removed. To our surprise, endoscopy revealed a normal gastric tube lumen without the previous spiralling obliteration; gastric retention did not recur.

To our knowledge, only one other similar case is reported in the literature; in that case a gastropexy was performed. Bleeding from the right gastroduodenal artery complicated surgery and the intrathoracic stomach, deprived of its blood supply, was lost [1].

We avoided surgery by placing a metal stent. The Ultraflex stent has the smallest radial force amongst the currently available stents and the expansion is gradual, thus decreasing stent-related complications. The diameter of the lumen and its flexibility improves the quality of swallowing compared with prosthetic tubes [2]. The chance of maintaining the stent's position in an elastic stenosis might be greater, and the stent can easily be removed if necessary [3].

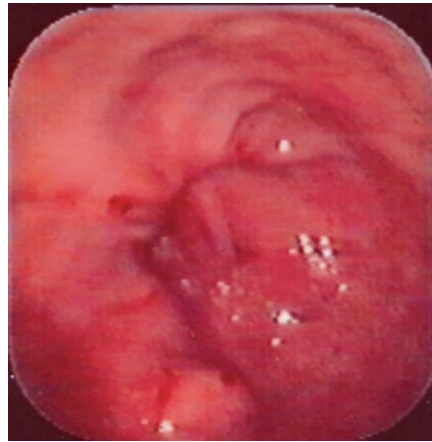


Figure 1 Upper endoscopy revealed an obliteration of the middle third of the gastric tube after transhiatal esophagectomy, with gastric folds that resembled a spiral.

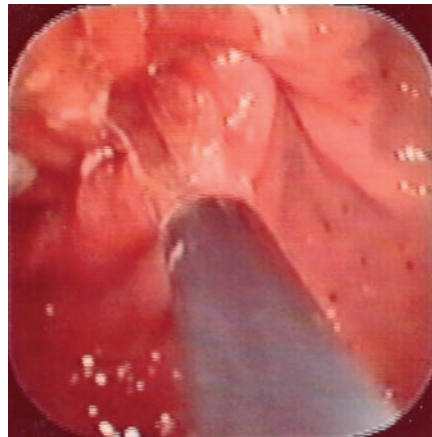


Figure 2 The stenosis itself was very elastic and the endoscope was passed through easily.

We can only hypothesize that the gastric tube had fibrosed in a new anatomic layer in an unwound position. Because of the fibrosis, the spiralling obliteration did not recur. We now believe that placement of an uncovered expandable stent, thus avoiding surgery, can be a good therapeutic option.

S. Donkervoort¹, B. van Ramshorst², R. Timmer²

¹ Department of Surgery, Ziekenhuis Hilversum in Hilversum, The Netherlands

² Department of Surgery and Gastroenterology, Sint Antonius Hospital, Nieuwegein, The Netherlands.

References

- 1 Casson A, Inculet R, Finley R. Volvulus of the intrathoracic stomach after total esophagectomy. *J Thorac Cardiovasc Surg* 1990; 100: 633–634
- 2 Siersema PD, Macon N, Vakil N. Metal stents for tumors of the distal esophagus and gastric cardia. *Endoscopy*. 2003; 35: 79–85
- 3 Cwikiel W, Willen R, Stridbeck H et al. Self-expanding stent in the treatment of benign esophageal strictures; experimental study in pigs and presentation of clinical cases. *Radiology* 1993; 187: 667–671

Corresponding Author

S. C. Donkervoort, M.D.

Department of Surgery
Ziekenhuis Hilversum
Postbus 10016

1201 DA Hilversum

The Netherlands

Fax: +31-35-6887062

E-mail: sdonkervoort@zhh.nl