

A 56-year-old man was referred to our institution with symptoms of chest discomfort, which had persisted for a month. The physical examination was unremarkable, and laboratory data revealed no abnormalities. A barium meal examination showed a round radiolucent area in the middle third of the esophagus (Figure 1). Upper endoscopy revealed a sessile, protruding lesion, which was brownish-red with a white coating on the top (Figure 2). In view of the patient's symptoms and the risk of bleeding, endoscopic mucosal resection of the tumor was carried out, without any complications. Histologically, the tumor was located in the proper mucosal layer, covered by normal squamous epithelium (Figure 3). The resected margin was free of tumor cells. High-power magnification showed that the tumor was composed of various-sized capillaries proliferating in a lobular fashion, accompanied by an edematous stroma. On the basis of these findings, the tumor was diagnosed as a pyogenic granuloma. A follow-up endoscopic examination 6 months later revealed a scarred ulcer,

with no evidence of recurrence. In the field of dermatology and oral surgery, pyogenic granuloma is a common neoplasm, which is considered to be benign in nature. However, the tumor is known to recur frequently after resection [1,2]. The occurrence of pyogenic granuloma in the gastrointestinal tract is extremely rare, and only nine such cases have been reported in the literature [3–5]. Pyogenic granulomas of the gastrointestinal tract have been treated using surgical resection or endoscopic snare polypectomy, due to bleeding or an increase in size. Recurrences of gastrointestinal pyogenic granuloma have not previously been described in detail, and the tumor in this case was removed completely using endoscopic mucosal resection, with no sign of recurrence at 6 months. This procedure may make it

possible to resect pyogenic granuloma completely, as confirmed in this case.

**N. Okada<sup>1</sup>, T. Matsumoto<sup>2</sup>, K. Kurahara<sup>1</sup>, K. Kanamoto<sup>1</sup>, T. Fukuda<sup>3</sup>, Y. Okada<sup>3</sup>, M. Iida<sup>1</sup>**

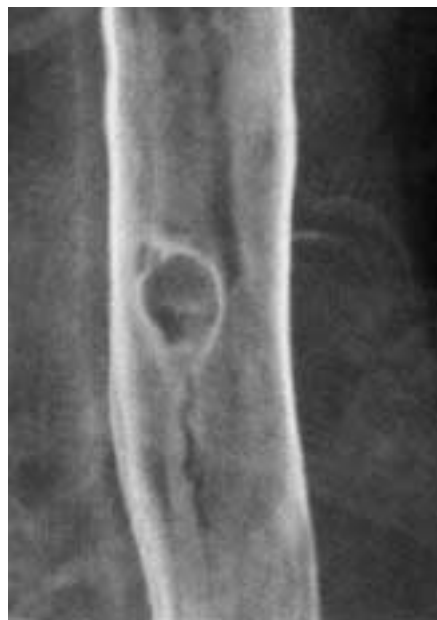<sup>1</sup> Department of Medicine and Clinical Science, Graduate School of Medical Sciences, Kyushu University, Fukuoka, Japan

<sup>2</sup> Department of Endoscopic Diagnosis and Therapeutics, Kyushu University Hospital, Fukuoka, Japan

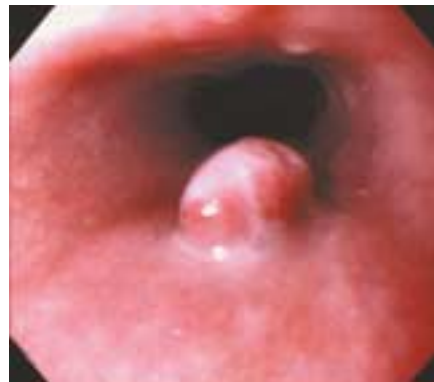<sup>3</sup> Fukuoka Red Cross Hospital, Fukuoka, Japan

## References

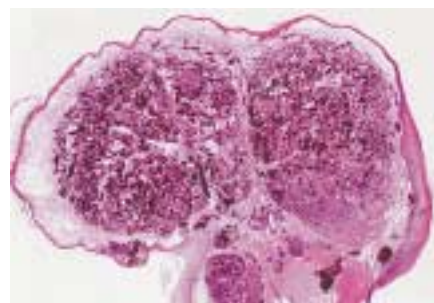
- 1 Bhaskar SN, Jacoway JR. Pyogenic granuloma: clinical features, incidence, histology, and result of treatment. *J Oral Surg* 1966; 24: 391–398
- 2 Patrice SJ, Wiss K, Mulliken JB. Pyogenic granuloma (lobular capillary hemangioma): a clinicopathologic study of 178 cases. *Pediatr Dermatol* 1991; 8: 267–276
- 3 Hirakawa K, Aoyagi K, Yao T et al. A case of pyogenic granuloma in the duodenum: successful treatment by endoscopic snare polypectomy. *Gastrointest Endosc* 1998; 47: 538–540
- 4 Chen TC, Lien JM, Ng KF et al. Multiple pyogenic granuloma in sigmoid colon. *Gastrointest Endosc* 1999; 49: 257–259
- 5 Lin KJ, Yen TC, Tzen KY. Multiple pyogenic granuloma demonstrated by SPECT using <sup>99m</sup>Tcm-labelled red blood cells. *Br J Radiol* 1999; 72: 397–399



**Figure 1** The barium meal examination shows a round radiolucent area, measuring 8 mm in diameter, in the middle third of the esophagus.



**Figure 2** Endoscopy reveals a sessile, protruding lesion. The base is brownish-red and the top is whitish in color.



**Figure 3** A low-powered view shows that the lobulated tumor is located in the proper mucosal layer (hematoxylin–eosin, original magnification  $\times 4$ ).

## Corresponding Author

**N. Okada, M.D.**

Dept. of Medicine and Clinical Science  
Graduate School of Medical Sciences  
Kyushu University  
Maidashi 3-1-1, Higashi-ku  
Fukuoka 812-8582, Japan  
Fax: +81-92-642-5273  
E-Mail: sakonao@genmedpr.med.kyushu-u.ac.jp