

The large working channel of a new generation of duodenoscopes permits side-by-side double guide wire placements, which can facilitate both cannulation and drainage during pancreaticobiliary procedures [1]. The use of two guide wires in one duct can make therapeutic endoscopy easier during drainage procedures. It is employed by many endoscopists for bilateral drainage of strictures in the biliary duct [1,2]. A similar method for stent insertion, employing a double guide wire, can also be applied during cystoenterostomies [3].

The “double guide wire technique” can also facilitate cannulation of the biliary tract in difficult endoscopic retrograde cholangiopancreatography (ERCP) procedures. If selective cannulation of the common bile duct has not been successful, we pass a 0.035-inch Teflon guide wire (Wilson-Cook, Winston-Salem, North Carolina, USA) distally into the main pancreatic duct, to prevent repeated overfilling and pancreatitis. It is advisable to suck the contrast medium out of the pancreas beforehand. A standard sphincterotome is

then passed into the working channel of the endoscope (JFT10, Olympus, Hamburg, Germany). The tip of the papillotome is positioned against the first wire placed in the pancreatic duct, and its curve is altered; this usually makes it easy to introduce a second guide wire into the common bile duct (Figure 1). If not, then the guide wire placed in the pancreatic duct is pushed downwards; this may straighten the distorted prepapillary part of the common bile duct and facilitate guidance to the choledochus.

This method was first described by Dumenceau et al. [4], but was used in only one patient, who had a Billroth I anastomosis. A similar idea was reported by Slivka et al. [5], who used temporary short pancreatic polyethylene stents to facilitate access into the bile duct.

We have routinely used this double guide wire technique in all our difficult cases for more than 3 years, because we believe that unwanted cannulation and repeated filling of the pancreatic duct run the risk of provoking pancreatitis. During recent months in our department, we performed 75 ERCPs followed by endoscopic sphincterotomy for biliary conditions. We used the double guide wire technique for can-

nulation in 24 difficult cases (32%). (Patients who underwent precutting are excluded.) All the interventions were carried out by two endoscopists. The complication rate did not differ significantly between the group of patients in whom cannulation was easy and the group in whom the double guide wire was used (mild pancreatitis 7.8% vs. 8.3%; slight bleeding 5.8% vs. 4.1%). A similar method can be applied if cannulation of the pancreatic duct is attempted but only biliary access is achieved initially. It is feasible to insert separate guide wires into the two ducts for complex endoscopic treatment of chronic pancreatitis. Pancreatic sphincterotomy using a needle-knife papillotome is then safer if it is applied between the two guide wires placed in the pancreatic and biliary ducts (Figure 2).

All of the abovementioned techniques are aimed at assisting the endoscopist, shortening the duration of procedures, and decreasing the risk of complications. Another advantage is safety even during the clinician's learning curve for the procedures [1], when repeated cannulation and overfilling of the pancreatic duct is a real danger, and correction of failed attempts is difficult because of papillary damage.

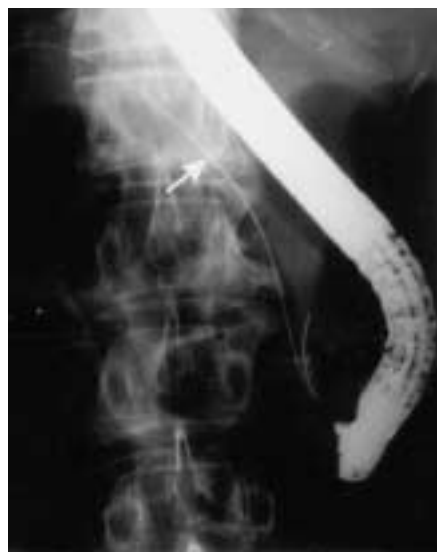

Figure 1 One guide wire has been passed into the pancreatic duct and another is being moved in the direction of the bile duct through the papillotome inserted into the ampulla.

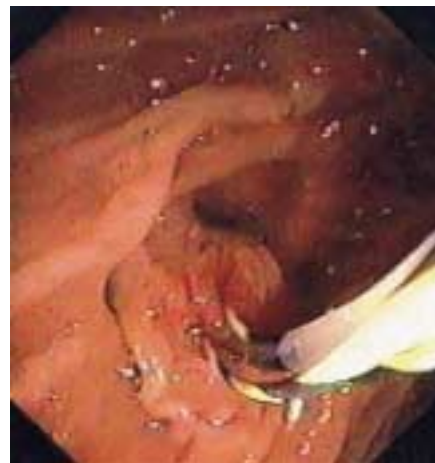


Figure 2 Septotomy using a needle-knife papillotome, between separate guide-wires inserted into the pancreatic and biliary ducts.

Acknowledgement

Presented at the IAP 2000 meeting, Chicago: *Pancreas* 2000; 21: 4, 439 (A).

T. Gyökeres¹, J. Duhl², M. Varsányi¹, R. Schwab¹, M. Burai¹, Á. Pap¹

¹ Department of Gastroenterology, MAV Hospital, Budapest, Hungary

² Raritan Bay Medical Center and RWJ Medical School, Perth Amboy, New Jersey, USA

References

- ¹ Bhasin DK, Sharma BC, Gupta S et al. Double guide wire placement in common bile duct: a technique for teaching biliary endoprosthesis placement (letter). *Gastrointest Endosc* 1998; 48: 453–454
- ² Gyökeres T, Pap Á. Two Teflon stents in non-hilar biliary malignancies. *Orv Hetil* 2000; 141: 77–82
- ³ Gyökeres T, Topa L, Marton I, Pap Á. Endoscopic cystogastrostomy during pregnancy. *Gastrointest Endosc* 2001; 53: 516–518
- ⁴ Dumenceau JM, Devière J, Cremer M. A new method of achieving deep cannulation of the common bile duct during endoscopic retrograde cholangiopancreatography. *Endoscopy* 1998; 30: S80
- ⁵ Slivka A. A new technique to assist in bile duct cannulation (letter). *Gastrointest Endosc* 1996; 44: 636

Corresponding Author

T. Gyökeres, M.D.

Dept. of Gastroenterology

MAV Hospital

Podmaniczky u. 111

1062 Budapest

Hungary

Fax: +361-475-2669

E-mail: gyokeres@elender.hu