

The rendezvous technique is a useful combined radiological and endoscopic procedure to facilitate common bile duct (CBD) access. A guide wire is placed through the skin into the biliary tract and advanced into the duodenum and once the wire exits the papilla the wire is grasped with a Dormia basket, forceps, or a snare. Occasionally it is difficult to grasp hydrophilic wires with forceps or a snare due to their slippery surface. Also, during the process of grabbing and pulling guide wires through the biopsy channel of the duodenoscope with any of these devices (forceps, snare, or basket) damage, kinking or breakage of the wire can occur.

We describe a simple and useful modification of the rendezvous technique (Figure 1). Once the wire exits the papilla and is inside the duodenal lumen, a catheter or a sphincterotome is placed in front of the tip of the wire (Figure 2). The tip of the wire is then pushed inside the lumen of the catheter. Following this maneuver, the catheter is advanced over the wire

into the CBD. The remaining steps follow the usual rendezvous technique: while the catheter is in the distal CBD, the wire is pushed completely through the tract and then pulled through the catheter out of the endoscope. Once the wire is out of the scope, the soft or floppy end of the wire is placed back into the catheter and advanced into the biliary tree. In any rendezvous technique it is imperative to pull the wire completely out of the endoscope and reinsert it with its floppy end through the catheter, because if the proximal hard end of the wire is pushed into the biliary tree, perforation can occur. A partial solution to this problem would be to design a wire with proximal and distal floppy (hydrophilic) tips, which could make both the traditional and the modified rendezvous techniques easier.

We have successfully employed the modified rendezvous technique on five occasions. Three patients with liver transplantation had developed bile leak immediately after removal of the T-tube. Deep cannulation of the CBD during endoscopic retrograde cholangiopancreatography (ERCP) proved impossible, therefore a wire was placed through the biliocutaneous tract and fluoroscopically guided into the CBD and duodenum. Two other patients had undergone percutaneous

transhepatic placement of a drain for obstructive jaundice, after ERCP had failed. At a second ERCP, the modified rendezvous technique was used to deeply cannulate the CBD and to place stents across the biliary strictures. We conclude that the modified rendezvous technique is a useful and effective maneuver to achieve deep CBD cannulation.

K. E. Mönkemüller, J. D. Linder, L. C. Fry
VA Medical Center,
Division of Gastroenterology,
University of Alabama, Birmingham,
Alabama, USA

References

- 1 Maetani I, Hoshi H, Ohashi S et al. Cholangioscopic extraction of intrahepatic stones associated with biliary strictures using a rendezvous technique. *Endoscopy* 1993; 25: 303–306

Corresponding Author

K. E. Mönkemüller, M.D.
Division of Gastroenterology
University of Alabama
633 ZRB UAB Station
Birmingham, AL 35294
USA
Fax: +1-205-934-8493
E-mail: klaus1@uab.edu

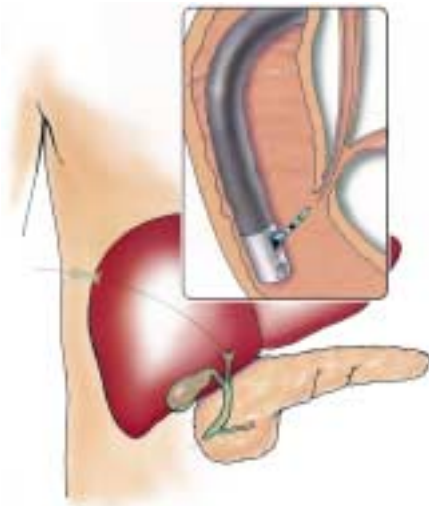


Figure 1 The wire is advanced under fluoroscopic guidance through the skin or external biliocutaneous drain into the biliary tree. The wire is then advanced into the distal common bile duct (CBD) and pushed towards the papilla. Once the wire exits the papilla and is inside the duodenal lumen, a catheter or a sphincterotome is placed in front of the tip of the wire. The tip of the wire is then pushed inside the lumen of the catheter.

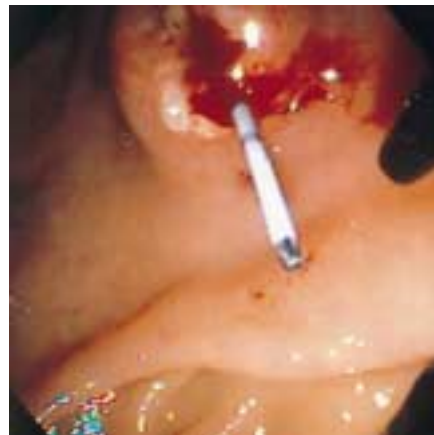

Figure 2 Endoscopic visualization of a guide wire which has been placed through a T-tube, advanced through the CBD and is now exiting the papilla of Vater. A catheter will be advanced over the wire into the CBD.