

Individuals who ingest coins are usually simply observed, because the majority of coins which pass into the stomach move unimpeded through the gastrointestinal tract [1,2]. It is rare for ingested coins which pass through the pylorus to lodge in the small bowel, and even rarer for this not to present acutely but rather several years later. A 52-year-old man presented with a 9-month history of intermittent epigastric pain and profuse vomiting, each bout lasting a few hours. These episodes settled spontaneously, and he was entirely well in between. The patient had accidentally swallowed a coin over 3 years previously which had not obviously passed. Physical examination showed normal findings. An abdominal plain film showed a coin-shaped metallic density in his mid-abdomen. Gastroscopy revealed an Irish 50 pence coin in the duodenal cap (Figure 1). The coin was firmly adherent to the duodenal mucosa on one of its edges, but appeared to swing about this axis and intermittently occlude the pyloric opening. There was a duodenal diverticulum just proximal to the site of the coin. The coin was dislodged with a snare and

retrieved using a basket (Figure 2). At follow up 3 months later, the patient remained well with no further gastrointestinal symptoms.

There are very few reports of patients ingesting foreign objects and presenting with subacute obstruction at a later date. One describes a patient in a persistent vegetative state who presented with obstruction 6 months after ingestion of the pulp of his feeding catheter [3], and another describes subacute small bowel obstruction in a patient with entrapped coins in an intraluminal duodenal diverticulum 20 years after ingestion [4]. Although rare, duodenal anomalies should be considered in the differential diagnosis of foreign bodies lodged in the duodenum [4]. Our patient had a duodenal diverticulum. Deformity around diverticula may promote lodgement of foreign objects.

**M. F. Byrne, G. McVey, K. Abdulla, S. Patchett**

Department of Gastroenterology,  
Beaumont Hospital, Dublin, Ireland

## References

- <sup>1</sup> Selivanov V, Sheldon GF, Cello JP et al. Management of foreign body ingestion. *Ann Surg* 1984; 199: 187–191
- <sup>2</sup> Stack LB, Munter DW. Foreign bodies in the gastrointestinal tract. *Emerg Med Clin N Am* 1996; 14: 493–521
- <sup>3</sup> Tibbitts GM, Sorrell RJ. Duodenal obstruction from a gastric feeding tube. *N Engl J Med* 1999; 340: 970–971
- <sup>4</sup> Adams DB. Endoscopic removal of entrapped coins from an intraluminal duodenal diverticulum 20 years after ingestion. *Gastrointest Endosc* 1986; 32: 415–416

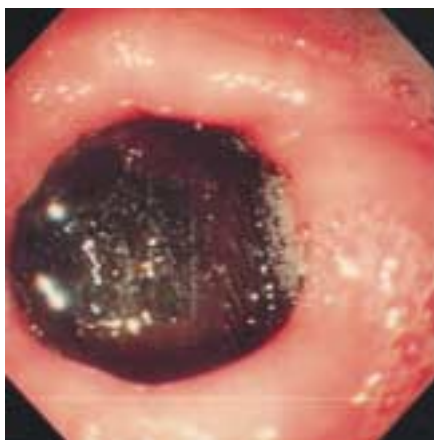## Corresponding Author

**M. F. Byrne, M.D.**


Duke University Medical Center  
Box 3189, Durham, NC 27710  
USA

Fax: +1-919-684-4695

E-mail: byrne006@mc.duke.edu



**Figure 1** Endoscopic image of coin acting like a “ball-valve” at the pylorus. The coin was adherent to the mucosa in the duodenal cap by one of its edges, about which it appeared to swing



**Figure 2** The retrieved Irish 50 pence coin was oxidized, and the date was obliterated. It measured about 28 mm in maximum diameter