

Portal Hypertensive Gastropathy: Treatment with Corticosteroids

UCTN

Portal hypertensive gastropathy (PHG) has been recognised as an increasingly important source of bleeding in cirrhotic patients in whom an esophageal source of hemorrhage has been excluded [1]. Results of treatment of this condition have been disappointing [2,3]. Although some authors consider that PHG and gastric antral vascular ectasia (GAVE) represent two separate entities, a large overlap exists [4]. The use of corticosteroids has been reported to be successful in patients with GAVE [5]. On this basis, our group used oral corticosteroid therapy to treat a patient with severe PHG, who had shown no improvement from treatment with nonselective beta-blockers.

A 64-year-old man with alcoholic cirrhosis was admitted for the fifth time in a 5-month period for severe anemia (Hgb, 6.1 g/dl; serum iron, 10 µg/dl), without overt gastrointestinal bleeding. An upper gastrointestinal endoscopy showed grade II esophageal varices and severe PHG of the whole stomach, which was bleeding spontaneously (Figure 1). Antrum biopsies showed vascular ectasia without inflammatory cells and no fibromuscular hyperplasia of the lamina propria. The patient was given 2 units of packed blood cells, and treatment with oral prednisolone 20 mg/day and with oral iron was started. The patient was discharged with a regimen of 20 mg of prednisolone on al-

ternate days. At 2 months later the hemoglobin level had risen to 10.8 g/dl, and 4 months later an upper gastrointestinal endoscopic examination showed improvement in the PHG (Figure 2). The prednisolone dose was reduced to 15 mg on alternate days and oral iron was stopped. After 15 months, there was no evidence of gastrointestinal bleeding or anemia and the prednisolone was stopped. A third upper gastrointestinal examination showed marked improvement in the PHG (Figure 3). Over a 3-year follow-up period there was no recurrence of anemia and the cirrhosis remained stable.

This report seems to show the efficacy of corticosteroids in the treatment of this group of patients; however the use of this medication needs to be further evaluated in controlled studies.

**M. I. Cremers, A. P. Oliveira,
A. L. Alves, J. Freitas**

Department of Gastroenterology,
Hospital de S. Bernardo, Setúbal, Portugal

References

- ¹ Smart HL, Triger DR. Clinical features, pathophysiology and relevance of portal hypertensive gastropathy. *Endoscopy* 1991; 23: 224–228
- ² Hosking SW, Kennedy HJ, Seddon I et al. The role of propranolol in congestive

gastropathy of portal hypertension. *Hepatology* 1987; 7: 437–441

³ Sarfeh IJ, Juler GL, Stemmer EA et al. Results of surgical management of hemorrhagic gastritis in patients with gastroesophageal varices. *Surg Gynecol Obstet* 1982; 155: 167–170

⁴ Payen J-L, Calès P, Voigt J-J et al. Severe portal hypertensive gastropathy and antral vascular ectasia are distinct entities in patients with cirrhosis. *Gastroenterology* 1995; 108: 139–144

⁵ Kruger R, Ryan ME, Dickson KB, Nunez JF. Diffuse vascular ectasia of the gastric antrum. *Am J Gastroenterol* 1987; 82: 421–426

Corresponding Author

M. I. Cremers, M.D.

Dept. of Gastroenterology
Hospital de S. Bernardo-Setúbal
2910 Setúbal
Portugal

Fax: + 351-265-549070

E-mail: cremers_tavares@hotmail.com

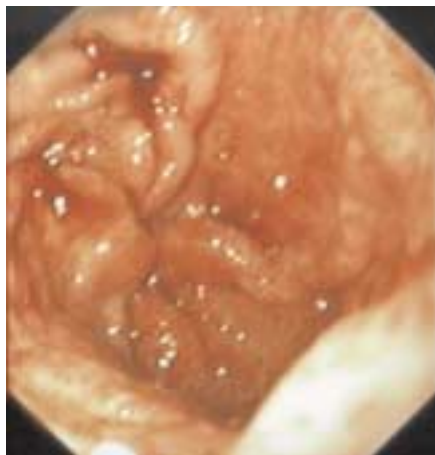


Figure 1 Severe portal hypertensive gastropathy before treatment with corticosteroids

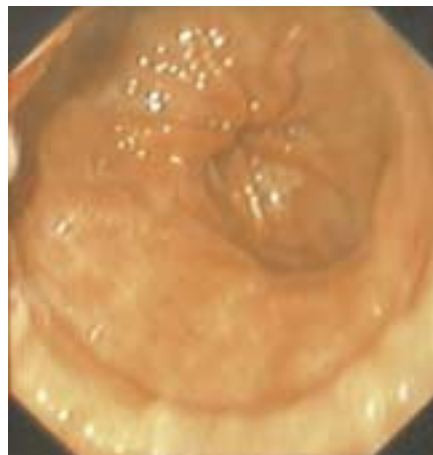


Figure 2 Improvement in severe portal hypertensive gastropathy after 4 months of corticosteroid treatment

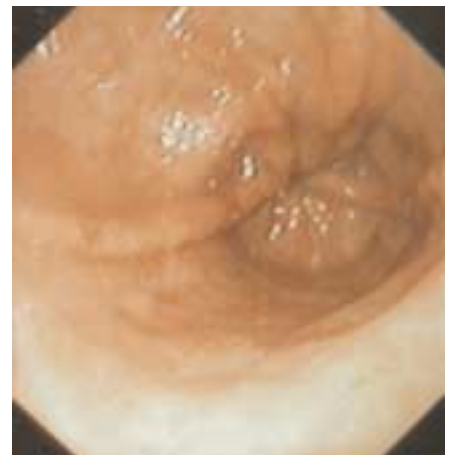


Figure 3 Marked improvement in severe portal hypertensive gastropathy after 15 months of corticosteroid treatment