








# Application of Combined SCIP and Free Fibula Flaps for Reconstruction of a Massive Composite Oromandibular Defect: A Pioneering Approach

K. Pavan Venkateswar<sup>1</sup> Anchit Kumar<sup>1</sup> Kripa Shankar Mishra<sup>1</sup> Rajan Arora<sup>1</sup> Nikhil Prasad<sup>1</sup>  
Samarth Gupta<sup>1</sup> A. K. Dewan<sup>2</sup> Vikas Arora<sup>2</sup> Vishal Yadav<sup>2</sup>

<sup>1</sup> Department of Plastic Surgery, Rajiv Gandhi Cancer Institute and Research Centre, New Delhi, India

<sup>2</sup> Department of Surgical Oncology, Rajiv Gandhi Cancer Institute and Research Centre, New Delhi, India

**Address for correspondence** Dr K. Pavan Venkateswar, Mch Plastic and Reconstructive Surgery, Department of Plastic Surgery, Rajiv Gandhi Cancer Institute and Research Centre, Rohini, Sector 5, New Delhi 110085, India (e-mail: drpavanven@gmail.com).

Indian J Plast Surg

## Abstract

Resection of advanced oral malignancies often leads to extensive composite tissue defects, which may involve skin, oral mucosa, mandible, and a significant amount of soft tissue. While the free fibula flap remains the primary choice of reconstruction, there are instances where a second flap is necessary for coverage. In such cases, the anterolateral thigh (ALT) flap is commonly employed as a second free flap. We recently utilized a superficial circumflex iliac artery perforator (SCIP) flap in combination with the free fibula flap to reconstruct a large oromandibular defect. This report emphasizes the significance of the SCIP flap and the benefits of combining free flaps, supported by relevant literature.

## Keywords

- ▶ oral malignancy
- ▶ SCIP flap
- ▶ double free flap
- ▶ free fibula flap
- ▶ composite defects

## Introduction

Reconstruction of defects involving multiple subunits of the oral cavity and the face often poses a great challenge to the reconstructive surgeon. The commonest choice for composite defects of the head and neck is the free fibula osteocutaneous flap. However, limitations exist in terms of available soft tissue, skin, and orientation of the skin paddle relative to the bone. Previous studies have explored the indications, efficacy, and functional outcomes of simultaneous double free flaps in cases of complex, large tissue defects.<sup>1</sup> Popular combinations include pairing the free fibula flap with either radial forearm free flap or an anterolateral thigh (ALT) flap.<sup>2</sup> In this case report, we highlight the possibility and advantages of using the superficial circumflex iliac artery perforator (SCIP) flap in combination with free fibula flap for reconstructing a major composite defect

of the lower face involving the mandible, skin, and oral mucosa.<sup>3,4</sup>

## Case Report

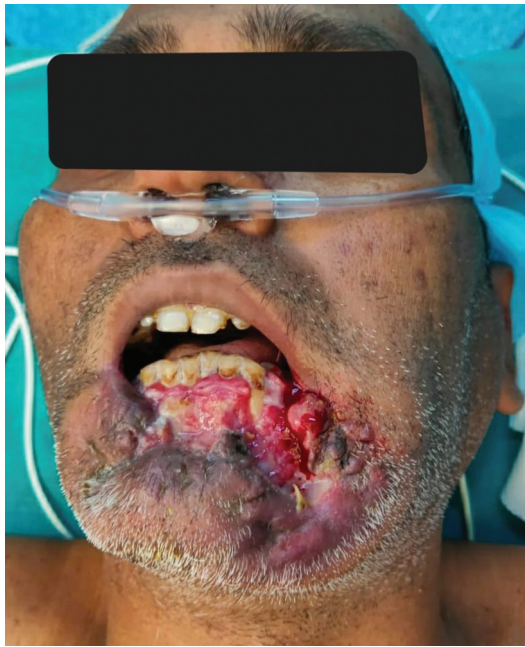A 42-year-old man had a well-differentiated squamous cell carcinoma of his lower lip. At the time of diagnosis, the tumor was classified as stage T4aN2c. Following neoadjuvant chemotherapy, the tumor was downstaged to ycT4aN0 (▶ **Fig. 1**). It extended from the lip, skin of the chin and the lower face and eroded into the mandible and the floor of the mouth. He subsequently underwent wide local excision and bilateral neck dissection by the oncosurgery team. It resulted in loss of his lower lip, central arch of the mandible, skin, and soft tissue of the mentum and the upper neck (▶ **Fig. 2**).

We planned to reconstruct the central arch and the intraoral lining with a free fibula flap. The outer defect measured

DOI <https://doi.org/10.1055/s-0044-1791810>.  
ISSN 0970-0358.

© 2024. Association of Plastic Surgeons of India. All rights reserved. This is an open access article published by Thieme under the terms of the Creative Commons Attribution-NonDerivative-NonCommercial-License, permitting copying and reproduction so long as the original work is given appropriate credit. Contents may not be used for commercial purposes, or adapted, remixed, transformed or built upon. (<https://creativecommons.org/licenses/by-nc-nd/4.0/>)

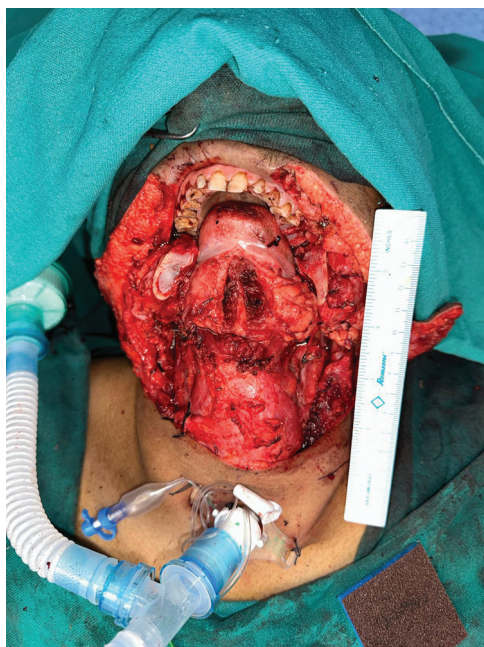Thieme Medical and Scientific Publishers Pvt. Ltd., A-12, 2nd Floor, Sector 2, Noida-201301 UP, India



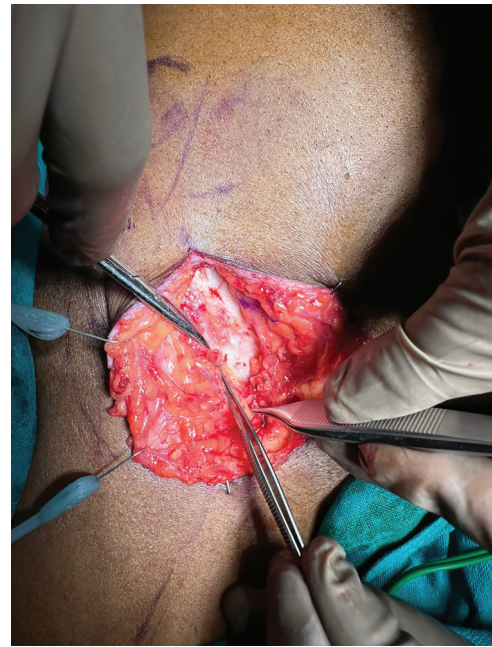**Fig. 1** Squamous cell carcinoma of the lower lip involving the floor of the mouth, mandible, and outer skin.

13 × 15 cm. Considering an ALT flap for such a large defect, we realized that the donor site would require a skin graft. Additionally, with the dominant perforator being proximal on preoperative Doppler study, it was deemed that a thick flap would give an unsightly reconstruction. Therefore, we opted for the SCIP flap, which in our opinion provides good contour over the face and a hidden linear scar at the donor site.

In a two-team approach, we harvested the free fibula flap from the left leg and the SCIP flap from the right groin. A line



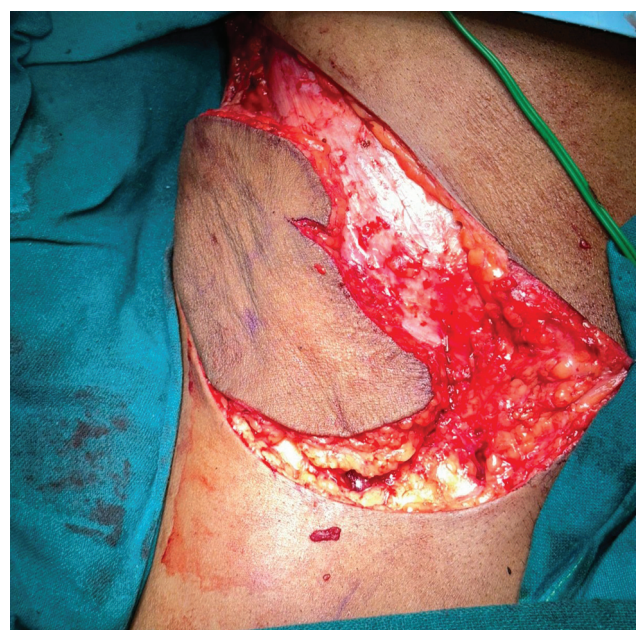**Fig. 2** Posttumor resection, the external skin defect is 13 × 15 cm and the central arch defect measured 11 cm. Mandible resection was done to the level of the low ramus on the left side and to the angle on the right side.



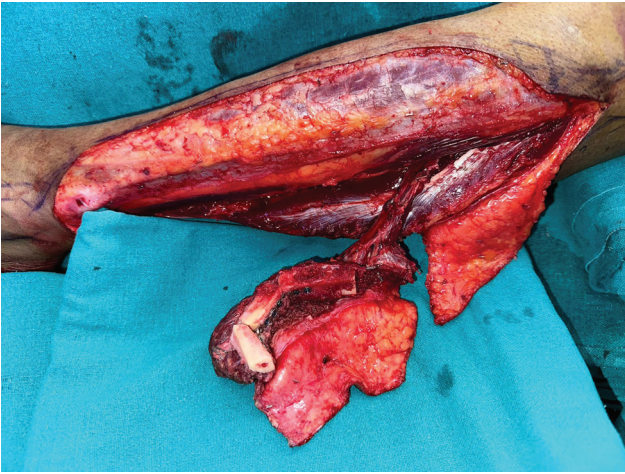
**Fig. 3** The superficial circumflex iliac artery perforator (SCIP) flap is elevated in the suprafascial plane above the deep fascia to avoid damage to the lymphatics.

was drawn from the pubic tubercle to the anterosuperior iliac spine representing the topographic pathway of the perforator and guiding flap design based on available recipient vessels. Preoperatively, we marked the dominant perforators in the groin area using a handheld Doppler.

Flap elevation began with an incision along the inferior border until the deep fascia. We continued dissection in the suprafascial plane until the perforators were visualized (►Figs. 3 and 4). The perforators from both the superficial and deep branches were identified and traced back to the



**Fig. 4** A 12 × 18 cm superficial circumflex iliac artery perforator (SCIP) flap is harvested from the right groin.

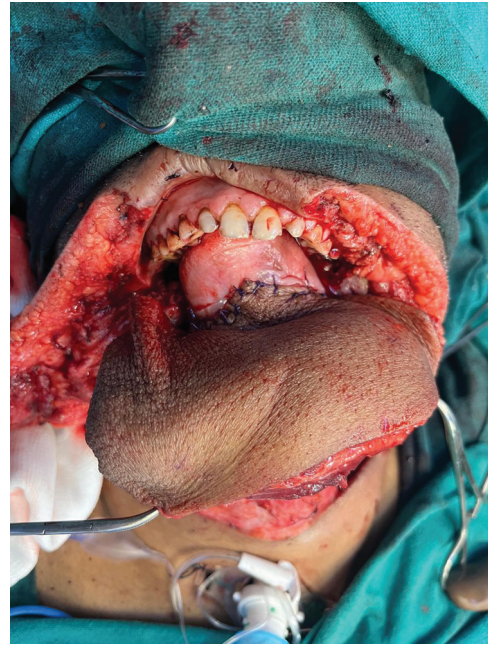

**Fig. 5** Osteotomy and plating for reconstruction of central arch is done before dividing the pedicle.

source vessel into the deep fascia. This ensured an adequate pedicle length of 6 cm and vessel diameter of 1.5 mm. We included a subcutaneous vein for additional drainage, which is usually found to have a better caliber for anastomosis.

The free fibula flap was harvested from the left leg. Osteotomy and plating of the fibula was performed before dividing the flap (→**Fig. 5**). Considering the potential need for future radiotherapy, we utilized 1.25-mm low-profile miniplates to secure the fibula segments and 1.5-mm miniplates to attach the fibula to the native mandible. The skin paddle of the fibula flap was then used to create the anterior floor of the mouth, intraoral lining, and inner aspect of the lower lip (→**Fig. 6**).

Given the bilateral neck dissection and the large defect, we had several options for recipient vessels. The SCIP flap was anastomosed end to end with the left superior thyroid artery and the vein was anastomosed to the superior thyroid vein. The free fibula flap was anastomosed to the left facial artery, and the venae comitantes of the peroneal artery were anastomosed to the left common facial vein.

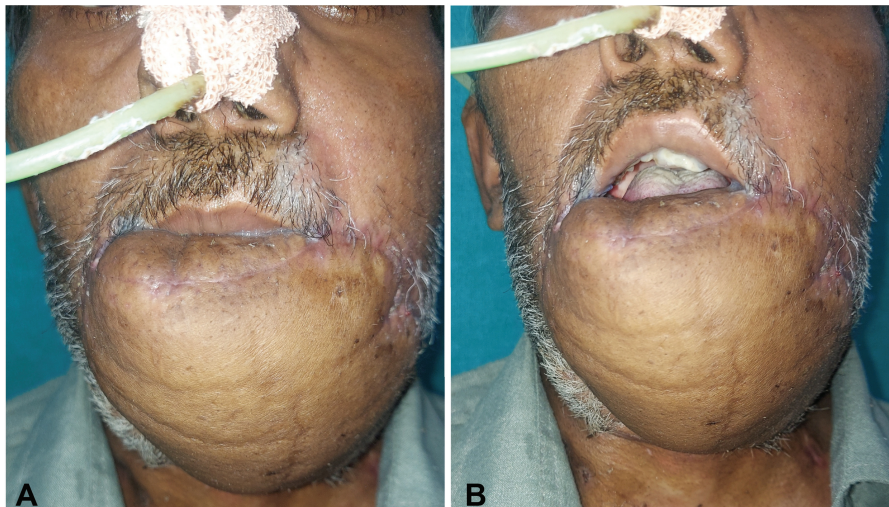


**Fig. 6** The fibula skin paddle was used for reconstruction of the floor of the mouth.

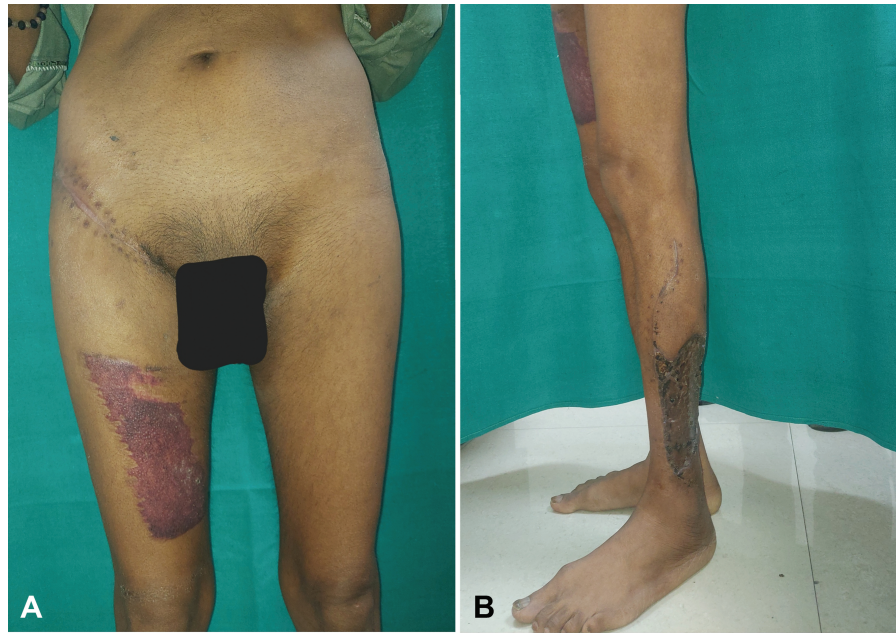Postsurgery, the patient recovered without any complications and is currently undergoing radiotherapy. Notably, there is a good skin color match, and the patient exhibits excellent oral continence, swallowing, and speech functions (→**Fig. 7**). Additionally, both the donor areas healed well (→**Fig. 8**).

## Discussion

When dealing with composite defects in the head and neck, the free fibula flap is considered the gold standard. However, the length of the perforator from the peroneal artery is limited, sometimes requiring the use of a second flap.<sup>5</sup> While flaps from the thigh and thoracodorsal regions can be bulky



**Fig. 7** (A, B) Four weeks after surgery, the patient developed good oral continence, and had adequate mouth opening.



**Fig. 8** (A, B) Both the donor sites healed well without complications. The groin scar is inconspicuous and cosmetically acceptable.

and have thick skin, the SCIP flap offers a thin skin paddle, making it an ideal choice to meet specific requirements.

The perforators from the deep branch penetrates the deep fascia laterally, while those from the superficial branch penetrate more medially. Building on this understanding, Koshima et al harvested the flap above the deep fascia, enhancing skin pliability and reducing flap thickness.<sup>6</sup> Choi et al further refined this approach by elevating the flap above the deep fat layer within the superficial fascial plane.<sup>7</sup> This plane is located between larger deep fat and smaller superficial fat lobules. In our case, as there is loss of submandibular soft tissue as well, we harvested the flap in a plane above the deep fascia.

Yoshimatsu et al introduced the concept of piggyback anastomosis, connecting the SCIP flap to the peroneal artery pedicle of the free fibula flap.<sup>4</sup> This technique proves valuable when a second recipient vessel is unavailable. However, it does carry a risk: if thrombosis occurs, both flaps could be compromised. In our case, we opted for separate anastomoses to different recipient vessels to mitigate this risk.

Due to its short pedicle length, most of the literature highlights the application of the SCIP flap in defects where the recipient vessels are superficially located.<sup>6</sup> However in head and neck cases, the recipient artery may be distant from the defect, occasionally requiring a vascular graft. The varying vessel diameters can make the anastomosis challenging. Despite these drawbacks, the versatile use of the SCIP flap remains unaffected.<sup>7</sup>

The SCIP flap is gaining popularity in head and neck coverage due to its thin and pliable characteristics. Its dermal quality makes it even more flexible than the thin ALT flap, making it an excellent choice for restoring facial contour. The SCIP flap drapes supplely over the facial muscles, preserving natural expressions. Additionally, its texture and color match well with facial skin compared with

other flaps.<sup>7</sup> Importantly, there is no loss of function or sensation because flap elevation does not require muscle or nerve dissection. The donor sites are typically closed and concealed.

## Conclusion

While no documented reports in the literature currently describe the combination of the SCIP flap with the free fibula flap for head and neck reconstruction, this case report sheds light on the potential of this combination to yield favorable functional and aesthetic outcomes. Given the mentioned advantages, it is advisable to consider using the SCIP flap more frequently for this purpose.

## Funding

None.

## Conflict of Interest

None declared.

## References

- Balasubramanian D, Thankappan K, Kuriakose MA, et al. Reconstructive indications of simultaneous double free flaps in the head and neck: a case series and literature review. *Microsurgery* 2012; 32(06):423–430
- Wei FC, Celik N, Chen HC, Cheng MH, Huang WC. Combined anterolateral thigh flap and vascularized fibula osteoseptocutaneous flap in reconstruction of extensive composite mandibular defects. *Plast Reconstr Surg* 2002;109(01):45–52
- Goh TLH, Park SW, Cho JY, Choi JW, Hong JP. The search for the ideal thin skin flap: superficial circumflex iliac artery perforator flap: a review of 210 cases. *Plast Reconstr Surg* 2015;135(02): 592–601
- Yoshimatsu H, Nakatsuka K, Karakawa R, Fuse Y, Yano T. The piggyback superficial circumflex iliac perforator flap for complex

free flap reconstructions. *Plast Reconstr Surg Glob Open* 2024;12(06):e5899

5 Tsuge I, Yamanaka H, Katsube M, Sowa Y, Sakamoto M, Morimoto N. Double-flap mandibular reconstruction around the condylar head using fibula and anterolateral thigh flaps. *Plast Reconstr Surg Glob Open* 2022;10(11):e4607

6 Koshima I, Nanba Y, Tsutsui T, et al. Superficial circumflex iliac artery perforator flap for reconstruction of limb defects. *Plast Reconstr Surg* 2004;113(01):233–240

7 Choi DH, Goh T, Cho JY, Hong JP. Thin superficial circumflex iliac artery perforator flap and supermicrosurgery technique for face reconstruction. *J Craniofac Surg* 2014;25(06):2130–2133