



Chronic Noninfectious Osteomyelitis: A Review of Imaging Findings

Stuti Chandola¹  Narendra Bagri² Savvas Andronikou³ A.V. Ramanan⁴ Manisha Jana¹

¹Department of Radiodiagnosis and Interventional Radiology, All India Institute of Medical Sciences, New Delhi, India

²Division of Paediatric Rheumatology, Department of Paediatrics, All India Institute of Medical Sciences, New Delhi, India

³Department of Radiology, Perelman School of Medicine at University of Pennsylvania, Philadelphia, Pennsylvania, United States

⁴Department of Paediatric Rheumatology, Bristol Royal Hospital for Children & Translational Health Sciences, University of Bristol, Bristol, United Kingdom

Address for correspondence Manisha Jana, MD, DNB, FRCR, Department of Radiodiagnosis and Interventional Radiology, AIIMS, New Delhi, India (e-mail: manishajana@gmail.com).

Indian J Radiol Imaging

Abstract

Chronic noninfectious osteomyelitis or chronic nonbacterial osteomyelitis (CNO), also known as chronic recurrent multifocal osteomyelitis, is an autoinflammatory bone disorder primarily affecting the pediatric age group. Currently, it is diagnosed on the basis of clinical, laboratory, and imaging features. Imaging plays a crucial role in the diagnosis and follow-up of CNO with whole body magnetic resonance imaging (WBMRI) being the main modality. Radiographs assist in exclusion of common differential diagnoses like infections and malignancy. WBMRI aids in disease detection and exclusion of differential diagnoses, identifies additional lesions, and has a role in ascertaining the pattern of bony involvement which helps with prognostication and grading. Recent recognition of specific morphological and distribution patterns on WBMRI is increasingly allowing an upfront diagnosis of this entity to be made on imaging alone. It is also helpful for assessment of response to therapy during follow-up. This review aims to summarize the role of imaging in the evaluation of CNO, with special emphasis on WBMRI in its assessment.

Keywords

- ▶ chronic nonbacterial osteomyelitis
- ▶ chronic recurrent multifocal osteomyelitis
- ▶ autoinflammatory
- ▶ whole body MRI
- ▶ nonbacterial osteitis
- ▶ radiograph

An 11-year-old boy presented with a history of swelling over the medial aspect of the left clavicle for 2 years. A chest radiograph was performed in view of the symptoms (▶ **Fig. 1**).

1. List the key findings
2. What are the possibilities?
3. What should be done next?

Introduction

Chronic nonbacterial osteomyelitis (CNO) or chronic recurrent multifocal osteomyelitis is a chronic autoinflammatory bone

disorder being increasingly recognized in the pediatric age group.^{1–3} This polymorphic disease lacks bacterial involvement and involves distinct sites within the skeletal system.⁴ The exact etiopathogenesis is unknown; however, it is thought to belong to the group of autoinflammatory bone disorders such as synovitis, acne, pustulosis, hyperostosis, and osteitis (SAPHO syndrome), Majeed syndrome, deficiency of interleukin-1 receptor antagonist (DIRA), inflammatory bowel disease, and pyogenic arthritis, pyoderma gangrenosum, and acne syndrome (PAPA). Among these, SAPHO syndrome in particular has been considered as a variant of CNO in adults.^{3–6}

DOI <https://doi.org/10.1055/s-0044-1790238>.
ISSN 0971-3026.

© 2024. Indian Radiological Association. All rights reserved.
This is an open access article published by Thieme under the terms of the Creative Commons Attribution-NonDerivative-NonCommercial-License, permitting copying and reproduction so long as the original work is given appropriate credit. Contents may not be used for commercial purposes, or adapted, remixed, transformed or built upon. (<https://creativecommons.org/licenses/by-nc-nd/4.0/>)
Thieme Medical and Scientific Publishers Pvt. Ltd., A-12, 2nd Floor, Sector 2, Noida-201301 UP, India

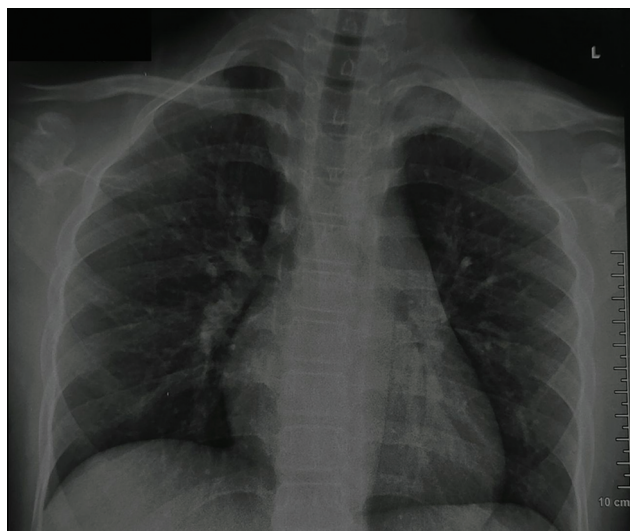

Fig. 1 Introductory radiograph. Frontal chest radiograph demonstrates exuberant hyperostosis and solid periosteal reaction with the medial and middle thirds of the left clavicle. Right clavicle and bony rib cage appear normal.

CNO typically affects children and adolescents, with the diagnosis peaking in between 7 and 12 years and the mean age at diagnosis being 11 years.^{4,7} Females are more frequently affected than males (2 to 4:1).⁷⁻⁹ The disease symptoms are often nonspecific and show variability, ranging from minimal pain and swelling with single bone affection to debilitating recurrent multifocal osteitis.^{7,8} Two major clinical patterns are recognized: multifocal involvement, which affects the appendicular system with typical involvement of long bone metaphysis, and the unifocal pattern involving flat bones like the clavicle and spine.^{1,4} Inflammatory markers like C-reactive protein (CRP) and erythrocyte sedimentation rate (ESR) may be normal or show mild

elevation.^{3,8,9} They additionally possess as low specificity for diagnosis as they are elevated in a multitude of conditions like infection and juvenile idiopathic arthritis (JIA). Associations with psoriasis and palmoplantar pustulosis have been observed in 2 to 17% and 3 to 20% of patients, respectively.

Diagnostic criteria: The diagnosis of CNO at present is based on a composite evaluation of clinical, laboratory, and imaging features.^{4,9-11} Biopsy is not specific and is reserved for exclusion of differential diagnoses such as infection and malignancy.^{10,11} Frequent misdiagnosis, most notably as bacterial osteomyelitis, often leads to initiation of antimicrobial therapy. The universally accepted diagnostic criteria of CNO are the Jansson and Bristol criteria which are tabulated in **Table 1**.¹²⁻¹⁴ The Bristol criteria are used more frequently worldwide and require presence of both typical clinical and radiological findings along with either of the following for a diagnosis of CNO: (1) multifocal lesions or isolated clavicular involvement with CRP < 30 g/L or (2) if CRP > 30 g/L, histological evidence of sterile inflammation.¹⁴

The new American College of Rheumatology (ACR)/European Alliance of Associations for Rheumatology classification criteria for diagnosis of CNO were proposed in 2022 and presented as a conference paper during ACR convergence in 2023.¹⁵ This system consists of a score allocation ranging from 0 to 18 (variable for different domains) on the basis of evaluation of 10 domains, namely, specific bone involved, pattern of distribution, response to antibiotics, biopsy results, age, coexisting inflammatory bowel disease and axial arthritis, hemoglobin, fever, ESR, and CRP levels. A score of > 55 is indicative of CNO.¹⁵

Imaging plays a crucial role in the diagnosis and follow-up of CNO and whole body magnetic resonance imaging (WBMRI) has emerged as the main modality for this assessment. WBMRI finds its importance not only in the diagnosis of CNO but also in ascertaining the disease severity and assessment of treatment

Table 1 Diagnostic criteria for chronic nonbacterial osteomyelitis (CNO)

Parameter	Jansson criteria ^a	Bristol criteria ^{14,b}
Clinical findings	1. Palmoplantar dermatosis (pustulosis psoriasis) 2. Symptoms > 6 months 3. Autoimmune disease in first- or second-degree relatives	Typical clinical findings: 1. Localized bony pain ± swelling, without significant local or systemic features of inflammation or infection
Laboratory	1. Normal blood count 2. Mild to moderate increase in ESR and CRP	1. CRP typically < 30 g/L 2. If > 30 g/L, biopsy needed
Radiology (X-ray and STIR MRI)	1. Osteolytic/osteosclerotic lesions 2. Multifocality of lesions 3. Hyperostosis	1. Typical radiological features (X-ray) - Combination of lysis, sclerosis, and new bone formation or STIR MRI (preferable) - marrow edema, expansion, periosteal reaction 2. Multifocal involvement 3. If unifocal involvement (except clavicle), biopsy required
Histopathology	1. Sterile osseous biopsy with signs of inflammation, fibrosis, or sclerosis	1. Chronic inflammation, presence of osteoclasts and fibrosis, and/or sclerosis with no microorganism

Abbreviations: CRP, C-reactive protein; ESR, erythrocyte sedimentation rate; MRI, magnetic resonance imaging; STIR, short tau inversion recovery.

^aJansson criteria: CNO validated by two major, or one major plus three minor criteria, major criteria highlighted in bold and italics.

^bFor Bristol criteria, diagnosis of CNO is based on detection of both typical clinical and radiological findings along with either of the two:

1. Demonstration of multifocal involvement or clavicle and low (<30 g/L) CRP.
2. If CRP is >30 g/L, biopsy showing sterile inflammation.

response at follow-up.^{10–14,16,17} Typical imaging features preclude the need for biopsy as well.¹⁰ This review focuses on the role of imaging in the evaluation of CNO, with special emphasis on WBMRI in its assessment.

Imaging Modalities

Among the available diagnostic imaging modalities, radiographs and MRI are most useful in diagnosis and follow-up of CNO.

Conventional radiograph: Evaluation of CNO on imaging frequently begins with obtaining conventional radiographs at symptomatic site(s). Radiographs are important for excluding common differentials of CNO, most notably infection and malignancy and carry relevance when nondiagnostic sites are under consideration. They typically demonstrate osteolytic, sclerotic, or mixed medullary lesions involving metaphysis of long bones depending on the time of disease progression. Less frequent but more suggestive features include hyperostosis and solid or lamellated periosteal reaction (→Fig. 2).¹³ A significant soft tissue component is typically not seen, which helps in differentiation from malignancies. Absence of sequestrum and sinus tract formation helps to differentiate it from bacterial osteomyelitis.³ A skeletal survey may be as an alternative if MRI is unavailable. Although they may be the first clue to diagnosis, radiographs carry low sensitivity in the detection of CNO and may be normal during the first 3 months of the disease course. A negative radiograph (including a survey) may thus ultimately require an MRI for further evaluation.

MRI: MRI is extremely sensitive for detecting marrow involvement in CNO in a background of appropriate clinical context¹³ and can be performed in two ways—as a focused MRI of the affected part and as WBMRI. Focused MRI allows detailed evaluation and helps to exclude differential diagnoses,

however, suffers from the drawback of not detecting additional lesions and is hence largely replaced by WBMRI. Although MRI is free of radiation-related concerns which makes it useful in follow-up of pediatric patients, this advantage is limited by the requirement of sedation in younger children.

WBMRI has been widely accepted as a standard imaging tool in the assessment of CNO over localized imaging due to advantages of detecting additional lesions and multifocal disease (increasing the likelihood of the diagnosis), especially when the index lesion is atypical.¹⁶ By depicting all the lesions in one study, WBMRI aids in ascertaining the pattern of osseous involvement (tibial-appendicular multifocal pattern, clavicular-spinal pauci-focal pattern, tibio-clavicular crossover pattern; →Fig. 3).¹⁰ It also helps to quantify the disease in terms of number (of sites involved) and identifies complications like physeal and vertebral involvement which are important in prognostication.^{10,17,18} Other potential applications include identifying a biopsy target site and treatment response evaluation.^{11,16}

Role of computed tomography (CT) and bone scintigraphy: Radiological modalities which have reduced utility nowadays in the evaluation of CNO include CT and bone scintigraphy. CT demonstrates features similar to radiographs but the use is discouraged for routine and whole body evaluation unless unavoidable or done inadvertently.^{3,9} Similarly, although 99m-technetium bone scintigraphy may demonstrate areas of uptake in the involved bones, its role has diminished due to radiation-related concerns and availability of WBMRI.⁹

WBMRI-Based Evaluation

Technical Considerations

The increasing utilization of WBMRI in the diagnosis and assessing treatment response in CNO requires the use of

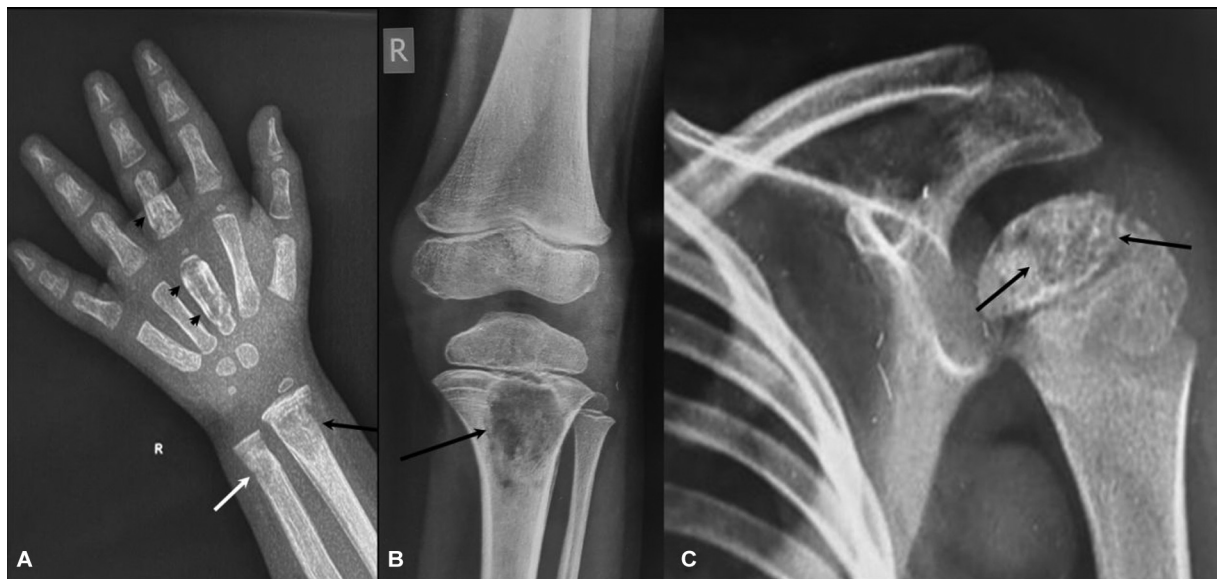

Fig. 2 Chronic nonbacterial osteomyelitis (CNO) in a 4-year-old male who complained of recurrent pain in bilateral wrists and right knee. (A) Posteroanterior (PA) view radiograph of the right wrist reveals an ill-defined lytic lesion in metaphyses of right distal radius with focal thinning and rarefaction of the medial cortex (black arrows, A), another similar lesion in distal ulna (white arrows, A) with hyperostotic lesions in metacarpals and phalanges of right 3rd digit (arrowheads, A). Frontal radiographs of right knee (A) and left shoulder show similar lytic lesions in proximal tibia (arrow, B) and proximal humerus (arrows, C).

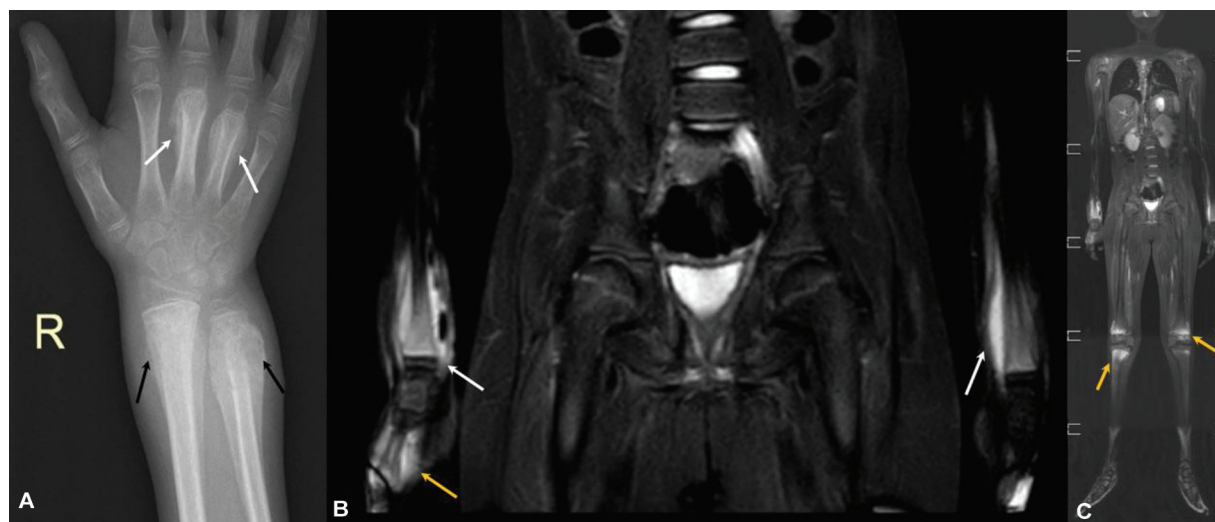


Fig. 3 Chronic nonbacterial osteomyelitis (CNO) in a 9-year-old male who complained of recurrent pain and swelling in bilateral wrist and knee joints. (A) Posteroanterior (PA) view radiograph of the right wrist demonstrates exuberant hyperostosis and solid periosteal reaction centered at the distal ulnar and radial metaphyses (black arrows, A) with similar changes in shafts of 3rd and 4th metacarpals (white arrows). (B) Coronal short tau inversion recovery (STIR) whole body magnetic resonance imaging (WBMRI) at the level of forearm shows hyperintense marrow alteration within the distal metaphysis and adjacent diaphysis of bilateral radii (white arrows) and right metacarpal (yellow arrow) with hyperintense signal in the subperiosteal plane and adjacent soft tissues. (C) Stitched coronal STIR WBMRI image in the same patient provides a review of the entire body and additionally shows similar signal abnormality at bilateral distal femoral and proximal tibial metaphyses in periphyseal location (yellow arrows). The pattern of involvement is consistent with “multifocal tibio- appendicular pattern” of CNO.

standardized protocols (with respect to sequences, planes of imaging, and scan time) for effective clinical communication and research.^{10,11} Image optimization should cater to increase the sensitivity of detection while simultaneously minimizing the scan times.^{10,11} **Table 2** highlights the relevant details pertaining to patient positioning and image acquisition.^{2,10,11,17–26}

Involvement of short bones of hands and feet has been increasingly found in CNO, ranging from 2 to 11%, with affection of feet being distinctly more common.^{18,20–22} While

talus and calcaneum remain the most frequently involved short bones,²² a study found metatarsal involvement in approximately 22% patients.¹⁸ Inclusion of both is hence essential for complete evaluation. Both carpal and tarsal lesions should, however, be interpreted with caution as these bones can inherently show high marrow signal owing to the normal stress and can be observed in normal children as well.¹⁰

No particular consensus exists with regards to positioning of hands and different studies have adopted different positions.^{17,23,24} Placing arms and hands besides the body leads

Table 2 Technical parameters of WBMRI acquisition in a suspected or follow-up case of CNO

Parameter	Relevant points
1. Field of view and matrix	Variable, ^{19,10,11,18} usual FOV: 480–480 mm ^a Matrix: 384–269 ^a
2. Number of stations	Depends primarily on the patient height and achieving maximum resolution, usually in between 4 and 8 for the coronal plane and 2 in sagittal plane for assessment of the spine ¹⁸ Essential to maintain same number and field size during follow-up
3. Coverage of clavicles	To be completely included either in the head and neck or chest field ¹⁰
4. Use of stitched images	May aid in follow-up as they provide an overview of the entire disease allowing easy comparison ^{2,10,18,19} ; however, not mandatory
5. Positioning of hands	a. Hands resting on the pelvis with additional body coil ^{16,23} b. Hands placed under the buttocks for inclusion in the pelvic scan (followed at author's institution) ¹⁷
6. Positioning of feet	Positioning in lateral view
7. Main planes of acquisition	Coronal for whole body and sagittal for spine
8. Main sequence	Short tau inversion recovery (STIR)
9. Additional sequences	Diffusion-weighted imaging (routinely done at author's institution) T1-weighted imaging

Abbreviations: CNO, chronic nonbacterial osteomyelitis; FOV, field of view; WBMRI, whole body magnetic resonance imaging.

^aParameters routinely used at the author's institution.

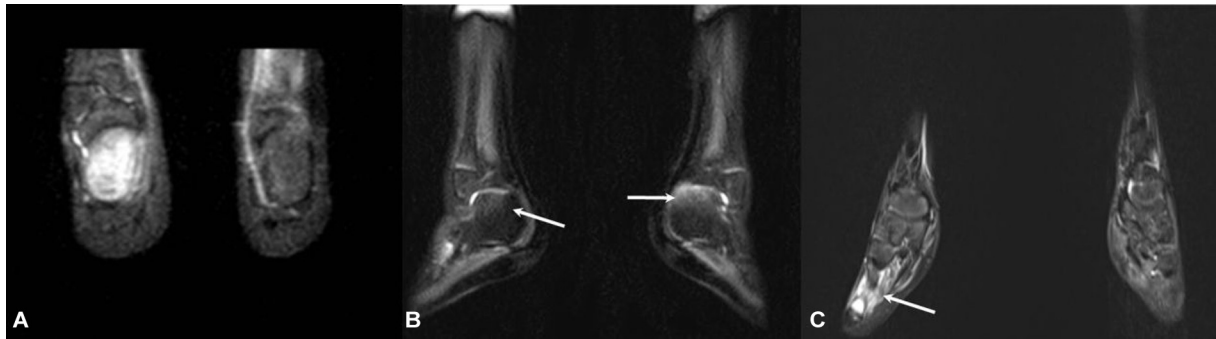


Fig. 4 Chronic nonbacterial osteomyelitis (CNO) with small bone involvement in different patients. (A) Calcaneal involvement in a 12-year-old female who complained fleeting bone pain. Coronal short tau inversion recovery (STIR) whole body magnetic resonance imaging (WBMRI) image demonstrates hyperintense signal in right calcaneus, suggesting involvement. (B and C) In another 11-year-old who complained of bilateral heel pain, external rotation of the feet during scanning allowed better evaluation of the calcaneus in the sagittal view (B) in comparison with a routine coronal view. Mild hyperintense signal is seen in bilateral calcaneal bones (arrows, B), which could be attributed to involvement. (C) An additional lesion in the right metatarsal (arrow, C) is also observed with associated periostitis.

to artifacts which reduces the sensitivity.²³ In order to overcome this, other options were suggested which include imaging the hands separately above the head, which however leads to increased scan times,^{24,25} resting of hands on the pelvis with an additional body coil,^{17,24} and placing the hands under the buttocks for inclusion in the pelvic scanning range.¹⁸ Utilization of the last two mentioned techniques can achieve better results with hands splayed (to avert air-skin interface artifact) in order to obtain good resolution without increasing scan times.¹⁰ The feet can be positioned in lateral view while obtaining the last station for improved visualization of talus and calcaneum (►Fig. 4).^{10,18} In cases of suboptimal imaging of the feet whenever covered as a part of routine station, a targeted MRI with sagittal scan of each foot is also suggested.^{17,26}

Imaging Planes and Sequences

WBMRI aims to cover the entire body within a stipulated time frame and hence relies on a minimal number of sequences (ideally single) and planes.¹⁰ However, besides the coronal plane which is used for routine imaging, a dedicated scan of the entire spine in the sagittal plane has been increasingly advocated during acquisition to improve detection of vertebral and sacral lesions.^{18,20,26} Two overlapping sections usually suffice for this purpose.²⁴ The thoracic, lumbar cervical, and sacral portions of the spine are involved in descending order.^{3,10,18,22} Incorporation of spinal imaging is essential due to increasing literature demonstrating evidence of spinal involvement in CNO. The reported frequency ranges from 8.4 to 33% in multiple studies.^{18,21,27–29} Another important reason is that early identification of spinal involvement allows institution of appropriate treatment before development of complications like pathological fracture, vertebral plana, kyphosis, and scoliosis.¹⁰ Vertebra plana in particular has been reported in approximately 22% patients by Falip et al.¹¹ A recent study has reported the incidence of kyphosis and scoliosis as high as 21 and 9.5%, respectively.³⁰ As loss of vertebral height is an irreversible process, it is advocated to image the spine in subclinical stages in order to institute appropriate treatment (i.e., bisphosphonates) so as to prevent deformity.^{29,31}

While short tau inversion recovery (STIR) sequence remains central during imaging with WBMRI in CNO due to its high sensitivity to detect marrow edema,²⁵ T1 and diffusion-weighted imaging (DWI) have also been utilized in the evaluation of CNO. T1-weighted images are useful to distinguish marrow edema due to CNO from hematopoietic marrow which does not suppress on STIR like fatty marrow. They also help in ascertaining the exact extent of involvement.^{23,32} A STIR hyperintense lesion showing T1 signal lower than the muscles or intervertebral disc indicates pathology as compared to hematopoietic marrow which does not. Dedicated T1 imaging can hence be utilized whenever such a situation arises for problem solving.¹⁰ DWI may be useful to differentiate CNO from malignancy with CNO lesions demonstrating higher apparent diffusion coefficient values than malignant lesions. It is simple and easy to perform and can be added as an additional sequence.³³ However, this comes at the expense of additional scan time, hence STIR remains the key sequence proven in literature to date. The sensitivity, additional value, and reliability of DWI in CNO need to be validated before it can be added as a routine additive sequence or can replace STIR. There is no particular role for contrast in WBMRI; however, a focused MRI of the part under consideration may be considered post-WBMRI acquisition in the context of unconventional clinical or WBMRI features (e.g., single lesion in nondiagnostic location) and multiple differential diagnoses.¹⁰

Imaging Findings

The diagnosis of CNO on imaging rests upon two major pillars which are demonstration of multifocal lesions (with involvement of specific sites) and recognition of the morphological features. Classic imaging appearances include presence of marrow edema, expansion, periosteal reactions, and soft tissue inflammation (►Figs. 3 and 5).^{17,18,22,34} Edema can vary from ill-defined to confluent “flame-like” in appearance and the flames project into the metaphyses from the physis.^{16,17} Signal-wise, active lesions typically show low T1 and moderate to high T2/STIR signal. They may show restricted diffusion on DWI images with variable contrast enhancement (whenever administered).⁷

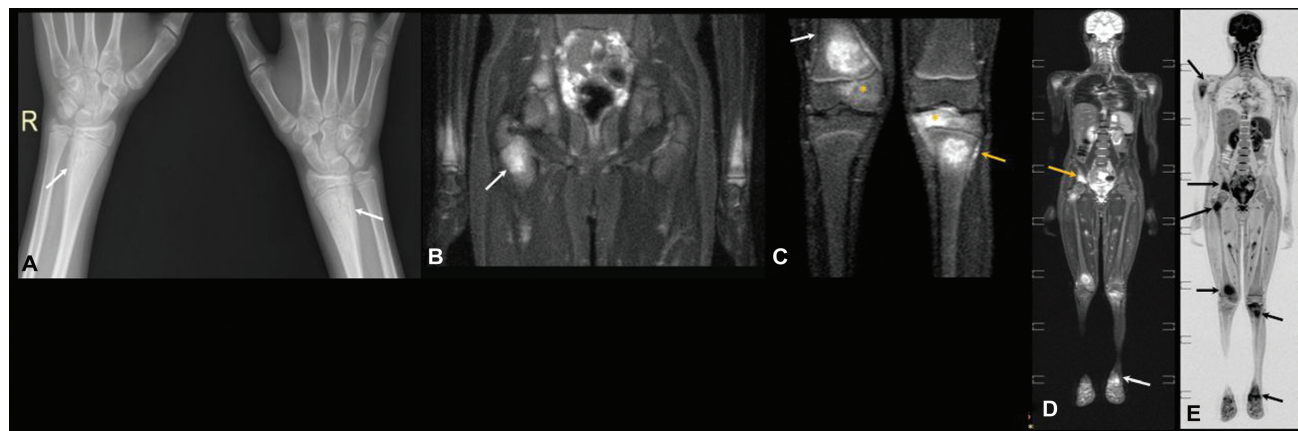


Fig. 5 Epiphyseal involvement in chronic nonbacterial osteomyelitis (CNO) in an adolescent with multiple joint pains. (A) Posteroanterior (PA) view radiograph at bilateral wrists shows subtle symmetric solid periosteal reaction in the distal metadiaphyseal location in bilateral radii (arrows). (B and C) Coronal short tau inversion recovery (STIR) images show multifocal metaphyseal lesions with adjacent periostitis in bilateral radii and right proximal femur (arrow, B) at juxtaphyseal location. Involvement of distal femoral (white arrow, C) and left proximal tibial metaphyses (yellow arrow, C) is characteristic as the two sites are most commonly involved in CNO. Epiphyses of bilateral distal radius, right distal femur, and left proximal tibia are also involved with the abnormal signal reaching up to subarticular location (asterisks, C). (D) Coronal whole body magnetic resonance imaging (WBMRI) STIR image shows bilateral symmetric involvement of proximal humeri with hyperintense lesions in right ilium (yellow arrow, D) and distal tibia (white arrow, D). (E) Reconstructed coronal diffusion-weighted image (DWI) with inverted grayscale demonstrates the previously illustrated lesions which appear dark (arrows, E).

As highlighted in its name, multifocality is a classic feature in CNO, with prevalence ranging from 89 to 98% in previous studies.^{18,20} Characteristic sites of involvement include long bone metaphyses, clavicle, mandible, sternum, and thoracolumbar spine.^{8,9,34}

Tibia is the most frequently affected long bone followed by femur, affecting approximately two-thirds and half of the patients, respectively, in a study.²⁷ Lesions are typically juxtaphyseal in location.^{10,32,34} Epiphyseal involvement has also been reported with a variable frequency, ranging from 35 to 67% in various studies^{17,18,34}; however, these lesions must demonstrate concomitant metaphyseal involvement to be considered typical for CNO (►Fig. 5).¹⁰ Bilateral and symmetric metaphyseal involvement is characteristic and such a pattern of long bone affliction in lower extremities combined with additional clavicular, sternal, vertebral, and pelvic lesions has been reported diagnostic in previous literature.^{10,20,22,34} Although less documented, involvement of growth plate is a potential complication leading to premature closure and growth disturbance with eventual limb length discrepancy and deformity.^{35,36}

CNO has been reported as the most common nonneoplastic cause of a clavicular lesion in the pediatric age group, affecting approximately 38% of patients.^{18,22} The medial one-third is frequently affected with associated periostitis, hyperostosis, and soft tissue STIR hyperintensity (►Fig. 6). Since bacterial osteomyelitis rarely occurs at this location and may be the sole location affected by CNO, isolated clavicular involvement is sufficient to meet the Bristol criteria during diagnosis.^{4,13}

The mandible remains the most common facial bone to be affected by CNO till date, found in up to 3% patients with CNO.³² While the majority patients demonstrate additional osseous involvement, an isolated mandibular pattern has also been described in literature. Wipff et al documented an

isolated involvement in 7% cases among patients with mandibular affliction.³² The posterior body of the mandible is most commonly affected, with occasional extension into the ramus. Medullary expansion and sclerosis, lytic destruction, and lamellar periosteal reaction with widening of the mandibular foramen are common imaging features.²²

Vertebral involvement is now considered as another important site in assessment and diagnosis of CNO, with reports describing affliction in up to 75% cases which may be asymptomatic.^{11,30,31,37} The thoracic spine is most commonly affected, being involved in approximately 54% of cases as per a recent study.³⁰ Typical spinal lesions are multifocal and involve the vertebral bodies in both a noncontiguous and a contiguous manner with sparing of the intervening discs.^{3,7,10,17,29} Appearances include altered marrow signal in the vertebral body representative of edema, with sclerosis and end plate irregularity (►Fig. 7).^{10,11,22,30} Absence of disc involvement, contiguous vertebral extension, and florid paravertebral soft tissue mass/collecton have traditionally remained useful features to distinguish CNO from infective spondylodiscitis (►Fig. 7).^{7,10} However, a few recent studies have described disc lesions and contiguous involvement with frequencies ranging from 14 to 26%, which prompts a second look before refuting the diagnosis of CNO on encountering such lesions.^{11,18,30} This may appear as a high STIR signal in the disc and loss of disc height.^{22,30} CNO should hence also be included as a differential for spondylodiscitis. Vertebral height loss and plana due to a fracture is a potential complication, as stated previously, and carries potential complications of deformity.¹⁰ Subclinical lesions may therefore benefit from institution of therapy to avoid these complications.^{5,8}

A study on CNO using WBMRI identified two classic patterns which included a tibio-appendicular multifocal pattern which was more frequently observed and reported in more than 50% patients (►Fig. 8).¹⁸ These cases demonstrated tibial

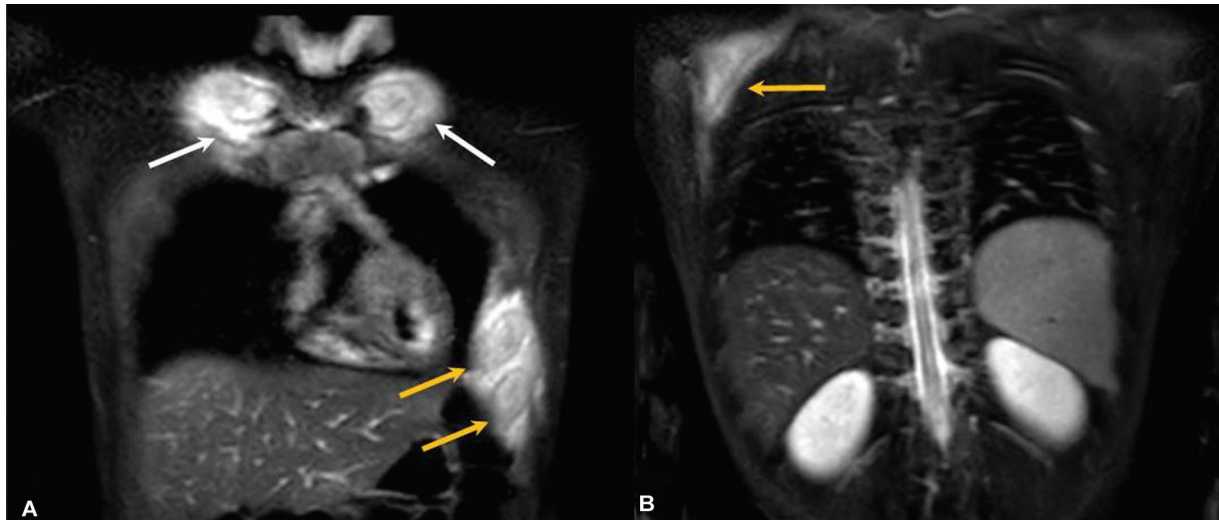


Fig. 6 Chronic nonbacterial osteomyelitis (CNO) with flat bone involvement. (A, B) Serial coronal short tau inversion recovery (STIR) whole body magnetic resonance imaging (WBMRI) images at the level of thorax in a 12-year-old with CNO show bony expansion, hyperintense marrow signal with periosteal involvement in left lower ribs (yellow arrow, A), bilateral medial clavicles (white arrows, A), with the latter being considered characteristic for diagnosis of CNO. Similar lesion is also seen in right scapula (yellow arrow, B).

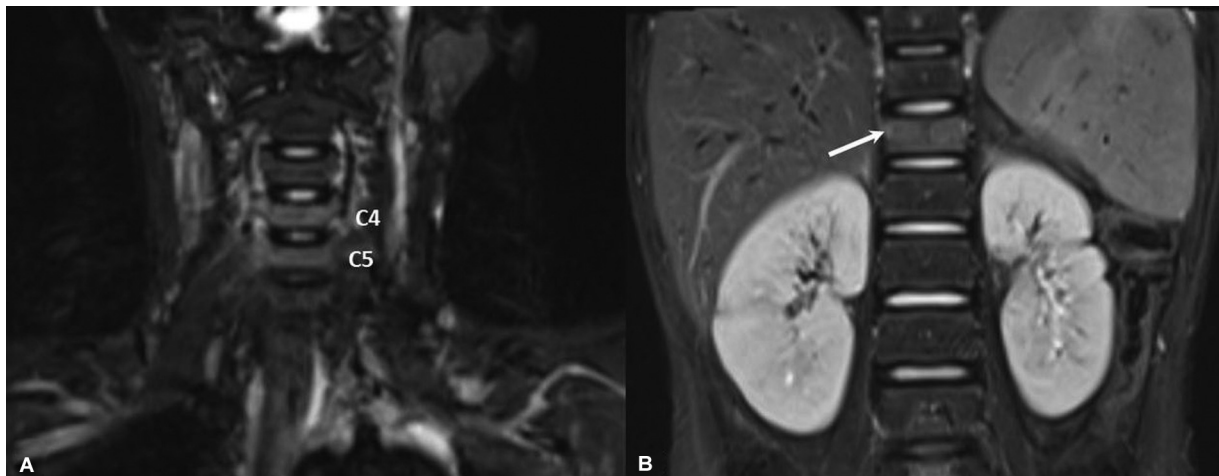


Fig. 7 Vertebral involvement in chronic nonbacterial osteomyelitis (CNO). (A and B) Coronal short tau inversion recovery (STIR) whole body magnetic resonance imaging (WBMRI) images in a patient with CNO show hyperintense signal in C4, C5, and D12 vertebral bodies with mild reduction in height in D12 vertebra (arrow, B). Intervening disc signal and height are preserved with lack of an associated soft tissue mass.

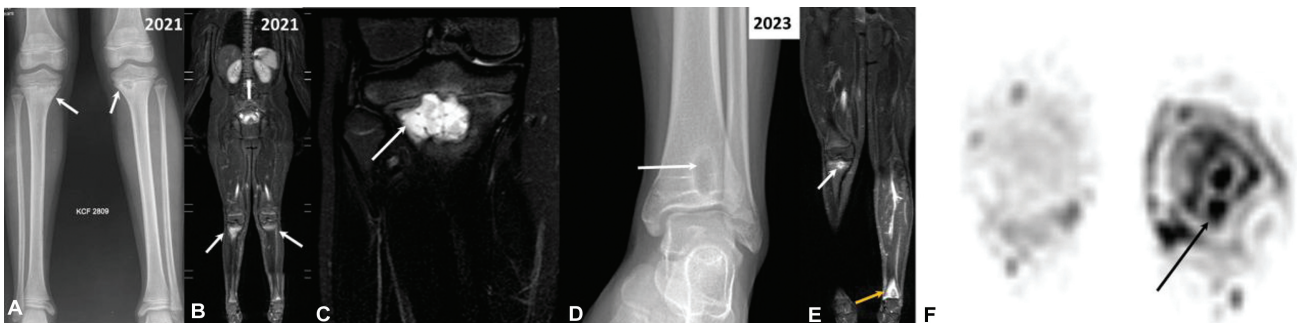


Fig. 8 Evolution of chronic nonbacterial osteomyelitis (CNO) in an 11-year-old boy who complained of left knee pain who was initially evaluated on lines of bacterial osteomyelitis. (A) Frontal radiograph of bilateral legs shows irregular lytic lesions in bilateral proximal tibial metaphyses with sclerotic rim (arrows, A). Coronal short tau inversion recovery (STIR) whole body magnetic resonance imaging (WBMRI) images (B and C) show hyperintense marrow signal (arrows, B and C) at corresponding location (C – zoomed image of right tibial lytic lesion). Radiograph done 2 years later showed a new metaphyseal lesion in distal left tibia (arrow, D). Coronal WBMRI STIR image shows reduction in size of right tibial lesion (white arrow, E) and confirms the left distal tibial lesion which shows surrounding edema (yellow arrow, E). Axial diffusion-weighted image (DWI) image (F) also assists in delineating the lesion (arrow, F).

lesions, multifocality, and had no clavicular involvement. The other pattern was a claviculo-spinal pauci-focal pattern, which showed clavicular lesions and mainly spinal lesions with no tibial involvement and was observed in roughly one-third of patients. A third pattern, named as tibio-clavicular crossover pattern, demonstrated synchronous clavicular and tibial involvement and accounted for 14% with mainly distal tibial lesions and was deemed as nonspecific for diagnosis.¹⁸

► **Table 3** provides a short review of the previously conducted studies on CNO using WBMRI.

Differential Diagnoses and Mimics

CNO needs to be differentiated from common entities like bacterial osteomyelitis, tuberculosis, JIA, Ewing’s sarcoma, Langerhans cell histiocytosis, Caffey’s disease, and scurvy.³⁸ Pertinent features are tabulated in ► **Table 4** (► **Figs. 9–11**). Among these, scurvy is increasingly being recognized in children with restrictive dietary patterns and may require additional sequences for differentiation. When considering unifocal lesions, location (e.g., clavicle), absence of exuberant soft tissue thickening and collections, combined with a protracted clinical course and laboratory investigations favor the possibility of CNO in such scenarios, but biopsy may ultimately be resorted to in case findings are still inconclusive.¹³

Additionally, while interpreting WBMRI scans, it is important to familiarize oneself with the normal signal of various osseous structures. Metatarsals, tarsals, and carpals may inherently show high STIR signal which requires caution during reporting especially in absence of classical sites involvement.^{10,39} Whenever in doubt, dedicated T1 imaging may be useful, however, at the expense of increased scan time. Similarly, bilateral symmetrical high STIR signal band like areas in patients on cyclical bisphosphonate therapy (notably pamidronate), presumably due to increased enchondral ossification, have been noted previously in literature¹⁰ and should be interpreted with caution especially in patients on therapy.⁴⁰

Available Guidelines and Scoring Systems

There has been a growing need for grading and determining the severity of disease on imaging in CNO as it essentially is a chronic disease with phases of relapses and remissions.^{41–43} Clinicians are increasingly relying upon WBMRI to assess the need for adding immunomodulation with additional follow-up imaging after 6 to 12 months to see response.^{4,10,41} At present, there is paucity of definite guidelines recommending a specific interval of follow-up in CNO. At the author’s institution, follow-up imaging is done at 6 months or earlier in cases of clinical relapse or progression.

Multiple studies have attempted to correlate the lesion load, size, and intralesional signal intensities with the clinical activity.^{17,41–45} Arnoldi et al proposed a scoring system for WBMRI findings of CNO and named it the Radiologic Index for Non-Bacterial Osteitis (RINBO) scoring system.¹⁷ The score assigns points (out of maximum of 10) to four criteria

Table 3 Summary of previously conducted studies on CNO using WBMRI

References	Study design (total population)	STIR plane ^a	Additional sequences	Acquisition Plane for additional sequences	Highlights
Fritz et al 2009 ³⁴	Retrospective (13)	Coronal	T1 pre- and postcontrast	Coronal	Most common site – femur (21%) followed by tibia (17%) In tubular bones metaphysis (86%) was most commonly involved and 67% showed epiphyseal involvement; 89% (66 out of 74) showed contiguous physseal relationship
Guérin-Pfiffer et al 2012 ¹⁹	Retrospective (9)	Coronal	T1 and T2	Coronal with dedicated axial in affected areas on imaging	Comparative study with bone scintigraphy Most frequent sites - pelvis followed by femur; spinal and pelvic involvement better seen on MRI as compared to scintigraphy
Falip et al 2013 ¹¹	Retrospective with longitudinal review (31)	Coronal/sagittal	T1	Coronal/sagittal; sagittal sequences performed for spine	Femoral and tibial involvement most common; 75% showed medullary edema with juxtaphyseal nodule-like appearance in 16% of lesions Recommended long-term monitoring for vertebral collapse

Table 3 (Continued)

References	Study design (total population)	STIR plane ^a	Additional sequences	Acquisition Plane for additional sequences	Highlights
Von Kalle et al 2013 ²⁰	Retrospective (53)	Coronal	Dedicated STIR imaging for shoulder, pelvis, and spine if affected on imaging	Sagittal and axial	98% demonstrated multifocal lesions; 75% had bilateral symmetrical bone involvement; pelvis, lower extremities, and spine were most commonly involved; 7.2% showed bone deformations with vertebra plana in 6%
Voit et al 2015 ²⁴	Prospective (17)	Coronal, sagittal	T1	Coronal, sagittal	Four patients showed active lesions despite clinical remission; 35% cases had spinal involvement (fractures/plana/hemifusion) Radiological follow-up recommended for patients in clinical remission
Leclair et al 2016 ³³	Prospective (16)	Coronal and axial	DWI; 3T B-values: 800 4-mm slice reconstructed in 5 mm coronal plane and as thick 3D MIP ADC values of lesion and corresponding reference locations were considered	Axial	First dedicated study on CNO patients utilizing DWI sequences. ADC values significantly elevated in CNO lesions with a mean relative increase of 69%; images nondiagnostic due to artifacts in 2 patients Comparison with STIR not done; useful as an additional sequence for exclusion of other differentials; additional ~15 min scan time
Arnoldi et al 2017 ¹⁷	Prospective (40)	Coronal, sagittal	T1 DWI in 11 patients (no results presented)	Coronal, sagittal	WBMRI detects asymptomatic disease with good correlation between clinically and radiologically active lesions; proposed RINBO as scoring index to offer standardized evaluation
Andronikou et al 2019 ¹⁸	Retrospective (37)	Coronal	DWI B-values of 0 and 800 with ADC values	Axial	Demonstrated two distinct morphological patterns on WBMRI - "tibio-appendicular multifocal" and "claviculo-spinal pauci-focal" patterns; 20 and 22% of the patients in two groups, respectively, had metatarsal and phalangeal involvement Proposed pictorial assessment for mapping and follow-up
Panwar et al 2021 ⁴¹	Retrospective (32)	Coronal, sagittal	-	-	WBMRI useful in objective assessment of lesion load and response to bisphosphonates; vertebral lesions showed highest response to treatment A scoring system was utilized and lesions were placed in the following groups - head, shoulder girdle, upper, lower extremities, hand, feet, pelvis, and spine; involvement of posterior elements was separately recorded

(Continued)

Table 3 (Continued)

References	Study design (total population)	STIR plane ^a	Additional sequences	Acquisition Plane for additional sequences	Highlights
Kieninger et al 2022 ⁴²	Retrospective (20)	Coronal	Postcontrast 3D T1	Axial	Use of WBMRI within 6 months of clinical suspicion can substantially increase the diagnostic accuracy; intralésional signal intensity ratios different in responders and nonresponders; both lesion volume and signal may assist in assessment of treatment response
Menashe et al 2022 ⁴³ Utilized CROMRIS system for evaluation	Retrospective (54)	Coronal, axial, and sagittal	–	–	Substantial correlation between lesion number and clinical severity at initial presentation
Guariento et al 2023 ³⁰	Retrospective (42)	Coronal and sagittal	T1 and T2	Sagittal	Focused assessment of spinal CNO 59.25% (25) had multifocal vertebral involvement, disc and posterior elements involved in 26 and 43%, respectively; most frequent imaging finding was focal edema in the superior aspect; height loss in 34% patients

Abbreviations: 3D, three-dimensional; ADC, apparent diffusion coefficient; CNO, chronic nonbacterial osteomyelitis; CROMRIS, chronic nonbacterial osteomyelitis MRI Scoring; DWI, diffusion-weighted imaging; MIP, maximum intensity projection; MRI, magnetic resonance imaging; RINBO, Radiologic Index for Non-Bacterial Osteitis; STIR, short tau inversion recovery; WBMRI, whole body magnetic resonance imaging. ^aSTIR was the main sequence in all studies.

which included increasing number of “radiologically active lesions” (unifocal, paucifocal, multifocal; out of 3 point scale), increasing lesion size (< 10, 10–100, and 100 mm, out of 3 point scale), presence of periosteal reaction and hyperostosis (labeled as acute and chronic extramedullary involvement, 1 point each), and vertebral body involvement (signal or deformity, 1 point each).¹⁷ The authors demonstrated it to be a predictor of clinically active lesions, improved standardized reporting, and allowed radiologic grading in terms of disease burden thereby aiding in prediction of the clinical course.¹⁷ However, this system did not provide any insight to assist in the diagnosis of the disease, that is, scoring based on whether lesions are typical, probable, indeterminate, or against a diagnosis of CNO.

CROMRIS (chronic nonbacterial osteomyelitis MRI Scoring) tool was another comprehensive system developed after a consensus panel with 11 radiologists and demonstrated good interobserver reliability in assessing the osseous and soft tissue involvement of CNO.⁴⁴ It included definition of various features observed in CNO (bone marrow hyperintensity, soft tissue hyperintensity, bony expansion, joint effusion), grading of marrow signal intensity in relation to fluid signal, size of signal intensity (< 25, 25–50, > 50% of volume), and division of osseous structures into multiple “bone units.” Inclusion of vertebral height loss and kyphosis is a pertinent feature incorporated in this system.⁴⁴ A score allocation per se was, however, not incorporated in CROMRIS.

Radiological activity index-CROMRIS (RAI-CROMRIS) system is another system devised on the basis of CROMRIS for scoring the disease activity in CNO.⁴⁵ Each involved bone unit was evaluated for bone marrow hyperintensity (scored from 0 to 1), presence of soft tissue/periosteal hyperintensity (scored from 0 to 1), extension of signal hyperintensity (scored from 1 to 3), and bony expansion and vertebral collapse (each scored from 0 to 1). The maximum score for each bone unit was 7.⁴⁵ The total score from all active CNO lesions were summed up as the final score on the whole body level.

Alternatively, few authors have also devised pictorial maps and pro formas to demonstrate lesion distribution and pattern in CNO, which allows a personalized approach in diagnosis and management of the disease.^{18,20,32} They are simple to understand and additionally highlight the disease pattern along with lesion number which in turn aids in correlation with the disease severity and response to treatment.^{18,32} A good image-based scoring system should be reproducible, easy to communicate, should aid in diagnosis, and stratification with provision of information regarding disease prognosis.

A recent study has attempted to utilize artificial intelligence in response assessment of CNO. The authors devised a machine learning algorithm which compared segments of pre- and post-bisphosphonate therapy images derived from WBMRI to assess treatment response.⁴⁶ These results were additionally compared with the results obtained by assessment of the same set of images by a panel of radiologists, which were also deemed as the ground truth. Out of a total of six test samples, the model classified two (33.3%) examples

Table 4 Differential diagnoses of CNO on imaging

Disease	Features that may mimic CNO	Differentiating features from CNO
1. Bacterial osteomyelitis	Metaphyseal involvement	Usually unifocal Diaphyseal involvement of long bones and flat bone involvement is rare Subperiosteal and soft tissue collections
2. Tubercular osteomyelitis	Metaphyseal involvement	Uni- or multifocal (especially in spine) In long bones – intermediate to low T2 signal, peripheral T1 hyperintense rim (higher than the central part, but lower than normal fatty marrow) Presence of intraosseous abscesses and perilesional lymphadenopathy, subperiosteal, and soft tissue collections Spine (spondylitis) – paradiskal and diskal involvement is very common, soft tissue collections
3. Ewing's sarcoma	Flat bone involvement	Pattern of destruction in flat bone Ewing's sarcoma is more permeative lytic than that in CNO Aggressive periosteal reaction in Ewing's as compared to solid reaction in CNO Soft tissue component is remarkably more in Ewing's sarcoma ³⁸
4. Langerhans cell histiocytosis (LCH)	Multifocality Flat bone involvement	Geographic lytic bone destruction pattern is seen more in LCH ³⁸ Lesions demonstrate beveled edges Associated solid soft tissue component
5. Scurvy	Metaphyseal involvement, lamellated periosteal reaction due to subperiosteal hematoma	Dense line of provisional ossification and metaphyseal corner fractures on radiographs Identification of subperiosteal hemorrhage (T1 hyperintense) on MRI; is, however, dependent on the stage of recognition
6. Caffey's disease	Hyperostosis and periostitis on radiographs	Presents at an earlier age (< 6 months) Flat bone involvement more common (mandible, ribs) Self-limiting nature
7. Juvenile idiopathic arthritis (JIA)	Periostitis Metaphyseal bone marrow edema may simulate CNO	"Joint-centered disease" X-ray - Periarticular osteopenia, erosions, soft tissue swelling, and joint effusion, epiphyseal overgrowth in later stages MRI - Synovitis (high signal of STIR with enhancement), epiphyseal cartilage defects, and enthesopathy
8. Focal periphyseal edema zone (FOPE)	Involvement of periphyseal metaphyses, physis, and epiphysis centered around knee (most common location of CRMO)	Typically unifocal marrow edema, central location, physis appears narrowed at same level Associated with meniscal injuries and discoid meniscus Self-limiting

Abbreviations: CNO, chronic nonbacterial osteomyelitis; CRMO, chronic recurrent multifocal osteomyelitis; MRI, magnetic resonance imaging; STIR, short tau inversion recovery.

correctly and showed 100% sensitivity in detecting disease improvement or progression.⁴⁶

Conclusion

A diagnosis of CNO should be considered for all atypical cases of infection and malignancies in pediatric patients, even when unifocal disease is present. WBMRI has become an essential imaging modality in diagnosis, prognostication, and follow-up of CNO. Routine imaging with WBMRI should include sagittal sequences for spinal assessment. In the light of increasing involvement of hands and feet, appropriate coverage is pertinent through proper positioning. Dedicated T1 and DWI sequences may be utilized for problem solving. Lastly, all such modifications should be done while keeping in mind

the scan times. Radiologists should familiarize themselves with common locations, imaging appearances, and patterns of CNO (multifocal tibio-appendicular vs. paucifocal claviculo-spinal) while excluding differentials and common variants. Reporting of spinal and physeal involvement is essential to avoid deformities. Usage of scoring systems and pictorial maps which highlight lesion load and distribution can assist in evaluation of treatment response during follow-up scans.

Answers pertaining to the introductory radiograph (→ Fig. 1)

1. Frontal chest radiograph demonstrates exuberant hyperostosis and solid periosteal reaction with the medial and middle thirds of the left clavicle. Right clavicle appears normal.

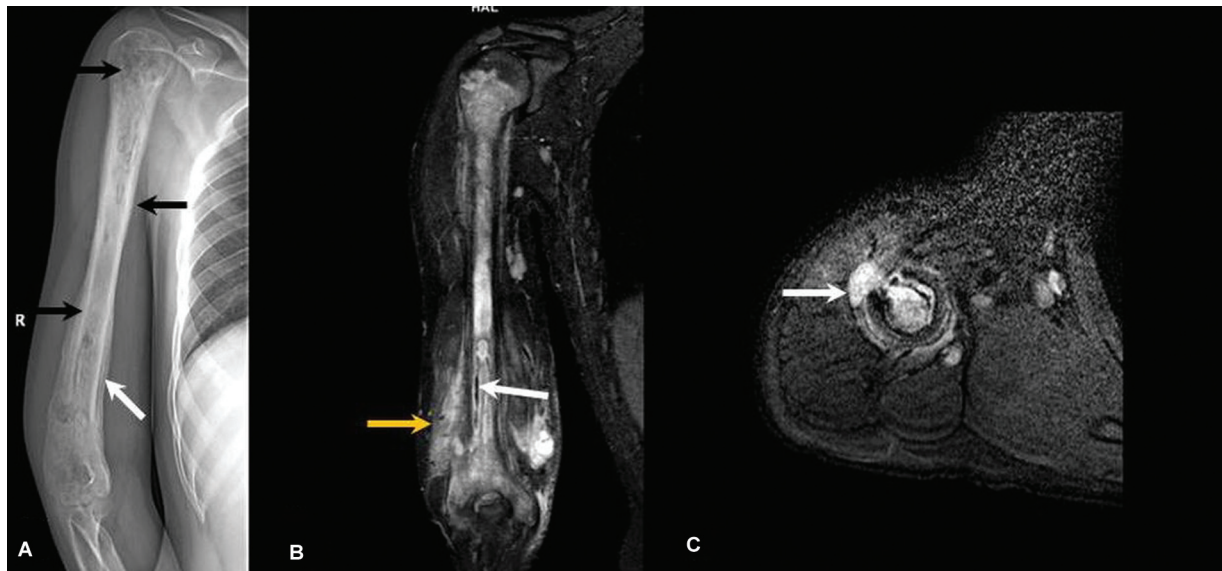


Fig. 9 Differential diagnoses of chronic nonbacterial osteomyelitis (CNO): Chronic bacterial osteomyelitis. Frontal radiograph of the right humerus shows ill-defined permeative destruction (black arrows, A) of the almost the entire humeral shaft with associated lamellated periosteal reaction (white arrow, A). Coronal (B) and axial (C) short tau inversion recovery (STIR) images show diffusely altered marrow signal within humerus with T2 hypointense sequestrum formation in the lower aspect (white arrow, B), subperiosteal T2 hyperintense soft tissue (yellow arrow) and a defect in the anterior cortex, suggesting cloaca formation (arrow, C).

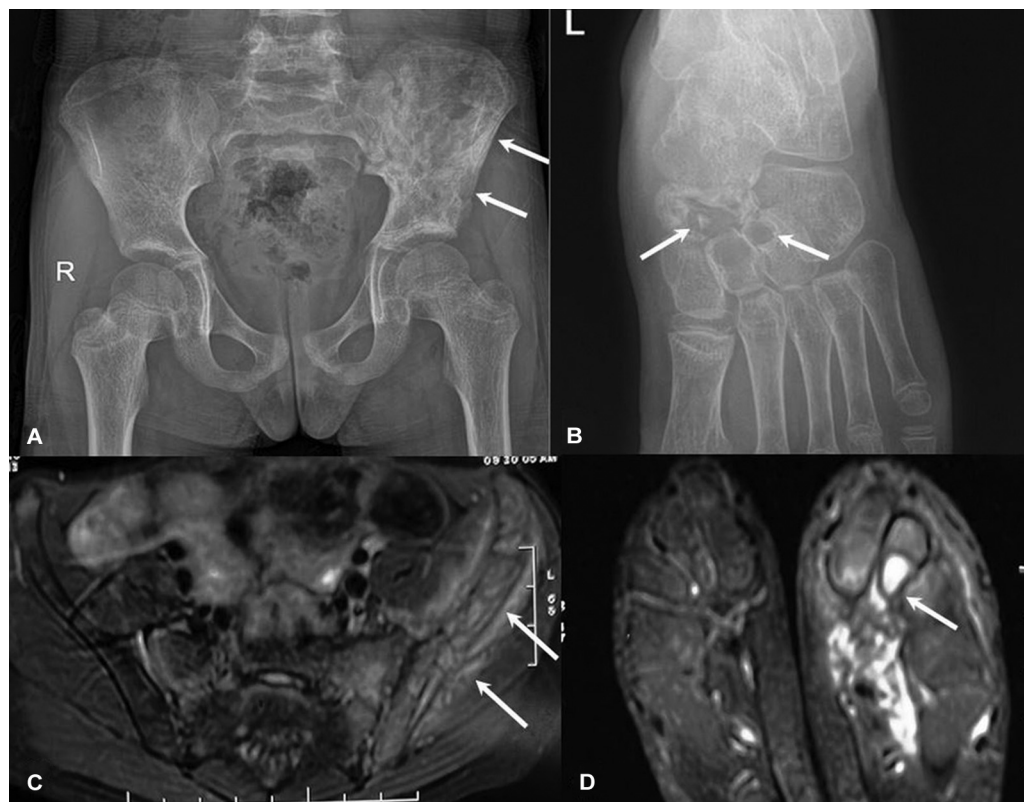


Fig. 10 Differential diagnoses: Tubercular osteomyelitis. Frontal radiograph of pelvis (A) demonstrates an irregular lytic sclerotic lesion in left iliac wing (arrows, A). Left foot radiograph shows multiple well-defined clustered lytic lesions in the navicular, middle, and lateral cuneiforms (arrows, B). Axial fat-suppressed T2-weighted images at level of pelvis (C) demonstrates hyperintense marrow signal in left iliac wing with adjacent inflammatory changes extending into the soft tissues (arrows, C). Axial fat-suppressed T2-weighted images at level of foot (D) shows marrow alteration within the tarsal bones with a well-defined intraosseous cyst-like lesion within the middle cuneiform, indicating an abscess (arrow, D).

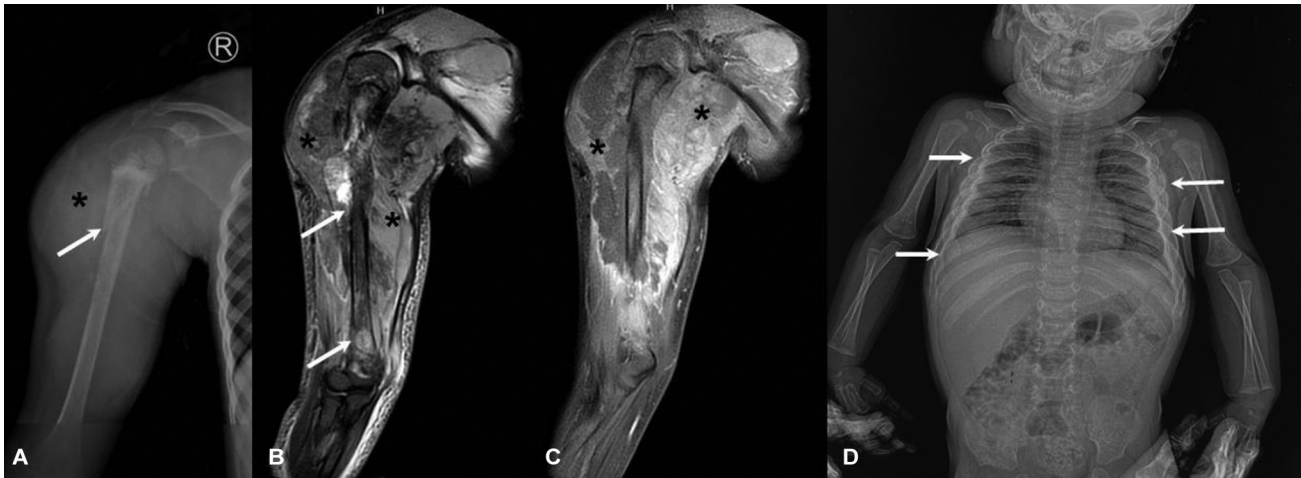


Fig. 11 Differential diagnoses: (A–C) Ewing’s sarcoma in a 10-year-old with right arm swelling. Frontal radiograph demonstrates an ill-defined lytic lesion in right proximal humeral metadiaphysis with wide zone of transition, pathological fracture (arrow, A), and a disproportionate soft tissue component (asterisk, A). Coronal T2 fat-suppressed and postcontrast images assist in delineating the widespread marrow involvement, which spans the entire humerus (arrows, B), with physeal involvement and a large heterogeneous soft tissue component (asterisks, B and C). (D) Caffey’s disease in an infant. Infantogram (D) shows expansion and hyperostosis in lateral ends of bilateral ribs (arrows, D).

2. Possibilities based on the radiographic appearance include CNO and Ewing’s sarcoma.
3. Symptoms and laboratory features should be elicited. Whole body MRI to be planned after a clinic-radiological discussion.

Funding

None.

Conflict of Interest

None declared.

Acknowledgment

We thank patients and their families for sharing the images to enable learning for other professionals about this entity.

References

- 1 Giedion A, Holthusen W, Masel LF, Vischer D. Subacute and chronic “symmetrical” osteomyelitis. *Ann Radiol (Paris)* 1972; 15(03):329–342
- 2 Hofmann SR, Kapplusch F, Girschick HJ, et al. Chronic recurrent multifocal osteomyelitis (CRMO): presentation, pathogenesis, and treatment. *Curr Osteoporos Rep* 2017;15(06):542–554
- 3 Nico MA, Araújo FF, Guimarães JB, da Cruz IA, Silva FD, Carneiro BC. Chronic non-bacterial osteomyelitis: the role of whole-body MRI. *Insights Imaging* 2022;13(01):1–2
- 4 Sergi CM, Miller E, Demellawy DE, Shen F, Zhang M. Chronic recurrent multifocal osteomyelitis. A narrative and pictorial review. *Front Immunol* 2022;13:959575
- 5 Ferguson PJ, Chen S, Tayeh MK, et al. Homozygous mutations in LPIN2 are responsible for the syndrome of chronic recurrent multifocal osteomyelitis and congenital dyserythropoietic anaemia (Majeed syndrome). *J Med Genet* 2005;42(07):551–557
- 6 Martinez-Rios C, Jariwala MP, Highmore K, et al. Imaging findings of sterile pyogenic arthritis, pyoderma gangrenosum and acne (PAPA) syndrome: differential diagnosis and review of the literature. *Pediatr Radiol* 2019;49(01):23–36
- 7 Hedrich CM, Morbach H, Reiser C, Girschick HJ. New insights into adult and paediatric chronic non-bacterial osteomyelitis CNO. *Curr Rheumatol Rep* 2020;22(09):52
- 8 Zhao Y, Ferguson PJ. Chronic non-bacterial osteomyelitis and chronic recurrent multifocal osteomyelitis in children. *Pediatr Clin North Am* 2018;65(04):783–800
- 9 Hedrich CM, Hofmann SR, Pablik J, Morbach H, Girschick HJ. Autoinflammatory bone disorders with special focus on chronic recurrent multifocal osteomyelitis (CRMO). *Pediatr Rheumatol Online J* 2013;11(01):47
- 10 Andronikou S, Kraft JK, Offiah AC, et al. Whole-body MRI in the diagnosis of paediatric CNO/CRMO. *Rheumatology (Oxford)* 2020; 59(10):2671–2680
- 11 Falip C, Alison M, Boutry N, et al. Chronic recurrent multifocal osteomyelitis (CRMO): a longitudinal case series review. *Pediatr Radiol* 2013;43(03):355–375
- 12 Jansson A, Renner ED, Ramser J, et al. Classification of non-bacterial osteitis: retrospective study of clinical, immunological and genetic aspects in 89 patients. *Rheumatology (Oxford)* 2007; 46(01):154–160
- 13 Rivas Felice J, González Herranz P, Mejía Casado A, Pérez Navarro R, Hernández Díaz R. Chronic recurrent osteomyelitis: a diagnostic and therapeutic challenge [in Spanish]. *Rev Esp Cir Ortop Traumatol* 2017;61(01):35–42
- 14 Roderick MR, Shah R, Rogers V, Finn A, Ramanan AV. Chronic recurrent multifocal osteomyelitis (CRMO) - advancing the diagnosis. *Pediatr Rheumatol Online J* 2016;14(01):47
- 15 Patel AM, Lee K, Kim A. OA02 Validation of newly proposed ACR/EULAR classification criteria for paediatric chronic non-bacterial osteomyelitis. *Rheumatology* 2023;62(Suppl 3):kead 323–002
- 16 Iyer RS, Thapa MM, Chew FS. Chronic recurrent multifocal osteomyelitis: review. *AJR Am J Roentgenol* 2011;196(6, Suppl):S87–S91
- 17 Arnoldi AP, Schlett CL, Douis H, et al. Whole-body MRI in patients with non-bacterial osteitis: radiological findings and correlation with clinical data. *Eur Radiol* 2017;27(06):2391–2399
- 18 Andronikou S, Mendes da Costa T, Hussien M, Ramanan AV. Radiological diagnosis of chronic recurrent multifocal osteomyelitis using whole-body MRI-based lesion distribution patterns. *Clin Radiol* 2019;74(09):737.e3–737.e15
- 19 Guérin-Pfyffer S, Guillaume-Czitrom S, Tammam S, Koné-Paut I. Evaluation of chronic recurrent multifocal osteitis in children by whole-body magnetic resonance imaging. *Joint Bone Spine* 2012; 79(06):616–620
- 20 Von Kalle T, Heim N, Hospach T, Langendörfer M, Winkler P, Stuber T. Typical patterns of bone involvement in whole-body

- MRI of patients with chronic recurrent multifocal osteomyelitis (CRMO). In: *RöFo-Fortschritte auf dem Gebiet der Röntgenstrahlen und der bildgebenden Verfahren*. 2013 Georg ThiemeVerlag KG; Stuttgart, Germany:655–661
- 21 Girschick HJ, Raab P, Surbaum S, et al. Chronic non-bacterial osteomyelitis in children. *Ann Rheum Dis* 2005;64(02):279–285
 - 22 Khanna G, Sato TS, Ferguson P. Imaging of chronic recurrent multifocal osteomyelitis. *Radiographics* 2009;29(04):1159–1177
 - 23 Damasio MB, Magnaguagno F, Stagnaro G. Whole-body MRI: non-oncological applications in paediatrics. *Radiol Med* 2016;121(05):454–461
 - 24 Voit AM, Arnoldi AP, Douis H, et al. Whole-body magnetic resonance imaging in chronic recurrent multifocal osteomyelitis: clinical longterm assessment may underestimate activity. *J Rheumatol* 2015;42(08):1455–1462
 - 25 Ley S, Ley-Zaporozhan J, Schenk JP. Whole-body MRI in the pediatric patient. *Eur J Radiol* 2009;70(03):442–451
 - 26 Darge K, Jaramillo D, Siegel MJ. Whole-body MRI in children: current status and future applications. *Eur J Radiol* 2008;68(02):289–298
 - 27 Beck C, Morbach H, Beer M, et al. Chronic nonbacterial osteomyelitis in childhood: prospective follow-up during the first year of anti-inflammatory treatment. *Arthritis Res Ther* 2010;12(02):R74
 - 28 Shah A, Rosenkranz M, Thapa M. Review of spinal involvement in chronic recurrent multifocal osteomyelitis (CRMO): what radiologists need to know about CRMO and its imitators. *Clin Imaging* 2022;81:122–135
 - 29 Hospach T, Langendoerfer M, von Kalle T, Maier J, Dannecker GE. Spinal involvement in chronic recurrent multifocal osteomyelitis (CRMO) in childhood and effect of pamidronate. *Eur J Pediatr* 2010;169(09):1105–1111
 - 30 Guariento A, Sharma P, Andronikou S. MRI features of spinal chronic recurrent multifocal osteomyelitis/chronic non-bacterial osteomyelitis in children. *Pediatr Radiol* 2023;53(10):2092–2103
 - 31 Taddio A, Zennaro F, Pastore S, Cimaz R. An update on the pathogenesis and treatment of chronic recurrent multifocal osteomyelitis in children. *Paediatr Drugs* 2017;19(03):165–172
 - 32 Wipff J, Costantino F, Lemelle I, et al. A large national cohort of French patients with chronic recurrent multifocal osteitis. *Arthritis Rheumatol* 2015;67(04):1128–1137
 - 33 Leclair N, Thörmer G, Sorge I, Ritter L, Schuster V, Hirsch FW. Whole-body diffusion-weighted imaging in chronic recurrent multifocal osteomyelitis in children. *PLoS One* 2016;11(01):e0147523
 - 34 Fritz J, Tzaribatchev N, Claussen CD, Carrino JA, Horger MS. Chronic recurrent multifocal osteomyelitis: comparison of whole-body MR imaging with radiography and correlation with clinical and laboratory data. *Radiology* 2009;252(03):842–851
 - 35 Walsh P, Manners PJ, Vercoe J, Burgner D, Murray KJ. Chronic recurrent multifocal osteomyelitis in children: nine years' experience at a statewide tertiary paediatric rheumatology referral centre. *Rheumatology (Oxford)* 2015;54(09):1688–1691
 - 36 Huber AM, Lam PY, Duffy CM, et al. Chronic recurrent multifocal osteomyelitis: clinical outcomes after more than five years of follow-up. *J Pediatr* 2002;141(02):198–203
 - 37 Jansson AF, Grote VESPED Study Group. Nonbacterial osteitis in children: data of a German Incidence Surveillance Study. *Acta Paediatr* 2011;100(08):1150–1157
 - 38 Menashe SJ, Aboughalia H, Zhao Y, et al. The many faces of pediatric chronic recurrent multifocal osteomyelitis (CRMO): a practical location- and case-based approach to differentiate CRMO from its mimics. *J Magn Reson Imaging* 2021;54(02):391–400
 - 39 Pal CR, Tasker AD, Ostlere SJ, Watson MS. Heterogeneous signal in bone marrow on MRI of children's feet: a normal finding? *Skeletal Radiol* 1999;28(05):274–278
 - 40 Schaal MC, Gendler L, Ammann B, et al. Imaging in non-bacterial osteomyelitis in children and adolescents: diagnosis, differential diagnosis and follow-up—an educational review based on a literature survey and own clinical experiences. *Insights Imaging* 2021;12(01):113
 - 41 Panwar J, Tolend M, Lim L, et al. Whole-body MRI quantification for assessment of bone lesions in chronic non-bacterial osteomyelitis patients treated with pamidronate: a prevalence, reproducibility, and responsiveness study. *J Rheumatol* 2021;48(05):751–759
 - 42 Kieninger A, Schäfer JF, Tsiflikas I, et al. Early diagnosis and response assessment in chronic recurrent multifocal osteomyelitis: changes in lesion volume and signal intensity assessed by whole-body MRI. *Br J Radiol* 2022;95(1130):20211091
 - 43 Menashe SJ, Iyer RS, Ngo AV, Rosenwasser NL, Zhao Y, Maloney E. Whole-body MRI at initial presentation of pediatric chronic recurrent multifocal osteomyelitis and correlation with clinical assessment. *Pediatr Radiol* 2022;52(12):2377–2387
 - 44 Zhao Y, Sato TS, Nielsen SM, et al. Development of a scoring tool for chronic non-bacterial osteomyelitis magnetic resonance imaging and evaluation of its interrater reliability. *J Rheumatol* 2020;47(05):739–747
 - 45 Capponi M, Pires Marafon D, Rivosecchi F, et al. Assessment of disease activity using a whole-body MRI derived radiological activity index in chronic nonbacterial osteomyelitis. *Pediatr Rheumatol Online J* 2021;19(01):123
 - 46 Bhat CS, Chopra M, Andronikou S, et al. Artificial intelligence for interpretation of segments of whole body MRI in CNO: pilot study comparing radiologists versus machine learning algorithm. *Pediatr Rheumatol Online J* 2020;18(01):47