



Update on the Role of Imaging in the Diagnosis, Staging, and Prognostication of Gallbladder Cancer

Pratyaksha Rana¹ Daneshwari Kalage² Raghuraman Soundararajan³ Pankaj Gupta⁴

¹Department of Radiology, U. N. Mehta Institute of Cardiology and Research Centre, Ahmedabad, Gujarat, India

²Department of Radiology, SDM College of Medical Sciences and Hospital, Dharwad, Karnataka, India

³Department of Radiodiagnosis, All India Institute of Medical Sciences, Nagpur, Nagpur, Maharashtra, India

⁴Department of Radiodiagnosis and Imaging, Post Graduate Institute of Medical Education and Research, Chandigarh, India

Address for correspondence Pankaj Gupta, MD, Department of Radiodiagnosis and Imaging, Post Graduate Institute of Medical Education and Research, Chandigarh, India (e-mail: pankajgupta959@gmail.com).

Indian J Radiol Imaging

Abstract

Gallbladder cancer (GBC) is a highly aggressive malignancy with dismal prognosis. GBC is characterized by marked geographic predilection. GBC has distinct morphological types that pose unique challenges in diagnosis and differentiation from benign lesions. There are no specific clinical or serological markers of GBC. Imaging plays a key role not only in diagnosis and staging but also in prognostication. Ultrasound (US) is the initial test of choice that allows risk stratification in wall thickening and polypoidal type of gallbladder lesions. US findings guide further investigations and management. Computed tomography (CT) is the test of choice for staging GBC as it allows comprehensive evaluation of the gallbladder lesion, liver involvement, lymph nodes, peritoneum, and other distant sites for potential metastases. Magnetic resonance imaging (MRI) and magnetic resonance cholangiopancreatography allow better delineation of the biliary system involvement. Contrast-enhanced US and advanced MRI techniques including diffusion-weighted imaging and dynamic contrast-enhanced MRI are used as problem-solving tools in cases where distinction from benign lesion is challenging at US and CT. Positron emission tomography is also used in selected cases for accurate staging of the disease. In this review, we provide an up-to-date insight into the role of imaging in diagnosis, staging, and prognostication of GBC.

Keywords

- ▶ artificial intelligence
- ▶ computed tomography
- ▶ deep learning
- ▶ gallbladder cancer
- ▶ magnetic resonance imaging
- ▶ ultrasound

Introduction

Gallbladder carcinoma (GBC) is the most common biliary tract malignancy, with a distinct geographic and demographic distribution.¹ It carries a dismal prognosis when diagnosed at an advanced stage, with a reported 5-year

survival rate of less than 5% in stage III or IV tumors.² There are several histological subtypes, with 90% of the cases being epithelial origin adenocarcinoma.^{3,4} GBC typically arises as a mucosal lesion, involving a part or the entire wall of the gallbladder (GB). There is a tendency for early invasion and

DOI <https://doi.org/10.1055/s-0044-1789243>.
ISSN 0971-3026.

© 2024. Indian Radiological Association. All rights reserved.
This is an open access article published by Thieme under the terms of the Creative Commons Attribution-NonDerivative-NonCommercial-License, permitting copying and reproduction so long as the original work is given appropriate credit. Contents may not be used for commercial purposes, or adapted, remixed, transformed or built upon. (<https://creativecommons.org/licenses/by-nc-nd/4.0/>)
Thieme Medical and Scientific Publishers Pvt. Ltd., A-12, 2nd Floor, Sector 2, Noida-201301 UP, India

rapid pathological progression due to the lack of muscularis mucosa and submucosa in the GB wall.⁵ This is especially seen along the adjacent hepatic surface, where the connective tissue of the GB is continuous with the interlobular connective tissue of the liver.

Clinical presentation is often vague with nonspecific signs and symptoms, contributing to an unresectable disease status at the time of initial diagnosis.⁶ Imaging plays an essential role in the management of GBC. However, it may be challenging to detect early GBC due to nonspecific imaging features that may overlap with other benign GB lesions.^{7,8} Furthermore, appropriate interpretation of the imaging findings is essential for accurate staging, thus guiding the overall surgical extent and management plan. Recent advancements in various imaging techniques have broadened the horizon of the role of preoperative imaging in patients with GBC. Additionally, with the advent of radiomics, radiogenomics, and artificial intelligence (AI) in the field of medical imaging, breakthrough advances have taken place in the application of imaging for not only detecting the GBC but also for molecular characterization, prognostication, and predicting the overall course of the disease.^{9,10} This article reviews the updated role of imaging in the diagnosis, staging, and prognostication of the GBC.

Morphological Types of Gallbladder Carcinoma

Traditionally, three morphological subtypes of GBC have been identified: mass-replacing GB, wall thickening, and intraluminal polypoid type of GBC, of which mass-replacing GB is the most common subtype (→Figs. 1–3).⁸ Recently, a fourth morphological pattern, a combined type of GBC, with imaging features of both mass-type and thickening-type GBC (→Fig. 4), has been described.¹¹ The morphological type of GBC has diagnostic implications as well as dictates the pattern of spread and overall prognosis of the patient.

Mass-replacing the normal GB lumen, or the GB fossa, accounts for 40 to 70% of all GBC cases.⁸ Compared to other forms of GBC, these tumors are typically easier to recognize and exhibit early invasion of neighboring tissue.¹² On transabdominal ultrasound (US), they present as a large hetero-

geneous, ill-margined masses, with or without internal vascularity, with normal GB not separately visualized. Associated gallstones, tumoral or wall calcifications, and liver, biliary, and vascular involvement may be seen. Additionally, discrete liver metastasis, omental, and peritoneal disease can be visualized. On computed tomography (CT), they typically appear as poorly marginated hypodense masses with heterogeneous enhancement and areas of necrosis in larger tumors.^{8,12,13} Up to 40% of the lesions show hypervascular foci of enhancement equal to or greater than that of the liver. On magnetic resonance imaging (MRI), they usually show heterogeneous high signal intensity on T2-weighted (W) images, and low to isointense signal intensity on T1-W images with diffusion restriction and heterogeneous enhancement.^{2,12,14,15} There may be delayed retention of contrast in the areas of fibrosis. Moreover, cross-sectional imaging clearly defines the disease's distant and locoregional spread.

Wall thickening is a nonspecific manifestation of various local GB pathologies as well as systemic diseases. Accurate characterization of GB wall thickening is often challenging, especially in subacute to chronic clinical presentations.¹⁶ Twenty to 30% of all GBC cases manifest as wall thickening on imaging.⁸ They are often misdiagnosed as benign lesions, present at a later stage, and have a higher propensity for perineural invasion and involvement of porta hepatis.

Focal, asymmetric mural thickening, with loss of integrity of the mucosa and a loss of layered appearance typically favors a malignant over a benign cause of GB wall thickening.^{15,16} Lack of intramural features (echogenic foci or intramural nodules) and an indistinct interface with adjacent liver parenchyma are also more commonly encountered with GBC. This is in contrast to benign thickening, which typically has a preserved layered appearance and distinct interface with the liver. A useful sign, "cervix-sign," has been described in association with malignant GB wall thickening involving the neck region, which is a potentially challenging area to evaluate.¹⁷ On CT, malignant wall thickening is typically irregular and asymmetric, with an indistinct interface with the adjacent liver parenchyma.^{15,18} Various types of enhancement patterns have been described in the literature for the characterization of GB wall thickening. Kim et al

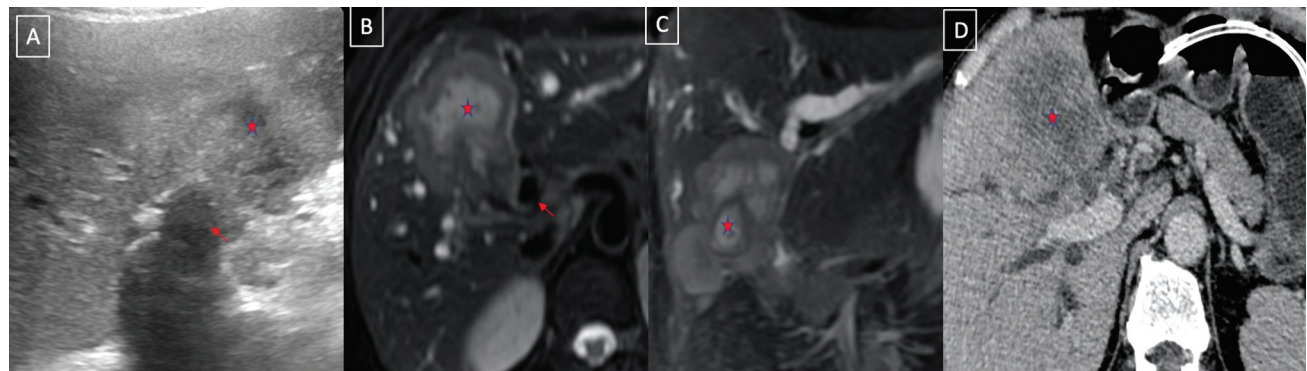


Fig. 1 Mass-forming type of gallbladder cancer. Grayscale ultrasound (A), axial (B) and coronal (C) T2-weighted magnetic resonance imaging, and axial computed tomography (D) images showing the mass-forming type of gallbladder cancer (asterisk) replacing the normal gallbladder, infiltrating into the adjacent liver and biliary radicles.

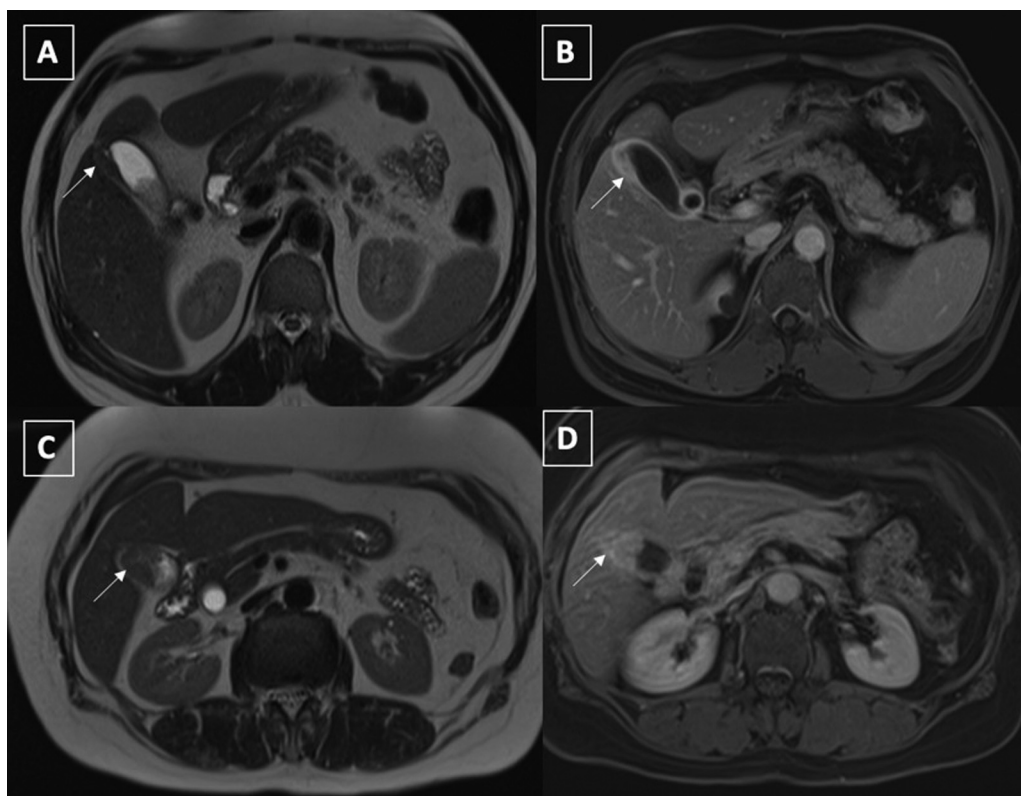


Fig. 2 Axial T2-weighted (A) and postcontrast T1-weighted (B) images of a 54-year-old male with IgG4 cholecystitis showing focal mural thickening involving the gallbladder fundus with preserved mural stratification (arrows, A, B). Axial T2-weighted (C) and postcontrast T1-weighted (D) images of a 50-year-old lady with gallbladder carcinoma showing single-layered heterogeneous enhancement of focal thickening involving the fundus of the gallbladder (arrows).

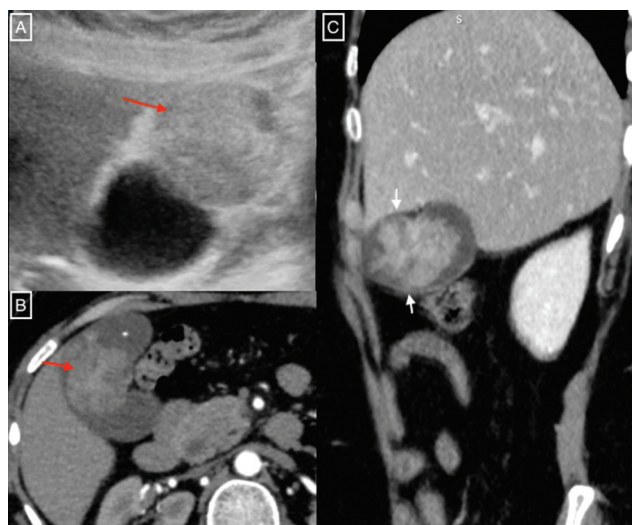


Fig. 3 A 45-year-old female with malignant polypoidal gallbladder lesion (biopsy-proven adenocarcinoma of the gallbladder). Grayscale ultrasound image shows the echogenic polypoidal lesion within the gallbladder lumen (A). Axial contrast-enhanced computed tomography image shows heterogeneous contrast enhancement of the polypoidal lesion (B). Note the lesion is confined within the gallbladder lumen (arrow, C).

identified five patterns of mural enhancement in diffuse wall thickening. Two-layered patterns with strong enhancement of the thick inner layer and weak enhancement of the outer layer and single-layered pattern with a heterogeneously

enhancing wall favored malignant GB wall thickening.¹⁹ Corwin et al described six different enhancement patterns in focal GB wall thickening, with enhancement of the entire focal fundal thickening and heterogeneous enhancement of the focal fundal thickening without discrete cystic spaces, suggesting malignant cases.²⁰ This is in contrast to benign causes of GB wall thickening, which typically show a continuous mucosal line and intramural features (cysts and/or nodules) with a preserved interface with the liver.

On MRI, malignant GB wall thickening shows heterogeneous T2-W hyperintense/T1-W hypointense to isointense signal intensity with nodular thickening and loss of layered appearance.² Furthermore, the presence of patchy, inhomogeneous, intense diffusion restriction favors malignant wall thickening and typically has lower apparent diffusion coefficient (ADC) values. The presence of T1-W hyperintensity within the wall of GB, or lumen, and the “T2 necklace sign” favored benign GB wall thickening.²¹ As with mass-forming GBC, the presence of extramural invasion and biliary and vascular involvement is characteristically seen in malignant GB wall thickening.²

While the vast majority of GB polyps are benign, the intraluminal polypoid type of GBC constitutes an important morphological subtype of GBC as they are usually well-differentiated and often incidentally detected, thus carrying a better prognosis. They account for 15 to 25% of all the cases of GBC.⁸ Malignant GB polyps tend to be larger (> 1 cm) and more heterogeneous as compared to the benign

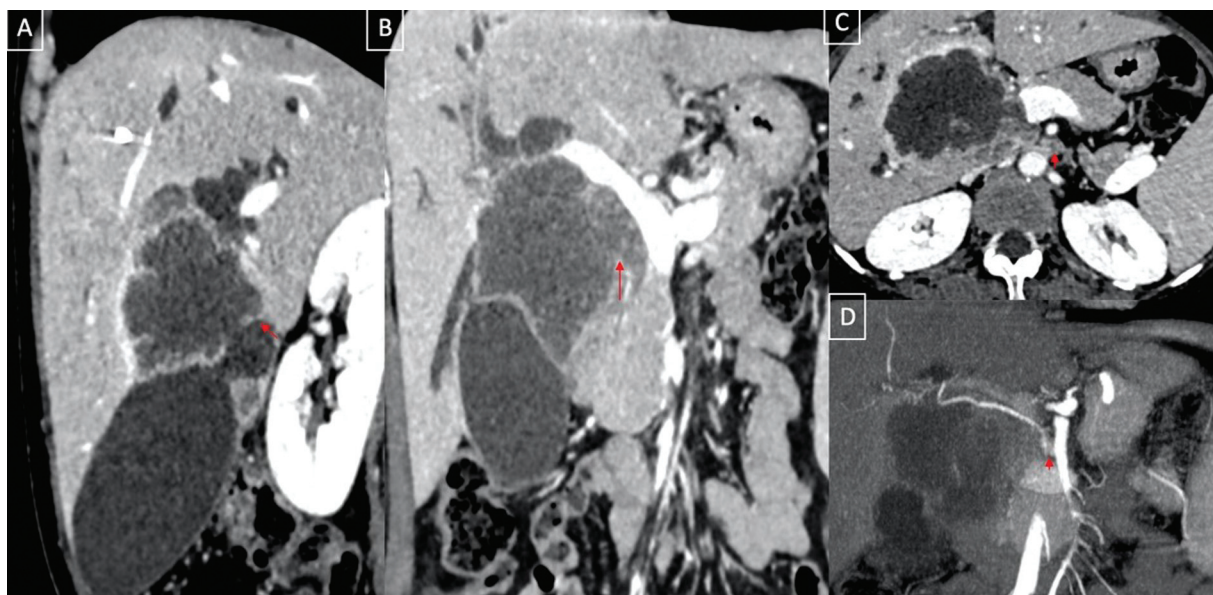


Fig. 4 A 42-year-old with combined type of gallbladder cancer. Sagittal (A) and coronal (B) reformatted contrast-enhanced computed tomography images show the asymmetrical mural thickening involving the body and neck of gallbladder with a peripherally enhancing mass in contiguity with the thickening extending into the adjacent liver parenchyma. Note the necrotic periportal lymph nodes (arrow, C) and replaced right hepatic artery encased within the mass (D). Depiction of the exact locoregional extent including the vascular anatomy is crucial for surgical planning and staging of the disease which is well depicted with contrast-enhanced computed tomography and its multiplanar capabilities.

counterparts.^{22,23} Sessile morphology with a nodular surface is another sinister feature.^{12,15} In contrast to intraluminal tumefactive sludge, they typically do not change in position and show internal vascularity on color Doppler US. While US suffices in most cases of GB polyps, cross-sectional imaging may be helpful in equivocal cases. Similar morphological features, along with hyperenhancement, have been described on CT and MRI, favoring malignant over benign GB polyps. Additionally, cross-sectional imaging more readily depicts the extraluminal spread in cases of malignant polyps.^{2,12,15}

The fourth pattern, combined type, shows imaging features of both the thickening type and the mass-replacing GB, posing a unique diagnostic dilemma. Although the morphological features are similar to mass-replacing GB, it characteristically grows exophytically into the liver parenchyma rather than replacing the GB. If the GB wall thickening is missed, this lesion may be misdiagnosed as a primary or metastatic liver lesion. A greater chance of liver metastases in combined-type GB has been described in comparison to other morphological types.¹¹

Gallbladder Carcinoma Spread

GBC disseminates via multiple pathways. Direct invasion into adjacent organs is the most common mode. Predominantly, the liver (65%) is involved by direct invasion, followed by the large bowel and the small bowel (15%).¹² Lymphatic vessels serve as conduits for tumor cell migration, facilitating metastasis to regional and distant lymph nodes. Lymphatic invasion occurs frequently (35–75%), especially through the pericholecystic lymphatics and follows distinct drainage

routes including the cholecysto-retropancreatic, cholecysto-celiac, and cholecysto-mesenteric pathways, ultimately converging at the retroperitoneal lymph nodes.^{8,24} Liver metastases can also occur through lymphatic (along Glissonian pedicles) or hematogenous (via the cystic vein into the liver parenchyma) routes. High prevalence of perineural invasion can be attributed to the rich autonomic innervation of the GB and biliary tract. This mode of spread is frequent with high-grade GBC which contributes to challenges in achieving curative resections and heightens the risk of early recurrence.⁷

Distant metastases in GBC are mostly via hematogenous spread, which predominantly afflict the liver, peritoneum, and lungs (2,7,24). Uncommon metastatic sites including the ovaries, bone, brain, vertebra, cheek, and heart, have been documented.^{25–30}

Understanding these diverse mechanisms of spread is crucial for elucidating the intricate pathophysiology of GBC and informing clinical management strategies.

Imaging Techniques

Ultrasound

US is the initial imaging technique for the evaluation of patients with suspected GB pathologies.³¹ Some of the key benefits of the US include easy availability, cost-effectiveness, lack of ionizing radiation, and the real-time dynamic nature. US findings guide further investigations. The reported sensitivity and accuracy in the diagnosis of locally advanced GBC are 85 and 80%, respectively.³² However, the sensitivity of the US for the detection of GB lesions is governed by several patient-related and technical factors.

Table 1 GB-RADS category and lexicon

GB-RADS score	Risk category (probability of malignancy)	Lexicon descriptors	Management
0	Inadequate evaluation due to technical or patient factors or gallbladder-related factors (N/A)	Morbid obesity Wall-echo-shadow complex Porcelain gallbladder Gas in the gallbladder lumen	Repeat ultrasound in selected cases. Consider multiphasic contrast-enhanced CT/MRI after multidisciplinary discussion
1	Normal	Adequate gallbladder distension Wall thickness \leq 3 mm	No additional imaging or follow-up
2	Benign (< 2%)	Symmetric circumferential thickening with or without intramural changes or focal thickening with intramural changes Layered appearance	No additional imaging or follow-up needed
3	Equivocal (2–50%)	Circumferential thickening without layered appearance Focal thickening without intramural features (cysts or echogenic foci) or layered appearance Distinct interface with liver	Consider multiphasic contrast-enhanced CT/MRI after multidisciplinary discussion
4	Malignancy is likely (50–90%)	Circumferential or focal thickening without layered appearance and with loss of interface with liver	Multiphasic contrast-enhanced CT/MRI
5	Malignancy is highly likely (> 90%)	Same as GB-RADS 4 with definite extramural invasion as suggested by one of the following: Biliary or vascular involvement by direct extension of mural thickening Liver mass in contiguity with the mural thickening	Multiphasic contrast-enhanced CT/MRI

Abbreviations: CT, computed tomography; GB-RADS, gallbladder reporting and data system; MRI, magnetic resonance imaging; N/A, not applicable. Note: Modified from Gupta et al.³⁴

In fact, a few studies report poor sensitivity of the US even for advanced disease.¹³ This is particularly true for the wall-thickening type of GBC, which is often challenging to diagnose.³³ A new stratification system, the GB reporting and data system (GB-RADS), has been formulated for risk stratification of GB wall thickening on US, with the intent to increase the accuracy of detection of malignant lesions (► **Table 1** and ► **Fig. 5**).³⁴ A single-center multireader validation study for assessing the performance of GB-RADS has shown promising results; however, further larger multicenter studies are needed for testing its accuracy for wider clinical utilization.³⁵ Few other studies have evaluated the diagnostic performance of GB-RADS combined with other advanced US techniques. Wang et al combined color Doppler with GB-RADS for GBC detection. They reported that the sensitivity and accuracy of GB-RADS was 82.5 and 83.8% while that of GB-RADS combined with color Doppler was 96.2 and 95.2%, respectively.³⁶ Boccatonda et al also proposed that the diagnostic performance of contrast-enhanced US (CEUS) combined with GB-RADS may be better than GB-RADS alone.³⁷ Zhu et al compared GB-RADS with multiparametric high frame rate CEUS for characterization of GB wall thickening and reported better accuracy of high frame rate CEUS in comparison to GB-RADS.³⁸

GB polyps are commonly seen on US. Most polyps are benign. However, distinguishing benign and malignant polyp is critical. Although the US remains the primary investigative modality for evaluating polypoidal lesions of GB, it has a higher false-positive rate, leading to unnecessary cholecystectomies. A systematic review by Martin et al which included 14 studies with a total of 1,259 patients with polyps, reported a false positive rate of 85.1% for the diagnosis of true GB polyps when compared with pathological findings, although their results may be biased by relative lack of the size criteria and homogeneity of the included studies.³⁹ Pickering et al also reported a low positive predictive rate of only 4.5% for detecting neoplastic GB polyps.⁴⁰ Similar studies by Li et al⁴¹ and Metman et al⁴² found false positive rates of 72.5 and 95.4%, respectively.

Despite these shortcomings of the US, it is still the preferred imaging modality for detection and risk stratification of GB polyps.^{22,23} In a recent expert consensus conference, the Society of Radiologists in Ultrasound provided recommendations for the management of incidentally detected GB polyps at US.²³ On the basis of their morphologic features and size, GB polyps are stratified into three categories. The morphological features that characterize extremely low-risk polyps include a pedunculated polyp with a “ball-on-the-wall” configuration or thin stalk. Low-risk polyps are

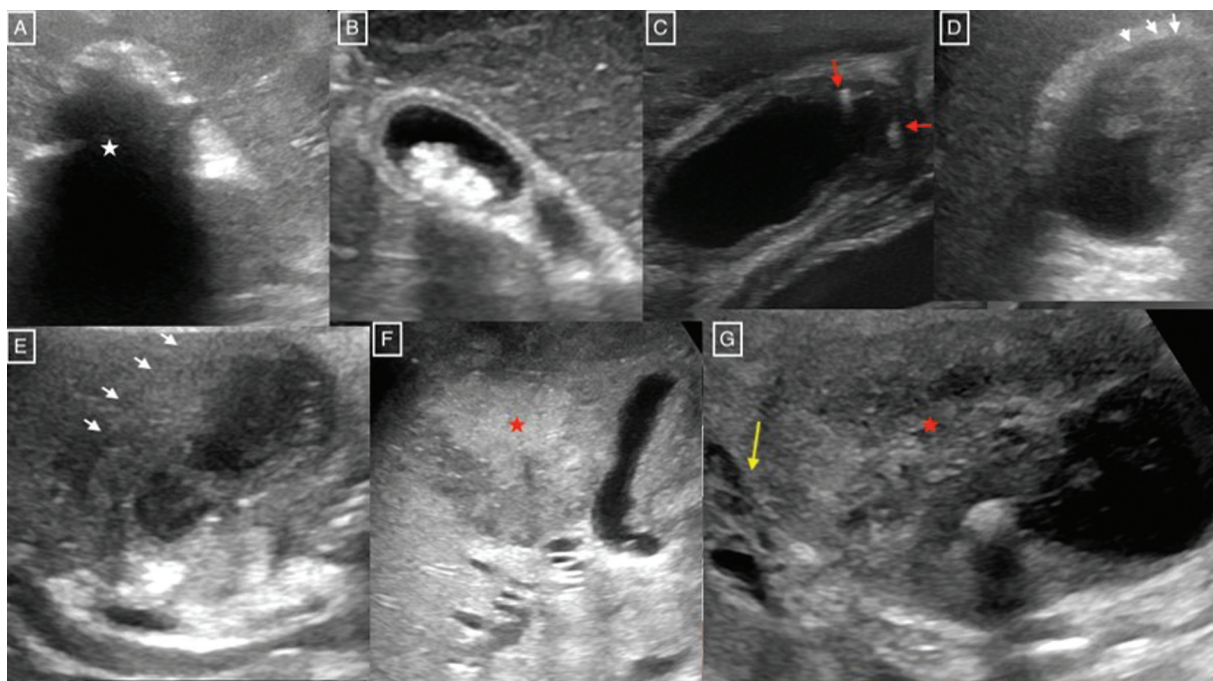


Fig. 5 Transabdominal ultrasound images showing various categories of gallbladder reporting and data system (GB-RADS). (A) GB-RADS 0–Wall echo-shadow complex (asterisk) limiting adequate evaluation of the gallbladder wall. (B) GB-RADS 2–Symmetric circumferential mural thickening with layered appearance and cholelithiasis suggestive of typically benign thickening. (C) GB-RADS 2–Typical benign gallbladder wall thickening with intramural echogenic foci (arrow). (D) GB-RADS 3–Focal thickening without intramural features or layered appearance and preserved interface with liver (white arrow). (E) GB-RADS 4–Asymmetric circumferential mural thickening without layered appearance and with loss of interface with liver (white arrow). (F and G) GB-RADS 5–Asymmetric circumferential mural thickening without layered appearance, loss of interface with liver, and associated liver mass contiguous with mural thickening (asterisk). Note the biliary involvement by the mass (G, arrow).

pedunculated with a thick or wide stalk or have a sessile configuration and intermediate-risk polyps have focal wall thickening adjacent to the polyp. The management and follow-up recommendations for each category are based on the premise that most malignant polyps are larger and grow faster than most nonmalignant polyps.

In comparison to conventional US, high-resolution US has a higher diagnostic accuracy for differentiating benign and malignant GB wall thickening, GB polyps, and assessing the depth of invasion.^{16,43} Detailed evaluation of the GB wall features is crucial for accurate risk stratification, which is achievable with high-resolution US and using advanced techniques like harmonic imaging. A systematic review by Rana et al highlights the importance of detailed evaluation of the GB wall for risk stratification in a nonacute setting.¹⁶ They found presence of echogenic foci, lack of wall disruption, and hypoechoic nodules as features favoring benign thickening with a sensitivity of 89, 77, and 66%, respectively, and specificity of 86, 51, and 80%, respectively. Focal thickening and indistinct interface with liver had a sensitivity of 75 and 55%, respectively, and specificity of 64 and 69%, respectively, for the diagnosis of malignant wall thickening.

Color Doppler Ultrasound

Numerous studies have assessed the value of color Doppler in differentiating benign and malignant GB lesions.^{44–48} Hayakawa et al reported a mean peak flow velocity of 49.4 ± 12.6 cm/s in patients with GBC versus the control nonneoplastic group, in which the mean peak flow velocity varied between

11.5 ± 2.6 and 28.6 ± 4.6 cm/s.⁴⁷ Li et al demonstrated a higher mean blood flow velocity of 35.8 ± 7.67 cm/s in GBC versus benign lesions.⁴⁸ Pradhan et al also found an improved detection rate of GBC with the addition of color Doppler to US.⁴⁴ Lower resistive index and higher peak systolic velocity in malignant GB polyps in comparison to benign GB polyps have been reported.⁴⁹ Although, the detection of color flow within the lesion supports GBC, its absence does not exclude it. Moreover, accurate quantification of color flow may be technically challenging.⁵⁰

Shear Wave Elastography

Limited number of studies have evaluated the role of shear wave elastography (SWE) in differentiating between benign and malignant GB wall thickening (► Fig. 6).^{51–53} Soundararajan et al reported a shear wave velocity of 34.99 ± 17.77 kPa in an abnormal area of GB in GBC, while velocity was 18.27 ± 8.12 kPa in an uninvolved region of GB.⁵² These values were significantly higher as compared to those of the benign group (12.27 ± 4.13 kPa) and the control group (10.52 ± 3.75 kPa). Kapoor et al reported a sensitivity of 100% and a specificity of 91.3% for diagnosing GBC at the cutoff elastography value of 2.7 m/s.⁵³ Despite promising results in these studies, the precise clinical utility and technical feasibility of SWE for evaluating GBC is yet to be fully explored.

Contrast-Enhanced Ultrasound

There has been a growing interest in CEUS for the diagnosis and characterization of GB lesions. A systematic review and meta-

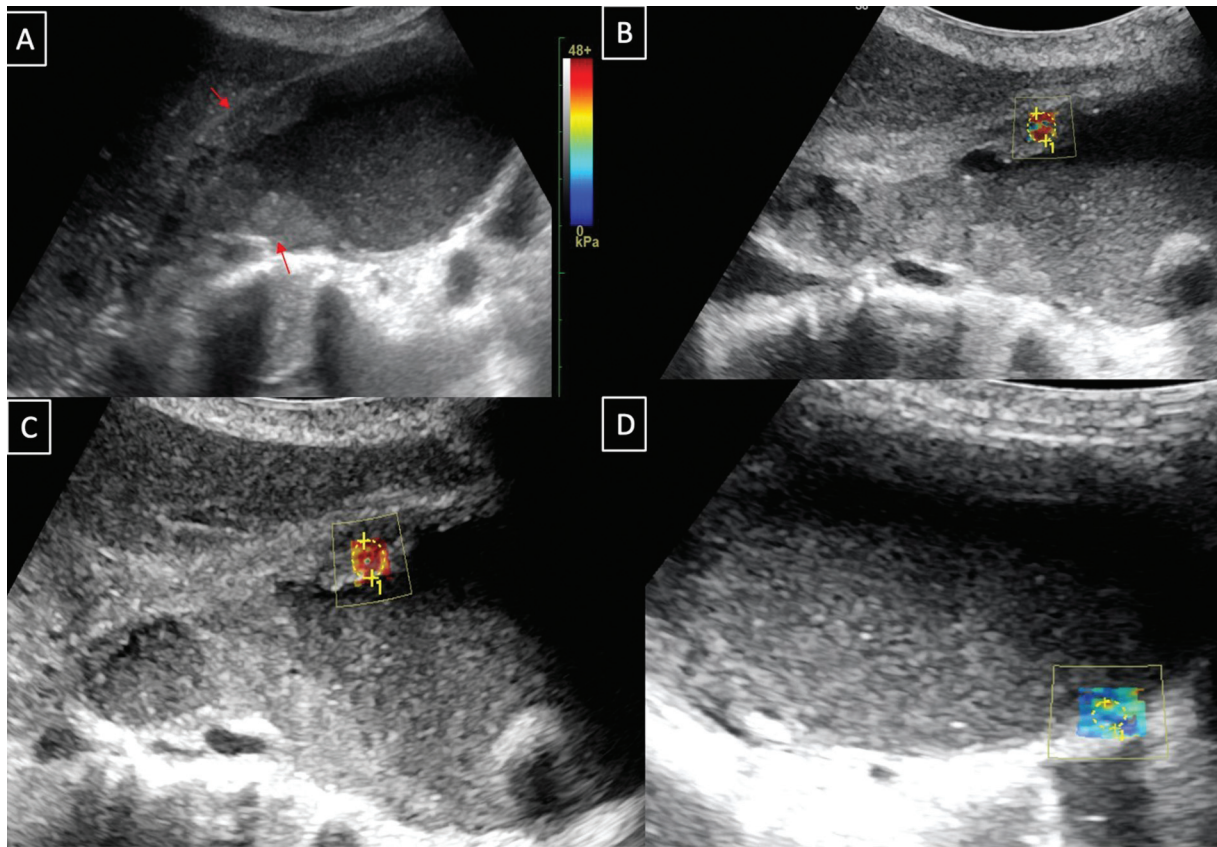


Fig. 6 Transabdominal ultrasound grayscale image (A) of a 56-year-old female with malignant gallbladder wall thickening involving the body and neck region (arrow). There were significantly elevated elastography values in the involved wall (43.85–43.98 kPa) (B, C) as compared to the uninvolved wall (6.78 kPa) (D).

analysis by Cheng et al found CEUS as a promising tool for differentiating benign and malignant GB lesions (pooled sensitivity and specificity of 0.81).⁵⁴ Comparing CEUS to conventional US, Zhang et al⁵⁵ and Numata et al⁵⁶ found significantly higher sensitivity, specificity, and diagnostic accuracy for distinguishing various GB pathologies. Dong et al reported the association of several CEUS features like arterial-phase irregular intralesional vascularity, late-phase hypoenhancement, destruction of the GB wall, and infiltration of the adjacent liver with GBC.⁵⁷ Boddapati et al found disruption of GB wall, intralesional non-enhancing areas, liver involvement, and arterial phase hyper-enhancement to be significantly associated with malignant lesions.⁵⁸ Similar CEUS features supporting GBC over benign diseases were reported by a number of other studies, including a meta-analysis by Wang et al.^{59–61}

Several studies have reported the promising role of CEUS in identification of malignant GB wall thickening.^{62–65} Focal thickening, discontinuity of outer and inner layers, increased vascularity, branched or linear intralesional vessels, early washout time of 40 second or less, and inhomogeneous and early hypoenhancement favor malignant GB wall thickening. In a study by Yuan et al, CEUS was found superior to the conventional US for differentiation of GBC from xanthogranulomatous cholecystitis (XGC). The continuous inner wall, hypoenhancement time of more than 80.5 seconds, diffuse GB wall thickening and enhancement, and intramural hypo-echoic nodules were the pointers toward nonmalignant wall

thickening.⁶³ Tang et al also reported better demonstration of intact GB wall and nonenhancing “Rokitansky–Aschoff sinuses” for diagnosing adenomyomatosis with CEUS.⁶⁴

CEUS is also a problem-solving tool for differentiation of sludge from soft tissue by demonstration of perfusion within the soft tissue. In the presence of calculi, the enhancing soft tissue may be better appreciated as compared to conventional US.⁶⁶

Promising findings have also been found in studies assessing the utility of CEUS in GB polyp characterization.^{67–71} In a study of 93 patients, the presence of CEUS imaging findings such as irregular vessel patterns and perfusion defects yielded 94% sensitivity and 93% specificity for diagnosing malignant GB polyps.⁶⁷ Similar results were shown by Miwa et al, who used dilated irregular vessels and heterogeneous enhancement within the polyp as diagnostic criteria for malignant GB polyps.⁷⁰

Computed Tomography

Contrast-enhanced computed tomography (CECT) is currently the workhorse for the evaluation of patients with suspected GBC. With its multiplanar reconstruction ability and various postprocessing techniques, CT allows precise and comprehensive anatomical delineation, accurate tumor and future liver remnant volume computation, and vascular map generation, which are crucial for surgical planning.¹³ It has an accuracy of 83.9, 85, and 100% in determining the local extent, predicting resectability, and determining the hepatic

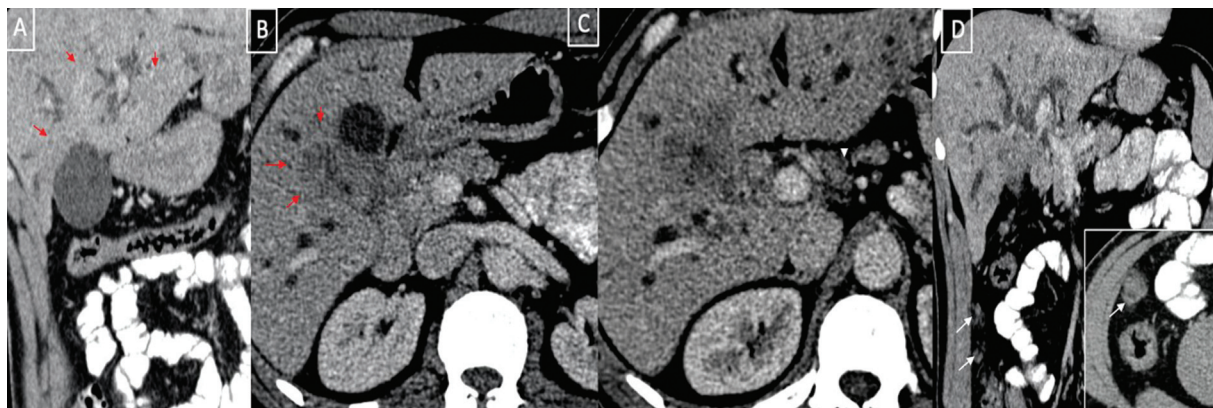


Fig. 7 Multiplanar reformatted contrast-enhanced computed tomography image of a 56-year-old male with malignant gallbladder wall thickening. Sagittal (A) and axial (B) images show the ill-margined hypoenhancing mural thickening involving the neck of the gallbladder infiltrating into the adjacent liver parenchyma causing biliary radicals cutoff with resultant intrahepatic biliary radical dilatation. Axial (C) and coronal (D) images show the extent of the disease with periportal lymphadenopathy (arrowhead, C) and omental nodules (arrow, D).

and vascular invasion, respectively.^{13,72,73} The optimal CT protocol involves multiphase acquisition in the arterial and portal venous phases. In cases of suspected gastric or duodenal obstruction due to local spread, one may administer positive oral contrast. While US is still superior in depicting subtle mucosal irregularities and gallstones, CT provides more accurate assessment of the depth of invasion and depiction of the entire tumor burden (►Fig. 7).^{60–62,74,75}

The accuracy of CT may also vary depending on the stage and type of tumor. According to Kim et al, the overall accuracy of CT for staging GBC was 71%; it was 79% for T1 and T2 tumors, 46% for T3 tumors, and 73% for T4 tumors. Furthermore, they reported a lower overall accuracy for staging wall-thickening types of GBC in comparison to mass-forming and polypoidal types of GBC.⁷³ A study by Kalra et al reported similar results.¹³ While dual-energy CT (DECT) has been extensively studied to evaluate gallstones, limited studies report its role in the evaluation of GBC (►Fig. 8). Pruthi et al found that lower KeV data sets and iodine maps performed better for characterizing GB wall thickening, with malignant GB thickening being associated with increased iodine uptake.⁷⁶ Another recent prospective study reported DECT to be useful in a subset of patients with GB wall thickening to differentiate XGC from GBC.⁷⁷

Magnetic Resonance Imaging

MRI is being increasingly used for the evaluation of suspected GBC and as a problem-solving tool.² Owing to its higher soft tissue contrast resolution and better ability to depict biliary anatomy, it facilitates more accurate delineation of early-stage GBC and the disease extent assessment. Magnetic resonance cholangiopancreatography (MRCP), diffusion-weighted imaging (DWI), and post-gadolinium dynamic contrast-enhanced imaging (DCE-MRI) are included in the MRI protocol, besides routine T1-W and T2-W sequences.²

MRI has a better sensitivity in comparison to CT for detecting adjacent hepatic invasion (reported sensitivity of 85.7–100%) and nodal metastasis (reported sensitivity of 92%; ►Fig. 9).^{2,78} Kim et al, in their study on 86 patients with proven GBC, reported an accuracy of 84% for MRI com-

prising MRCP and DCE sequences.⁷⁹ The sensitivity of MRI with MRCP was shown to be 100% for hepatic invasion and 92% for nodal involvement in another retrospective study by Schwartz et al.⁸⁰ The use of DWI can be potentially helpful in differentiating GBC from benign polyps.^{81,82} Yoshioka et al found considerably lower ADC levels in the GBC than adenomas.⁸³ Kim et al reported a lower mean ADC value of $1.46 \pm 0.45 \times 10^{-3} \text{ mm}^2/\text{s}$ in the GBC group versus $2.16 \pm 0.56 \times 10^{-3} \text{ mm}^2/\text{s}$ in the cholecystitis group.⁸⁴ Kitazume et al demonstrated better specificity and accuracy when combining DWI with suspicious morphological features for differentiating benign and malignant GB lesion on MRI.⁸⁵ DWI also adds to the detection of liver, peritoneal, and lymph nodal metastasis.^{2,80,81} Recent studies have also reported the value of ADC in predicting tumor differentiation and prognosis after surgery.^{86,87} MRI has also been found superior to CT in the characterization of GB wall thickening. A study by Kalage et al reported superior performance of MRI over CT in the characterization of wall thickening. At MRI, heterogeneous enhancement, indistinct interface with liver, and diffusion restriction were significantly associated with malignancy, while the intramural cysts favored a benign lesion.⁸⁸

With DCE-MRI, the lesion can be characterized better and the liver parenchyma can be assessed for tumor infiltration and metastatic disease.² Heterogeneous single-layered enhancement patterns and two-layered enhancement patterns with thick inner layers favor malignant thickening (►Fig. 5).⁶⁵ Studies by Takashima et al and Kalage et al reported a steeper time intensity curve in GBC.^{89,90} Yoshimatsu et al studied the role of DCE in differentiating GB polyps. They reported that malignant GB polyps tend to demonstrate early, prolonged enhancement without washout on MR, compared to benign polyps.⁹¹

In a recent work by Kalage et al, utility of multiparametric MRI for characterizing GB wall thickening was evaluated. They used quantitative sequences (DCE-MRI, intravoxel incoherent motion [IVIM], and diffusion tensor imaging [DTI]) in addition to conventional MRI sequences (that included DWI). Compared to conventional MRI, multiparametric MRI had a better sensitivity for detecting malignancy in GB wall thickening. Between the

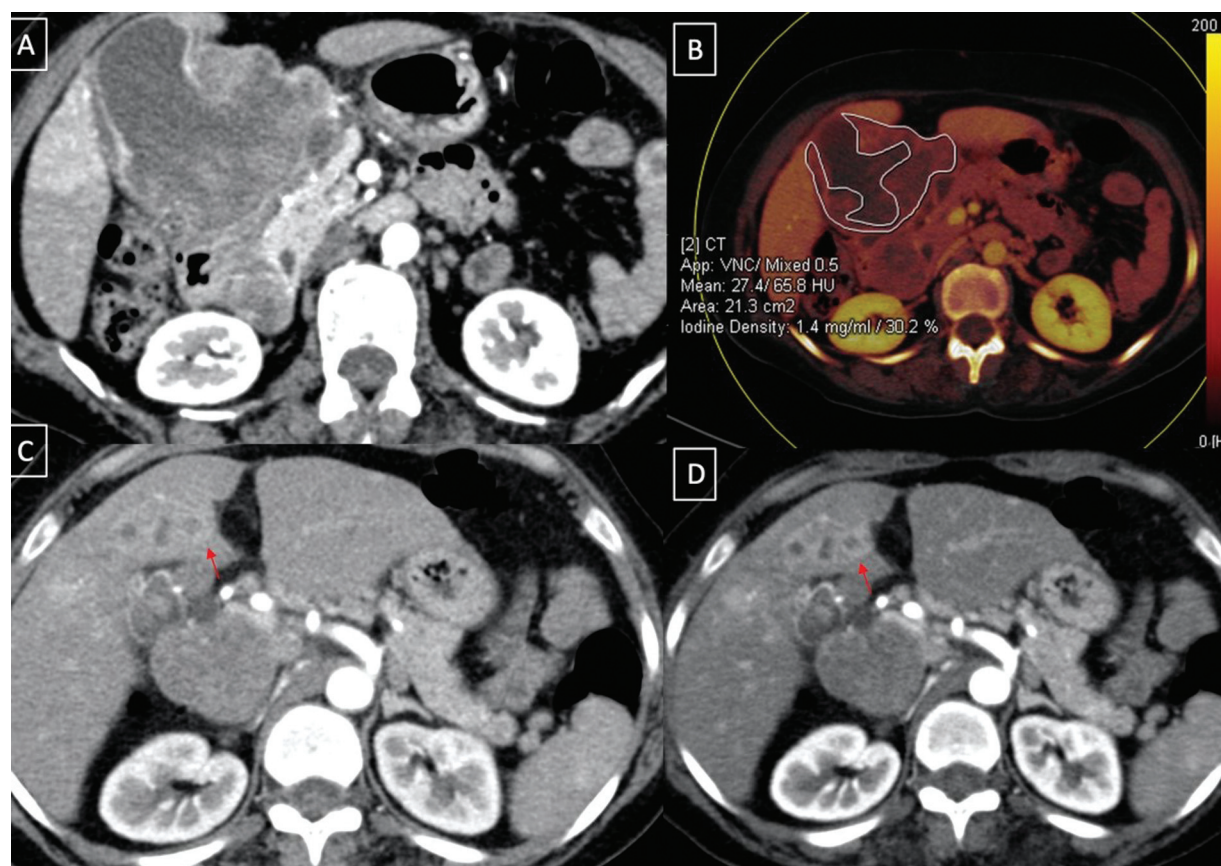


Fig. 8 Dual-energy computed tomography for malignant gallbladder mass. Axial images (A, B) show the heterogeneously enhancing gallbladder mass with increased iodine uptake. The discrete liver lesions were less conspicuous on higher energy (140 keV) image as compared to lower energy (80 keV) image which has a higher contrast resolution.

benign and malignant groups, there were significant differences in the quantitative MRI parameters (time-to-peak enhancement in DCE-MRI, mean diffusivity in DTI, and perfusion fraction in IVIM). Despite these advantages, multiparametric MRI could not differentiate XGC from GBC.⁹⁰

Positron Emission Tomography

Although CT is still the most often used diagnostic method for evaluating GBC, few have shown that F-18 fluorodeoxyglucose (FDG)-positron emission tomography (PET) is a helpful imaging modality for GBC.^{92–95} For the diagnosis of GBC, a meta-analysis revealed sensitivity of 87% and a specificity of 78% of FDG-PET.⁹² Parida et al reported a pooled sensitivity of 96, 95, and 75% for nodal disease, metastatic disease, and local disease extent, respectively.⁹⁵ However, its usefulness may be limited because benign GB diseases may also exhibit FDG uptake. Pericleous et al demonstrated that GBC could not be reliably confirmed by FDG-PET CT.⁹³ Currently, it is still less frequently utilized for primary GBC diagnosis and more frequently for staging, assessing treatment response, and identifying tumor recurrence and occult metastases.

Staging

GBC staging has evolved through the adoption of the American Joint Committee on Cancer (AJCC) system, now employing the

8th edition since January 1, 2018.⁹⁶ It utilizes the TNM staging system which assesses the three primary factors: the extent of tumor spread based on tumor size (T), lymph node involvement (N), and distant metastasis (M; ▶ **Table 2**).

Tumor invasion depth (T) remains pivotal in determining suitable surgical approaches for potentially resectable tumors. Notably, the 8th edition introduces a refined classification of T2 tumors (confined to the GB wall), distinguishing between T2a and T2b based on peritoneal and hepatic side involvement, respectively.⁹⁶ This approach acknowledges differing tumor behaviors and prognostic implications. Studies have underscored distinct rates of vascular and neural invasion and nodal metastases between T2a and T2b tumors, advocating for potential adjuvant therapies in T2b tumors owing to their heightened metastatic potential.⁹⁷ In the AJCC 8th edition, lymph nodes >10 mm along the hepatoduodenal ligament are categorized as N1 or N2 based on the number of involved nodes. Number rather than location of the positive nodes emerges as a prognostic determinant.⁹⁸

Role of Imaging in GBC Staging

Endoscopic Ultrasound

Endoscopic US (EUS) allows precise T staging as it demonstrates the layered structure of the GB wall. EUS is also useful for N staging of GBC specifically for assessment of celiac and aortocaval nodes.^{99–101}

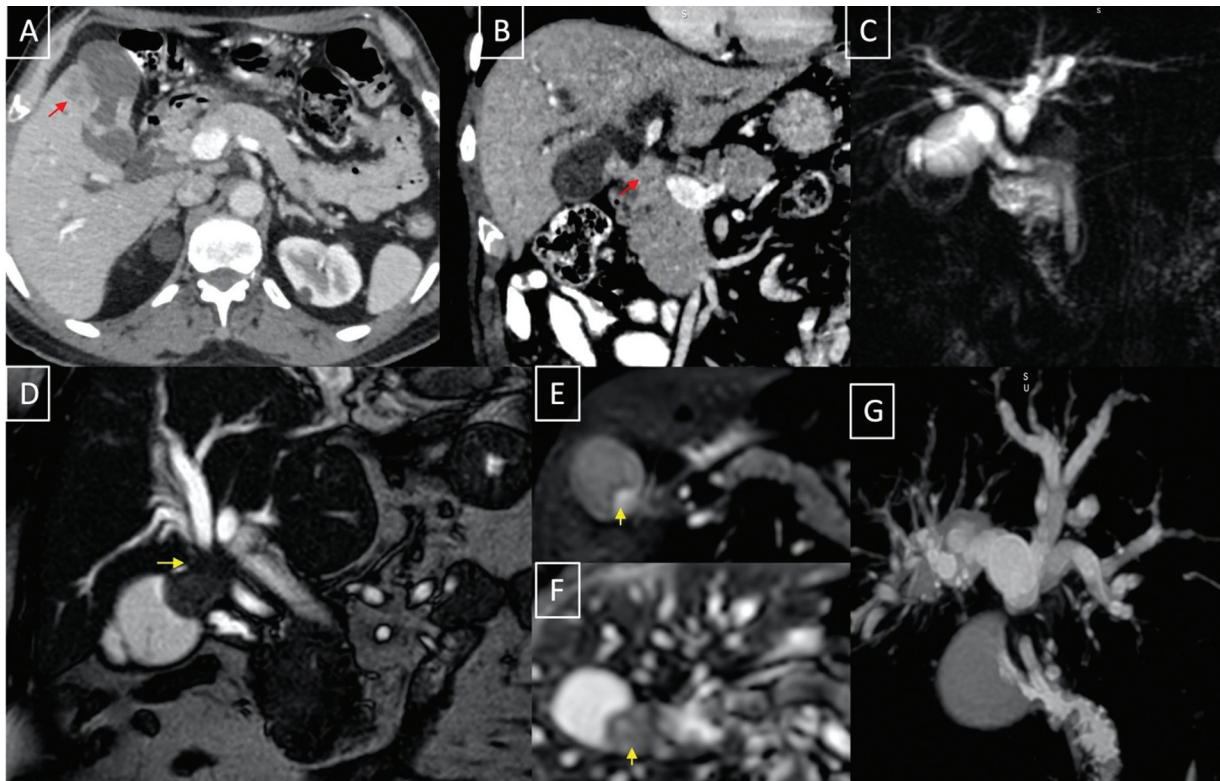


Fig. 9 Magnetic resonance cholangiopancreatography (MRCP) depiction of detailed biliary involvement in gallbladder cancer. Axial (A) and coronal (B) computed tomography images show the asymmetric mural thickening of the gallbladder with infiltration into the adjacent liver parenchyma (arrow, A) and periportal lymphadenopathy (arrow, B) causing biliary cutoff, just below the primary confluence. Corresponding MRCP image (C) shows the exact site and extent of biliary involvement which is important for surgical and biliary intervention planning. T2-weighted coronal image (D) of another patient shows a malignant gallbladder mass (arrow) showing diffusion restriction (E [diffusion-weighted imaging [DWI] 800], F [apparent diffusion coefficient [ADC]]), involving the bile duct, just below the primary confluence which is well depicted by the MRCP image (G).

Table 2 8th AJCC staging definitions for GBC

Stage	Definition
T1	Tumor invades lamina propria or muscular layer
T2a	Tumor invades perimuscular connective tissue on the peritoneal side, without involvement of the serosa (visceral peritoneum)
T2b	Tumor invades perimuscular connective tissue on the hepatic side, with no extension into the liver
T3	Tumor perforates serosa (visceral peritoneum) and/or directly invades the liver and/or one other adjacent organ or structure
T4	Tumor invades main portal vein or hepatic artery or invades two or more extrahepatic organs or structures
N0	No regional lymph node metastasis
N1	Metastases to 1–3 regional lymph nodes
N2	Metastases to ≥ 4 regional lymph nodes
M0	No distant metastasis
M1	Distant metastasis

Abbreviations: AJCC, American Joint Committee on Cancer; GBC, gallbladder cancer.
 Note: Modified from Amin et al.⁹⁶

Multidetector Computed Tomography

CECT is the imaging modality of choice for staging and preoperative planning. In addition, CT allows assessment of anatomical variations of vessels and future liver remnant.

-T staging

Discrimination of T1 and T2 is challenging on CT. In a study by Kim et al for accuracy of CT in local staging of GBC,

presence of pericholecystic fat stranding was considered as T3 and obvious hepatic mass in GB fossa was considered as T4.⁷³ They found an accuracy of over 70% for detection of T1/T2 and T4 tumors on CT; however, the accuracy was only 46% for T3 tumors. Poor accuracy for local staging of T3 disease was attributed to the inability of CT to identify minimal pericholecystic extension, local inflammatory changes, and volume averaging artifacts. A study conducted by Kim et al showed CT accuracy of 83.9% in preoperative T staging of GBC.⁷² Vascular involvement is considered when there is tumor vessel contact > 180 degrees, irregular outline, narrowing of caliber, or tumor on both sides of the vessel.¹⁰²

-N and M staging

The lymph nodes and peritoneal involvement are frequently underestimated on CT compared to surgical detection. Ohtani et al reported a lower sensitivity of 36 and 47%, respectively, for N1 and N2 nodal involvement detection on CT compared to pathological findings.¹⁰³ CT also has shown low sensitivity in identification of peritoneal/omental disease (85–93%).¹⁰³

Magnetic Resonance Imaging

MRI has frequently been utilized in GBC staging because of its excellent soft tissue resolution and clear depiction of biliary tree.²

-T staging

High-resolution T2W and DWI have higher accuracy in local staging.¹⁰⁴ Eaton et al demonstrated that MRI had 100% sensitivity and 70% specificity in detecting subcentimetric lesions.¹⁰⁵ In a retrospective study, a combination of MRI, MRCP, and DCE-MRI sequences had an accuracy of 84% for determining the T stage. Overstaging was due to the presence of concurrent inflammation or when a mass shows papillary features due to their exaggerated enhancement on the dynamic phase. Kim et al found 100% sensitivity and 90% specificity for bile duct and vascular invasion.¹⁰⁶ In another retrospective study by Schwartz et al, it demonstrated conventional MRI with MRCP achieved a sensitivity of 100% for liver invasion which has better accuracy if invasion was greater than 2 cm.⁸⁰

-N and M staging

Metastatic lymph nodes appear hyperintense on T2W, and high *b*-value DWI. Studies have shown improved sensitivity of DWI with ADC in the detection of liver, regional nodal, and distant metastases.¹⁰⁷

The accuracy, sensitivity, and specificity for the N staging were 77.9, 78.4, and 77.6%, respectively, in a study by Kim et al.⁷⁹ Schwartz et al showed a higher (92%) sensitivity for nodal staging.⁸⁰ In a meta-analysis, the pooled sensitivity of MRI for detecting lymph node metastasis was 75%.¹⁰⁷

Positron Emission Tomography-Computed Tomography

PET-CT is superior in assessing primary tumor, nodal spread, as well as distant metastasis in comparison to CT. PET-CT has

no added value in the T staging of disease; however, it has shown to have higher positive predictive value and accuracy in the detection of regional lymph nodes and distant metastasis as compared to multidetector CT, thereby predicting resectability.^{92–95}

Role of Imaging in Prognostication of Gallbladder Cancer

GBC has a poor outcome with an overall 5-year survival rate of < 5%, which, however, can be improved to 75% if detected early and if stage-adjusted treatment strategies are used.¹⁰⁸ Accurate assessment of the local extent of disease is pivotal in determining optimal management strategy. Surgical treatment of GBC depends on the tumor extent and hence prognosis depends on the T stage of the disease. Imaging is crucial in preoperative differentiation of T1 from T2 disease and T2 lesions from advanced disease.⁷² T1a lesions diagnosed incidentally on cholecystectomy do not need further surgery. T1b and T2 lesions without nodal metastasis are recommended for radical cholecystectomy with en-bloc resection of adjacent liver. T3 and T4 disease do not benefit from primary surgical resection and require chemotherapy or external beam radiotherapy.^{24,109} A study by Wright et al showed up to 40% chances of local recurrence of disease when simple cholecystectomy was performed for T2 disease.¹¹⁰ The impact of imaging on local staging and detection of lymph node and distant metastases has already been discussed in the previous section on staging.^{13,110} Apart from conventional imaging, radiomics may improve the prediction of lymph nodal metastasis.^{111,112}

Tumor-related imaging features that may suggest prognosis are discussed below. A study by Choi et al showed no significant relationship of tumor size with R0/R1/R2 resection.¹¹³ However, imaging features such as morphology, involvement of hepatic wall of GB, liver invasion, duodenal invasion, and involvement of hepatic artery, portal vein, biliary tree, regional lymph node, and omentum were associated with high probability of positive resection margins, of which, hepatic artery invasion had highest specificity of positive margins.¹¹³ A study by Shindoh et al showed that T2 tumors involving the hepatic wall (T2b) had higher rates of nodal, perineural, and vascular invasion as compared to T2 tumors involving the peritoneal wall (T2a).⁹⁷ Hence, adjuvant therapy is needed for T2b tumors along with resection.¹¹⁴ Similar studies have also shown higher survival and lower recurrence rates in T2a disease as compared to T2b disease.^{115,116} A study by Shirai et al showed that the number of involved lymph nodes predicted the surgical outcomes better as compared to the location of lymph nodes.¹¹⁷ A study by Higuchi et al showed that poor clinical outcomes were associated with stage 3/4 disease without distant metastasis, if liver invasion was ≥ 5 mm or invasion of the left margin or the entire hepatoduodenal ligament, or ≥ 4 metastatic lymph nodes.¹¹⁸ Nomograms for prediction of prognosis after surgery have been developed by Xu et al based

on the TNM stage.¹¹⁹ A recent radiomics-based study using the classification and regression tree analysis has shown that patients with tumors larger than 5 cm had poor prognosis, though tumor size is not a criterion in the present AJCC 8th edition. This study also showed that preoperative biliary drainage was also a marker of poor outcome.¹²⁰ An externally validated model developed by de Savornin Lohman et al has shown good discrimination capacity with calibration for prediction of survival in GBC and has shown to outperform the AJCC staging system.¹⁰⁷ Zhang et al constructed a nomogram model to predict cancer-specific survival rates in patients with liver metastasis in GBC.¹²¹ CT-based deep learning (DL) models constructed by Yin et al and Liu et al, have also shown good prediction of survival outcomes in GBC.^{122,123} Krishnaraju et al have shown that FDG-PET improved prognostication of residual and metastatic disease in incidentally detected GBC and the strategy of management changed in 10% of patients following FDG-PET as compared to a CECT.¹²⁴

Studies have also proven improvement in the rates of R0 resection following neoadjuvant chemotherapy in

cases of locally advanced GBC.^{125–131} Imaging following neoadjuvant chemotherapy is crucial in deciding resectability and comparison of sequential imaging is mandatory. No specific response assessment criteria are available for GBC and Modified Response Evaluation Criteria in Solid Tumors criteria is commonly used, however, may be difficult with wall-thickening type of GBC. No set guidelines are available on the recommended imaging modality or frequency of interval imaging following neoadjuvant chemotherapy.¹⁴

Imaging also helps in postoperative surveillance of GBC as up to 50% of the tumors recur within 2 years of surgery. The National Comprehensive Cancer Network guidelines recommend close follow-up with imaging every 3 to 6 months up to 5 years and yearly imaging thereafter.² It is important to differentiate recurrent tumor from postoperative changes. Invasion of fat between vessels, vascular encasement, and bowel infiltration suggest recurrence rather than postoperative changes.¹³²

Table 3 AI radiomics and radiological imaging-based deep learning in GBC

Author (year)	Imaging technique	Aim	AI algorithm	Performance
Gupta et al ¹³⁴ (2023)	US	Differentiating XGC and GBC	DL (GBCNet-convolutional neural network [CNN] and RadFormer, transformer)	0.744–0.751, $p = 0.514$
Wang et al ¹³⁵ (2023)	US	Risk stratification of GB masses	DL (XGBoost-based US radiomics model)	0.995 ($p < 0.011$)
Gupta et al ¹⁰ (2023)	US	GBC detection	DL (CNN) GBCNet (MS-SoP)	0.887 (95% CI, 0.844–0.930)
Basu et al ¹³⁶ (2023)	US	GBC detection	DL (Transformer) RadFormer	0.971
Xiang et al ¹³⁷ (2024)	CECT	GBC detection	DL (ResNet50)	0.857 (95% CI: 0.773–0.942) to 0.864 (95% CI: 0.814–0.915)
Yin et al ¹³⁸ (2023)	CECT	GB lesion characterization *emphasis on studying the adjacent liver parenchyma while evaluation for GBC	DL (CNN)	0.71 (95% CI 0.58–0.88) 0.81 (95% CI 0.71–0.92; $p = 0.09$) ^a
Fujita et al ¹³⁹ (2022)	CECT	Differentiating XGC and GBC	DL (ResNet 50)	0.9998 (95% CI: 0.9997–1.0000, $p < 0.0001$) to 0.9985 (95% CI: 0.9981–0.9990, $p < 0.0001$)
Zhang et al ¹⁴⁰ (2024)	CECT	Differentiating XGC and GBC	DL (Resnet-18 with Fourier transformation (FCovResnet18))	0.92–1
Zhou et al ¹⁴¹ (2024)	CECT	Prediction of serosal involvement in GBC	ML (best-logistic regression), DL (f-CNN)	f-CNN 0.916, Logistic regression 0.944
Liu et al ¹²³ (2020)	CECT	Predicting the overall survival of GBC	ML (LASSO and random forest)	0.73–0.79
Liu et al ¹⁴² (2021)	CECT	Predicting lymph node metastasis in GBC	ML (LASSO/Random Forest)	0.810 (95% CI, 0.645–0.993) to 0.851 (95% CI, 0.741–0.908)
Yin et al ¹⁴³ (2023)	CECT	GB lesion characterization	ML (LASSO, ridge regression, and XG Boosting)	0.81 (95% CI: 0.72–0.91)
Meng et al ¹⁴⁴ (2023)	CECT	Postoperative survival in GBC	ML + DL – Logistic regression, DenseNet 121	0.871

Abbreviations: AI, artificial intelligence; CI, confidence interval; CECT, contrast-enhanced computed tomography; GB, gallbladder; GBC, gallbladder cancer; US, ultrasound; XGC, xanthogranulomatous cholecystitis.

^aAdding information from adjacent liver parenchyma.

Artificial Intelligence, Radiomics, and Radiogenomics

AI has enormously influenced medical practice in many spheres. DL, a subset of AI, is now the state-of-the-art AI technique in the medical domain, automatically learning feature representations from sample images using neural networks.^{9,10} The capabilities of DL-based models range from risk stratification and detection to phenotypic and genotypic characterization, guiding treatment, and outcome prediction. Radiomics is the process of extracting useful quantitative information from radiological images, which can yield information about tumor biology to guide “precision medicine” for each individual patient. It involves the extraction of a large number of parameters from the images, which can provide information with myriad applications in the disease process, including detection, characterization, prognostication, guiding therapy, assessment of treatment response, and risk of recurrence. Further, the correlation of imaging phenotypic data with genotype expression is called radiogenomics, which can generate clinically useful information, acting as a substitute for genetic testing and playing a crucial role in individual patient management in the era of precision medicine.^{9,10,133}

Numerous studies have been undertaken to evaluate the role of AI in various domains of GBC.^{10,123,134–144} **Table 3** summarizes the various machine learning and DL-based studies in the evaluation of GBC, including its application in radiomics and radiogenomics. While the existing studies are based on a small number of patients and are yet to be validated on a larger scale for clinical utilization, they seem to have the potential to significantly impact the overall management of the disease in the future.

In conclusion, imaging in GBC has significantly evolved and is no longer restricted only to diagnosis and staging. With recent insights into the disease pathogenesis and advances in technology, imaging plays a critical role in risk stratification and prognostication of patients with GBC.

Funding

None.

Conflict of Interest

None declared.

References

- 1 Feo CF, Ginesu GC, Fancellu A, et al. Current management of incidental gallbladder cancer: a review. *Int J Surg* 2022;98:106234
- 2 Lopes Vendrami C, Magnetta MJ, Mittal PK, Moreno CC, Miller FH. Gallbladder carcinoma and its differential diagnosis at MRI: what radiologists should know. *Radiographics* 2021;41(01):78–95
- 3 Bal MM, Ramadwar M, Deodhar K, Shrikhande S. Pathology of gallbladder carcinoma: current understanding and new perspectives. *Pathol Oncol Res* 2015;21(03):509–525
- 4 Roa JC, Basturk O, Adsay V. Dysplasia and carcinoma of the gallbladder: pathological evaluation, sampling, differential diagnosis and clinical implications. *Histopathology* 2021;79(01):2–19
- 5 Tan CH, Lim KS. MRI of gallbladder cancer. *Diagn Interv Radiol* 2013;19(04):312–319
- 6 Pavlidis ET, Galanis IN, Pavlidis TE. New trends in diagnosis and management of gallbladder carcinoma. *World J Gastrointest Oncol* 2024;16(01):13–29
- 7 Ramachandran A, Srivastava DN, Madhusudhan KS. Gallbladder cancer revisited: the evolving role of a radiologist. *Br J Radiol* 2021;94(1117):20200726
- 8 Levy AD, Murakata LA, Rohrmann CA Jr. Gallbladder carcinoma: radiologic-pathologic correlation. *Radiographics* 2001;21(02):295–314; questionnaire, 549–555
- 9 Gupta P, Basu S, Arora C. Applications of artificial intelligence in biliary tract cancers. *Indian J Gastroenterol* 2024
- 10 Gupta P, Basu S, Rana P, et al. Deep-learning enabled ultrasound based detection of gallbladder cancer in northern India: a prospective diagnostic study. *Lancet Reg Health Southeast Asia* 2023;24:100279
- 11 Chhabra M, Kalage D, Gupta P, et al. Proposal for a new morphological “combined type” of gallbladder cancer: description of radiopathological characteristics and comparison with other morphological types. *Abdom Radiol (NY)* 2024;49(03):703–709
- 12 Ganeshan D, Kambadakone A, Nikolaidis P, Subbiah V, Subbiah IM, Devine C. Current update on gallbladder carcinoma. *Abdom Radiol (NY)* 2021;46(06):2474–2489
- 13 Kalra N, Suri S, Gupta R, et al. MDCT in the staging of gallbladder carcinoma. *AJR Am J Roentgenol* 2006;186(03):758–762
- 14 Gupta P, Meghashyam K, Marodia Y, et al. Locally advanced gallbladder cancer: a review of the criteria and role of imaging. *Abdom Radiol (NY)* 2021;46(03):998–1007
- 15 Furlan A, Ferris JV, Hosseinzadeh K, Borhani AA. Gallbladder carcinoma update: multimodality imaging evaluation, staging, and treatment options. *AJR Am J Roentgenol* 2008;191(05):1440–1447
- 16 Rana P, Gupta P, Kalage D, Soundararajan R, Kumar-M P, Dutta U. Grayscale ultrasonography findings for characterization of gallbladder wall thickening in non-acute setting: a systematic review and meta-analysis. *Expert Rev Gastroenterol Hepatol* 2022;16(01):59–71
- 17 Rana P, Pruthi H, Gupta P, et al. Sonographic “cervix sign”: a new ancillary sign of gallbladder neck malignancy. *J Clin Exp Hepatol* 2023;13(06):972–976
- 18 Tongdee R, Maroongroge P, Suthikeree W. The value of MDCT scans in differentiation between benign and malignant gallbladder wall thickening. *J Med Assoc Thai* 2011;94(05):592–600
- 19 Kim SJ, Lee JM, Lee JY, et al. Analysis of enhancement pattern of flat gallbladder wall thickening on MDCT to differentiate gallbladder cancer from cholecystitis. *AJR Am J Roentgenol* 2008;191(03):765–771
- 20 Corwin MT, Khera SS, Loehfelm TW, Yang NT, Fananapazir G. Incidentally detected focal fundal gallbladder wall thickening at contrast-enhanced computed tomography: prevalence and computed tomography features of malignancy. *J Comput Assist Tomogr* 2019;43(01):149–154
- 21 Kalra N, Gupta P, Singhal M, et al. Cross-sectional imaging of gallbladder carcinoma: an update. *J Clin Exp Hepatol* 2019;9(03):334–344
- 22 Foley KG, Lahaye MJ, Thoeni RF, et al. Management and follow-up of gallbladder polyps: updated joint guidelines between the ESGAR, EAES, EFISDS and ESGE. *Eur Radiol* 2022;32(05):3358–3368
- 23 Kamaya A, Fung C, Szpakowski JL, et al. Management of incidentally detected gallbladder polyps: Society of Radiologists in Ultrasound consensus conference recommendations. *Radiology* 2022;305(02):277–289
- 24 Ito M, Mishima Y, Sato T. An anatomical study of the lymphatic drainage of the gallbladder. *Surg Radiol Anat* 1991;13(02):89–104

- 25 Pesce A, Li Destri G, Amore FF, Magro G, La Greca G, Puleo S. A rare case of Krukenberg tumor by gallbladder cancer. *Ann Med Surg (Lond)* 2019;47:50–52
- 26 Chaudhari S, Hatwal D, Bhat P. A rare presentation of gallbladder carcinoma metastasis. *J Clin Diagn Res* 2014;8(06):FD19–FD20
- 27 Win AZ, Aparici CM. Rare case of gallbladder cancer presenting with meta-stasis to bone and brain in an African American male discovered by F18-FDG PET/CT. *J Biomed Graph Comput* 2013;3(02):24–29
- 28 Joshi MK, Joshi R, Chadha M, Alam SE, Varshneya H, Kumar S. Gall bladder carcinoma presenting with spinal metastasis: a rare phenomenon. *Indian J Palliat Care* 2013;19(02):113–115
- 29 Marin H, Bouras AF, Patenôtre P, et al. Cheek metastasis from gallbladder adenocarcinoma. *J Visc Surg* 2013;150(03):225–226
- 30 Baghmar S, Sandhyav R, Arora A, Arora A. Carcinoma gall bladder with cardiac metastasis presenting as liver abscess: an unusual case. *Trop Gastroenterol* 2019;39(03):173–175
- 31 Miyoshi H, Inui K, Katano Y, Tachi Y, Yamamoto S. B-mode ultrasonographic diagnosis in gallbladder wall thickening. *J Med Ultrason* 2021;48(02):175–186
- 32 Dwivedi AN, Jain S, Dixit R. Gall bladder carcinoma: aggressive malignancy with protean loco-regional and distant spread. *World J Clin Cases* 2015;3(03):231–244
- 33 Soundararajan R, Marodia Y, Gupta P, et al. Imaging patterns of wall thickening type of gallbladder cancer. *Clin Exp Hepatol* 2022;8(04):255–266
- 34 Gupta P, Dutta U, Rana P, et al. Gallbladder reporting and data system (GB-RADS) for risk stratification of gallbladder wall thickening on ultrasonography: an international expert consensus. *Abdom Radiol (NY)* 2022;47(02):554–565
- 35 Soundararajan R, Subramanian P, Gupta P, et al. Agreement of gallbladder reporting and data system for gallbladder wall thickening at ultrasonography: a multireader validation study. *J Clin Exp Hepatol* 2024;14(04):101393
- 36 Wang R, Lv L, Li L. Diagnostic performance of the gallbladder reporting and data system combined with color doppler flow imaging for gallbladder cancer in the Asian population. *Front Oncol* 2024;14:1367351
- 37 Boccatonda A, Cocco G, D'Ardes D, Schiavone C. GB-RADS score, a possible role for CEUS? *Abdom Radiol (NY)* 2023;48(03):1199–1201
- 38 Zhu L, Li N, Zhu Y, et al. Value of high frame rate contrast enhanced ultrasound in gallbladder wall thickening in non-acute setting. *Cancer Imaging* 2024;24(01):7
- 39 Martin E, Gill R, Debru E. Diagnostic accuracy of transabdominal ultrasonography for gallbladder polyps: systematic review. *Can J Surg* 2018;61(03):200–207
- 40 Pickering O, Pucher PH, Toale C, et al. Prevalence and sonographic detection of gallbladder polyps in a western European population. *J Surg Res* 2020;250:226–231
- 41 Li Y, Tejirian T, Collins JC. Gallbladder polyps: real or imagined? *Am Surg* 2018;84(10):1670–1674
- 42 Metman MJH, Olthof PB, van der Wal JBC, van Gulik TM, Roos D, Dekker JWT. Clinical relevance of gallbladder polyps; is cholecystectomy always necessary? *HPB (Oxford)* 2020;22(04):506–510
- 43 Kim JH, Lee JY, Baek JH, et al. High-resolution sonography for distinguishing neoplastic gallbladder polyps and staging gallbladder cancer. *AJR Am J Roentgenol* 2015;204(02):W150–9
- 44 Pradhan S, Shukla VK, Agrawal S, Dixit VK, Sharma OP. Sonographic and colour doppler morphology in carcinoma gallbladder. *Indian J Cancer* 2002;39(04):143–148
- 45 Hirooka Y, Naitoh Y, Goto H, Furukawa T, Ito A, Hayakawa T. Differential diagnosis of gall-bladder masses using colour Doppler ultrasonography. *J Gastroenterol Hepatol* 1996;11(09):840–846
- 46 Li Y, Wang Y, Chi M. The diagnostic value of high-frequency ultrasound combined with color Doppler ultrasound versus surgical pathology in gallbladder polyps. *Am J Transl Res* 2021;13(07):7990–7996
- 47 Hayakawa S, Goto H, Hirooka Y, et al. Colour Doppler-guided spectral analysis of gall-bladder wall flow. *J Gastroenterol Hepatol* 1998;13(02):181–185
- 48 Li D, Dong BW, Wu YL, Yan K. Image-directed and color Doppler studies of gallbladder tumors. *J Clin Ultrasound* 1994;22(09):551–555
- 49 Mellnick VM, Menias CO, Sandrasegaran K, et al. Polypoid lesions of the gallbladder: disease spectrum with pathologic correlation. *Radiographics* 2015;35(02):387–399
- 50 Komatsuda T, Ishida H, Konno K, et al. Gallbladder carcinoma: color Doppler sonography. *Abdom Imaging* 2000;25(02):194–197
- 51 Teber MA, Tan S, Dönmez U, et al. The use of real-time elastography in the assessment of gallbladder polyps: preliminary observations. *Med Ultrason* 2014;16(04):304–308
- 52 Soundararajan R, Dutta U, Bhatia A, et al. Two-dimensional shear wave elastography: utility in differentiating gallbladder cancer from chronic cholecystitis. *J Ultrasound Med* 2023;42(07):1577–1585
- 53 Kapoor A, Kapoor A, Mahajan G. Differentiating malignant from benign thickening of the gallbladder wall by the use of acoustic radiation force impulse elastography. *J Ultrasound Med* 2011;30(11):1499–1507
- 54 Cheng Y, Wang M, Ma B, Ma X. Potential role of contrast-enhanced ultrasound for the differentiation of malignant and benign gallbladder lesions in East Asia: a meta-analysis and systematic review. *Medicine (Baltimore)* 2018;97(33):e11808
- 55 Zhang HP, Bai M, Gu JY, He YQ, Qiao XH, Du LF. Value of contrast-enhanced ultrasound in the differential diagnosis of gallbladder lesion. *World J Gastroenterol* 2018;24(06):744–751
- 56 Numata K, Oka H, Morimoto M, et al. Differential diagnosis of gallbladder diseases with contrast-enhanced harmonic gray scale ultrasonography. *J Ultrasound Med* 2007;26(06):763–774
- 57 Dong Y, Liu L, Cao Q, et al. Differential diagnosis of focal gallbladder lesions: the added value of contrast enhanced ultrasound with liner transducers. *Clin Hemorheol Microcirc* 2020;74(02):167–178
- 58 Boddapati SB, Lal A, Gupta P, et al. Contrast enhanced ultrasound versus multiphase contrast enhanced computed tomography in evaluation of gallbladder lesions. *Abdom Radiol (NY)* 2022;47(02):566–575
- 59 Zhuang B, Li W, Wang W, et al. Contrast-enhanced ultrasonography improves the diagnostic specificity for gallbladder-confined focal tumors. *Abdom Radiol (NY)* 2018;43(05):1134–1142
- 60 Liu LN, Xu HX, Lu MD, et al. Contrast-enhanced ultrasound in the diagnosis of gallbladder diseases: a multi-center experience. *PLoS One* 2012;7(10):e48371
- 61 Wang W, Fei Y, Wang F. Meta-analysis of contrast-enhanced ultrasonography for the detection of gallbladder carcinoma. *Med Ultrason* 2016;18(03):281–28
- 62 Kong WT, Shen HY, Qiu YD, Han H, Wen BJ, Wu M. Application of contrast enhanced ultrasound in gallbladder lesion: is it helpful to improve the diagnostic capabilities? *Med Ultrason* 2018;20(04):420–426
- 63 Yuan HX, Wang WP, Wen JX, et al. Xanthogranulomatous cholecystitis: contrast-enhanced ultrasound features and differential diagnosis from wall-thickening gallbladder carcinoma. *Discov Med* 2016;21(114):89–98
- 64 Tang S, Huang L, Wang Y, Wang Y. Contrast-enhanced ultrasonography diagnosis of fundal localized type of gallbladder adenomyomatosis. *BMC Gastroenterol* 2015;15:99
- 65 Gupta P, Kumar M, Sharma V, Dutta U, Sandhu MS. Evaluation of gallbladder wall thickening: a multimodality imaging approach. *Expert Rev Gastroenterol Hepatol* 2020;14(06):463–473
- 66 de Sio I, D'Onofrio M, Mirk P, et al; SIUMB experts committee. SIUMB recommendations on the use of ultrasound in neoplastic lesions of the gallbladder and extrahepatic biliary tract. *J Ultrasound* 2023;26(03):725–731

- 67 Choi JH, Seo DW, Choi JH, et al. Utility of contrast-enhanced harmonic EUS in the diagnosis of malignant gallbladder polyps (with videos). *Gastrointest Endosc* 2013;78(03):484–493
- 68 Bae JS, Kim SH, Kang HJ, et al. Quantitative contrast-enhanced US helps differentiating neoplastic vs non-neoplastic gallbladder polyps. *Eur Radiol* 2019;29(07):3772–3781
- 69 Liu XS, Gu LH, Du J, et al. Differential diagnosis of polypoid lesions of the gallbladder using contrast-enhanced sonography. *J Ultrasound Med* 2015;34(06):1061–1069
- 70 Miwa H, Numata K, Sugimori K, Kaneko T, Maeda S. Vascular evaluation using transabdominal ultrasound for gallbladder polyps. *J Med Ultrason* 2021;48(02):159–173
- 71 Yuan Z, Liu X, Li Q, et al. Is contrast-enhanced ultrasound superior to computed tomography for differential diagnosis of gallbladder polyps? A cross-sectional study. *Front Oncol* 2021; 11:657223
- 72 Kim SJ, Lee JM, Lee JY, et al. Accuracy of preoperative T-staging of gallbladder carcinoma using MDCT. *AJR Am J Roentgenol* 2008; 190(01):74–80
- 73 Kim BS, Ha HK, Lee IJ, et al. Accuracy of CT in local staging of gallbladder carcinoma. *Acta Radiol* 2002;43(01):71–76
- 74 Gupta P, Marodia Y, Bansal A, et al. Imaging-based algorithmic approach to gallbladder wall thickening. *World J Gastroenterol* 2020;26(40):6163–6181
- 75 Marodia Y, Kharel J, Saikia UN, et al. Association of CT findings with perineural invasion in gallbladder cancer: preliminary assessment. *AJR Am J Roentgenol* 2023;220(06):850–851
- 76 Pruthi H, Chhabra M, Soundararajan R, et al. Role of dual energy computed tomography in evaluation of suspected wall thickening type of gallbladder cancer. *Clin Exp Hepatol* 2022;8(01):92–95
- 77 Reddy KP, Gupta P, Gulati A, et al. Dual-energy CT in differentiating benign gallbladder wall thickening from wall thickening type of gallbladder cancer. *Eur Radiol* 2024. Doi: 10.1007/s00330-024-10904-3
- 78 Catalano OA, Sahani DV, Kalva SP, et al. MR imaging of the gallbladder: a pictorial essay. *Radiographics* 2008;28(01):135–155, quiz 324
- 79 Kim SJ, Lee JM, Lee ES, Han JK, Choi BI. Preoperative staging of gallbladder carcinoma using biliary MR imaging. *J Magn Reson Imaging* 2015;41(02):314–321
- 80 Schwartz LH, Black J, Fong Y, et al. Gallbladder carcinoma: findings at MR imaging with MR cholangiopancreatography. *J Comput Assist Tomogr* 2002;26(03):405–410
- 81 Hu Y, Jia D, Xu Z, et al. Value of diffusion-weighted MRI in differentiation between benign and malignant polypoid gallbladder lesions [in Chinese]. *Zhonghua Yi Xue Za Zhi* 2015;95(39):3201–3204
- 82 Ohki K, Igarashi T, Yakabe H, et al. Differentiating gallbladder cancer from polyps using non-enhanced magnetic resonance imaging. *Pol J Radiol* 2024;89:e106–e114
- 83 Yoshioka M, Watanabe G, Uchinami H, et al. Diffusion-weighted MRI for differential diagnosis in gallbladder lesions with special reference to ADC cut-off values. *Hepatogastroenterology* 2013; 60(124):692–698
- 84 Kim SJ, Lee JM, Kim H, Yoon JH, Han JK, Choi BI. Role of diffusion-weighted magnetic resonance imaging in the diagnosis of gallbladder cancer. *J Magn Reson Imaging* 2013;38(01):127–137
- 85 Kitazume Y, Taura S, Nakaminato S, et al. Diffusion-weighted magnetic resonance imaging to differentiate malignant from benign gallbladder disorders. *Eur J Radiol* 2016;85(04):864–873
- 86 Lee NK, Kim S, Moon JI, et al. Diffusion-weighted magnetic resonance imaging of gallbladder adenocarcinoma: analysis with emphasis on histologic grade. *Clin Imaging* 2016;40(03): 345–351
- 87 Min JH, Kang TW, Cha DI, et al. Apparent diffusion coefficient as a potential marker for tumour differentiation, staging and long-term clinical outcomes in gallbladder cancer. *Eur Radiol* 2019;29(01):411–421
- 88 Kalage D, Gupta P, Gulati A, et al. Contrast enhanced CT versus MRI for accurate diagnosis of wall-thickening type gallbladder cancer. *J Clin Exp Hepatol* 2024;14(05):101397
- 89 Takashima T, Nakazawa S, Yoshino J, et al. Diagnosis of the wall-thickened lesions of the gallbladder with dynamic MRI [in Japanese]. *Nihon Shokakibyō Gakkai Zasshi* 1998;95(05):424–431
- 90 Kalage D, Gupta P, Gulati A, et al. Multiparametric MR imaging with diffusion-weighted, intravoxel incoherent motion, diffusion tensor, and dynamic contrast-enhanced perfusion sequences to assess gallbladder wall thickening: a prospective study based on surgical histopathology. *Eur Radiol* 2023;33(07): 4981–4993
- 91 Yoshimitsu K, Honda H, Kaneko K, et al. Dynamic MRI of the gallbladder lesions: differentiation of benign from malignant. *J Magn Reson Imaging* 1997;7(04):696–701
- 92 Annunziata S, Pizzuto DA, Caldarella C, Galiandro F, Sadeghi R, Treglia G. Diagnostic accuracy of fluorine-18-fluorodeoxyglucose positron emission tomography in gallbladder cancer: a meta-analysis. *World J Gastroenterol* 2015;21(40):11481–11488
- 93 Pericleous S, Doran SLF, Wotherspoon A, et al. The diagnostic accuracy of ¹⁸F-FDG-PET/CT for cancer of the gallbladder: a retrospective study. *World J Nucl Med* 2022;21(02):112–119
- 94 Gupta V, Vishnu KS, Yadav TD, et al. Radio-pathological correlation of 18F-FDG PET in characterizing gallbladder wall thickening. *J Gastrointest Cancer* 2019;50(04):901–906
- 95 Parida GK, Panda RA, Agrawal K. Impact of fluorine-18-fluorodeoxyglucose PET/computed tomography in staging of patients with gallbladder cancer: a systematic review and meta-analysis. *Nucl Med Commun* 2021;42(08):846–854
- 96 Amin MB, Greene FL, Edge SB, et al. The Eighth Edition AJCC Cancer Staging Manual: continuing to build a bridge from a population-based to a more “personalized” approach to cancer staging. *CA Cancer J Clin* 2017;67(02):93–99
- 97 Shindoh J, de Aretxabala X, Aloia TA, et al. Tumor location is a strong predictor of tumor progression and survival in T2 gallbladder cancer: an international multicenter study. *Ann Surg* 2015;261(04):733–739
- 98 Lee AJ, Chiang YJ, Lee JE, et al. Validation of American Joint Committee on Cancer eighth staging system for gallbladder cancer and its lymphadenectomy guidelines. *J Surg Res* 2018; 230:148–154
- 99 Sadamoto Y, Kubo H, Harada N, Tanaka M, Eguchi T, Nawata H. Preoperative diagnosis and staging of gallbladder carcinoma by EUS. *Gastrointest Endosc* 2003;58(04):536–541
- 100 Makar M, Zhao E, Tyberg A. Personalized approach to the role of endoscopic ultrasound in the diagnosis and management of pancreaticobiliary malignancies. *J Pers Med* 2021;11(03):180
- 101 Hijioka S, Nagashio Y, Ohba A, Maruki Y, Okusaka T. The role of EUS and EUS-FNA in differentiating benign and malignant gallbladder lesions. *Diagnostics (Basel)* 2021;11(09):1586
- 102 Kumaran V, Gulati S, Paul B, Pande K, Sahni P, Chattopadhyay K. The role of dual-phase helical CT in assessing resectability of carcinoma of the gallbladder. *Eur Radiol* 2002;12(08):1993–1999
- 103 Ohtani T, Shirai Y, Tsukada K, Muto T, Hatakeyama K. Spread of gallbladder carcinoma: CT evaluation with pathologic correlation. *Abdom Imaging* 1996;21(03):195–201
- 104 Tseng JH, Wan YL, Hung CF, et al. Diagnosis and staging of gallbladder carcinoma. Evaluation with dynamic MR imaging. *Clin Imaging* 2002;26(03):177–182
- 105 Eaton JE, Thackeray EW, Lindor KD. Likelihood of malignancy in gallbladder polyps and outcomes following cholecystectomy in primary sclerosing cholangitis. *Am J Gastroenterol* 2012;107(03):431–439
- 106 Kim JH, Kim TK, Eun HW, et al. Preoperative evaluation of gallbladder carcinoma: efficacy of combined use of MR imaging, MR cholangiography, and contrast-enhanced dual-phase three-dimensional MR angiography. *J Magn Reson Imaging* 2002;16(06):676–684

- 107 de Savornin Lohman EJ, de Bitter TJJ, van Laarhoven CJHM, Hermans JJ, de Haas RJ, de Reuver PR. The diagnostic accuracy of CT and MRI for the detection of lymph node metastases in gallbladder cancer: a systematic review and meta-analysis. *Eur J Radiol* 2019;110:156–162
- 108 Goetze TO. Gallbladder carcinoma: prognostic factors and therapeutic options. *World J Gastroenterol* 2015;21(43):12211–12217
- 109 Aloia TA, Járufe N, Javle M, et al. Gallbladder cancer: expert consensus statement. *HPB (Oxford)* 2015;17(08):681–690
- 110 Wright BE, Lee CC, Iddings DM, Kavanagh M, Bilchik AJ. Management of T2 gallbladder cancer: are practice patterns consistent with national recommendations? *Am J Surg* 2007;194(06):820–825, discussion 825–826
- 111 Ji GW, Zhang YD, Zhang H, et al. Biliary tract cancer at CT: a radiomics-based model to predict lymph node metastasis and survival outcomes. *Radiology* 2019;290(01):90–98
- 112 Ma Y, Lin Y, Lu J, et al. A meta-analysis of based radiomics for predicting lymph node metastasis in patients with biliary tract cancers. *Front Surg* 2023;9:1045295
- 113 Choi SY, Kim JH, Park HJ, Han JK. Preoperative CT findings for prediction of resectability in patients with gallbladder cancer. *Eur Radiol* 2019;29(12):6458–6468
- 114 Lee H, Choi DW, Park JY, et al. Surgical strategy for T2 gallbladder cancer according to tumor location. *Ann Surg Oncol* 2015;22(08):2779–2786
- 115 Wang L, Dong P, Zhang Y, Yang M, Chen Y, Tian BL. Prognostic validation of the updated 8th edition Tumor-Node-Metastasis classification by the Union for International Cancer Control: survival analyses of 307 patients with surgically treated gallbladder carcinoma. *Oncol Lett* 2018;16(04):4427–4433
- 116 Liao X, Zhang D. The 8th Edition American Joint Committee on cancer staging for hepato-pancreato-biliary cancer: a review and update. *Arch Pathol Lab Med* 2021;145(05):543–553
- 117 Shirai Y, Sakata J, Wakai T, Ohashi T, Ajioka Y, Hatakeyama K. Assessment of lymph node status in gallbladder cancer: location, number, or ratio of positive nodes. *World J Surg Oncol* 2012;10:87
- 118 Higuchi R, Yazawa T, Uemura S, et al. Examination of prognostic factors affecting long-term survival of patients with stage 3/4 gallbladder cancer without distant metastasis. *Cancers (Basel)* 2020;12(08):2073
- 119 Xu X, He M, Wang H, Zhan M, Yang L. Development and validation of a prognostic nomogram for gallbladder cancer patients after surgery. *BMC Gastroenterol* 2022;22(01):200
- 120 Cotter G, Beal EW, Poultsides GA, et al. Using machine learning to preoperatively stratify prognosis among patients with gallbladder cancer: a multi-institutional analysis. *HPB (Oxford)* 2022;24(11):1980–1988
- 121 Zhang W, Chen Z, Sa B. Construction and validation of the predictive model for gallbladder cancer liver metastasis patients: a SEER-based study. *Eur J Gastroenterol Hepatol* 2024;36(01):129–134
- 122 Yin Z, Chen T, Shu Y, et al. A gallbladder cancer survival prediction model based on multimodal fusion analysis. *Dig Dis Sci* 2023;68(05):1762–1776
- 123 Liu Z, Zhu G, Jiang X, et al. Survival prediction in gallbladder cancer using CT based machine learning. *Front Oncol* 2020;10:604288
- 124 Krishnaraju VS, Kumar R, Mittal BR, et al. Incidentally detected gallbladder carcinoma: can F-18 FDG PET/CT aid in staging and prognostication? *Nucl Med Mol Imaging* 2024;58(03):104–112
- 125 Sirohi B, Mitra A, Jagannath P, et al. Neoadjuvant chemotherapy in patients with locally advanced gallbladder cancer. *Future Oncol* 2015;11(10):1501–1509
- 126 Creasy JM, Goldman DA, Dudeja V, et al. Systemic chemotherapy combined with resection for locally advanced gallbladder carcinoma: surgical and survival outcomes. *J Am Coll Surg* 2017;224(05):906–916
- 127 Selvakumar VPP, Zaidi S, Pande P, Goel A, Kumar K. Resection after neoadjuvant chemotherapy in advanced carcinoma of the gallbladder: a retrospective study. *Indian J Surg Oncol* 2015;6(01):16–19
- 128 Engineer R, Goel M, Chopra S, et al. Neoadjuvant chemoradiation followed by surgery for locally advanced gallbladder cancers: a new paradigm. *Ann Surg Oncol* 2016;23(09):3009–3015
- 129 Kato A, Shimizu H, Ohtsuka M, et al. Surgical resection after downsizing chemotherapy for initially unresectable locally advanced biliary tract cancer: a retrospective single-center study. *Ann Surg Oncol* 2013;20(01):318–324
- 130 Birnbaum DJ, Viganò L, Ferrero A, Langella S, Russolillo N, Capussotti L. Locally advanced gallbladder cancer: which patients benefit from resection? *Eur J Surg Oncol* 2014;40(08):1008–1015
- 131 Agrawal S, Mohan L, Mourya C, Neyaz Z, Saxena R. Radiological downstaging with neoadjuvant therapy in unresectable gall bladder cancer cases. *Asian Pac J Cancer Prev* 2016;17(04):2137–2140
- 132 Shin YM. Surveillance method and imaging characteristics of recurrent biliary cancer after surgical resection. *Korean J Hepatobiliary Pancreat Surg* 2014;18(03):73–76
- 133 Li S, Zhou B. A review of radiomics and genomics applications in cancers: the way towards precision medicine. *Radiat Oncol* 2022;17(01):217
- 134 Gupta P, Basu S, Yadav TD, et al. Deep-learning models for differentiation of xanthogranulomatous cholecystitis and gallbladder cancer on ultrasound. *Indian J Gastroenterol* 2023. Doi: 10.1007/s12664-023-01483-0
- 135 Wang LF, Wang Q, Mao F, et al. Risk stratification of gallbladder masses by machine learning-based ultrasound radiomics models: a prospective and multi-institutional study. *Eur Radiol* 2023;33(12):8899–8911
- 136 Basu S, Gupta M, Rana P, Gupta P, Arora C. RadFormer: transformers with global-local attention for interpretable and accurate gallbladder cancer detection. *Med Image Anal* 2023;83:102676
- 137 Xiang F, Meng QT, Deng JJ, et al. A deep learning model based on contrast-enhanced computed tomography for differential diagnosis of gallbladder carcinoma. *Hepatobiliary Pancreat Dis Int* 2024;23(04):376–384
- 138 Yin Y, Yakar D, Slangen JJG, Hoogwater FJH, Kwee TC, de Haas RJ. The value of deep learning in gallbladder lesion characterization. *Diagnostics (Basel)* 2023;13(04):704
- 139 Fujita H, Wakiya T, Ishido K, et al. Differential diagnoses of gallbladder tumors using CT-based deep learning. *Ann Gastroenterol Surg* 2022;6(06):823–832
- 140 Zhang W, Wang Q, Liang K, et al. Deep learning nomogram for preoperative distinction between Xanthogranulomatous cholecystitis and gallbladder carcinoma: a novel approach for surgical decision. *Comput Biol Med* 2024;168:107786
- 141 Zhou S, Han S, Chen W, et al. Radiomics-based machine learning and deep learning to predict serosal involvement in gallbladder cancer. *Abdom Radiol (NY)* 2024;49(01):3–10
- 142 Liu X, Liang X, Ruan L, Yan S. A clinical-radiomics nomogram for preoperative prediction of lymph node metastasis in gallbladder cancer. *Front Oncol* 2021;11:633852
- 143 Yin Y, Yakar D, Slangen JJG, Hoogwater FJH, Kwee TC, de Haas RJ. Optimal radiological gallbladder lesion characterization by combining visual assessment with CT-based radiomics. *Eur Radiol* 2023;33(04):2725–2734
- 144 Meng FX, Zhang JX, Guo YR, et al. Contrast-enhanced CT-based deep learning radiomics nomogram for the survival prediction in gallbladder cancer postoperative. *Acad Radiol* 2023;S1076–6332(23)00663–3