Article published online: 2024-09-10

Case Report

Early Recognition of Drug-Induced Febrile Neutropenia Leads to an Improved Outcome in the Trauma Intensive Care Unit: A Case Report

Bisman J.K. Khurana[1] Amarjyoti Hazarika[1] Kajal Jain[1]

[1] Department of Anaesthesia and Intensive Care, Postgraduate Institute of Medical Education and Research, Chandigarh, India

J Neuroanaesthesiol Crit Care

Address for correspondence Bisman Jeet Kaur Khurana, MD, DM, Department of Anaesthesia and Intensive Care, Postgraduate Institute of Medical Education and Research, Madhya Marg, Chandigarh 160012, India (e-mail: khurana.bisman@gmail.com).

Abstract

Traumatic brain injury necessitates the use of antiepileptics for seizure prophylaxis, which are associated with multiple side effects including neutropenia, which may be dose dependent or idiosyncratic. We report the case of a young male with traumatic brain injury who developed febrile neutropenia, likely secondary to antiepileptic use. Early recognition and stopping of the drugs with use of granulocyte colony-stimulating factor led to the successful management of the patient.

Keywords
- febrile neutropenia
- neurointensive care settings
- traumatic brain injury

Introduction

Patients presenting to a trauma acute care setting often have neurological deficits secondary to traumatic brain injury (TBI), which necessitates antiepileptics for seizure prophylaxis. Neutropenia is a rare side effect of many of these drugs and may be seen when multiple antiepileptics are given together. The occurrence of febrile neutropenia can have an adverse effect on the outcome of these patients, especially if it is not picked up early and the drug is not stopped. We describe here a patient who was managed successfully by utilizing colony-stimulating factors and prompt recognition and discontinuation of the culprit drugs.

Case Report

A 15-year-old adolescent boy presented following TBI after a roadside accident to advanced trauma center of our tertiary care hospital. The primary survey revealed airway compromise for which the patient was intubated. Breathing and circulation, as well as other vital signs, were preserved. The patient had a Glasgow coma scale score of 8/15 and bilateral pupils were 2.5 mm in size and equally reactive. The neck was stabilized using cervical collar on arrival in view of GCS score of 8/15 till the cervical spine was cleared. A noncontrast computed tomography (CT) scan of the head revealed right and left cerebellar hemorrhages with multiple dot contusions over bilateral frontal lobes with a left sylvian fissure subarachnoid hemorrhage, Marshall grading 2. The patient was shifted to the trauma intensive care unit (ICU) for further management. On day 2 of injury, the patient had multiple episodes of generalized tonic–clonic seizures and focal seizures despite receiving sodium phenytoin as seizure prophylaxis. Magnetic resonance imaging was done, which revealed hemorrhagic contusions in the right frontal, frontotemporal, and bilateral cerebellar hemispheres, with micro-hemorrhages in the left frontal, temporal, and basifrontal regions with grade II diffuse axonal injury. In view of ongoing seizure activity, phenytoin was stopped and levetiracetam was started, and carbamazepine and sodium valproate were added. Despite three antiepileptic drugs, the patient had status epilepticus for which midazolam infusion was started. After control of seizure activity, clobazam was added on day 9. During his hospital stay, the patient developed fever, which was associated with a decreasing total leukocyte count and absolute neutrophil count with sterile blood, urine, and tracheal cultures. The leucocyte count decreased from 10,000 to 4,000/µL to as low as 300/µL with a corresponding neutrophil count of 6,200, 2,100, and 30/µL, respectively. This was also accompanied by a

DOI https://doi.org/10.1055/s-0044-1789205.
ISSN 2348-0548.

Thieme Medical and Scientific Publishers Pvt. Ltd., A-12, 2nd Floor, Sector 2, Noida-201301 UP, India

reduction in hemoglobin and platelet counts to a nadir of 6.6 g/dL and 34,000/µL, respectively. Timeline of leucocyte count and antiepileptics has been depicted in ►**Fig. 1**. A repeat set of tracheal, blood, and urine cultures was sent and the patient was started on empirical antibiotics meropenem and vancomycin in view of febrile neutropenia. With a possibility of drug-induced severe neutropenia and pancytopenia, carbamazepine and sodium valproate were stopped and granulocyte colony-stimulating factor (GCSF) was started. The subsequent tracheal cultures grew *Staphylococcus aureus*, and antibiotics were changed according to sensitivity. However, despite culture-driven antibiotics, the patient continued to be febrile with temperature ranging from 40 to 42°C. Repeat cultures showed growth of *Pseudomonas* and *Acinetobacter* in the tracheal cultures, and antibiotics were upgraded to injection colistin according to sensitivity. Simultaneously, the leukocyte count started showing an improving trend after discontinuation of carbamazepine and sodium valproate, as well as institution of GCSF. The patient responded to antibiotics and was weaned off the ventilator on day 31 of ICU stay and shifted back to the ward for planning long-term care.

Discussion

Patients admitted in the ICU are more at risk of polypharmacy in comparison to other patients in the hospital.[1] Due to the polypharmacy, as well as an increased incidence of organ dysfunction (such as hepatic and renal failure) in these patients, they are also at a higher risk of unwanted drug interactions and adverse effects. Neutropenia has been reported as a side effect of multiple drugs, with antibiotics and antiepileptics being commonly used in the ICU. In addition, sepsis may also lead to leukopenia and neutropenia, which can further exacerbate the drug side effects. Drug-induced neutropenia is infrequently recognized in the ICU setting, and most information is derived from oncology patients presenting with febrile neutropenia to the ICU.[2] As such, the data for nononcological patients with drug-induced neutropenia and febrile neutropenia are limited, particularly in the ICU and TBI setting. While multiple drugs, as well as severe sepsis, can contribute to the development of pancytopenia and severe neutropenia, based on published literature, as well as the temporal improvement in cytopenias after stopping carbamazepine and sodium valproate, we believe these two drugs to be the most likely culprit drugs in our case.

Febrile neutropenia has been associated with a mortality risk between 10 and 20% depending on risk factors.[3] GCSF is recommended in patients with severe neutropenia at admission into the ICU.[4] GCSF use has been shown to reduce the duration of neutropenia, as well as days of hospitalization and antibiotic use in patient with drug-induced neutropenia and agranulocytosis.[5] Most of the data for use of GCSF are in the setting of cancer patients with chemotherapy-induced

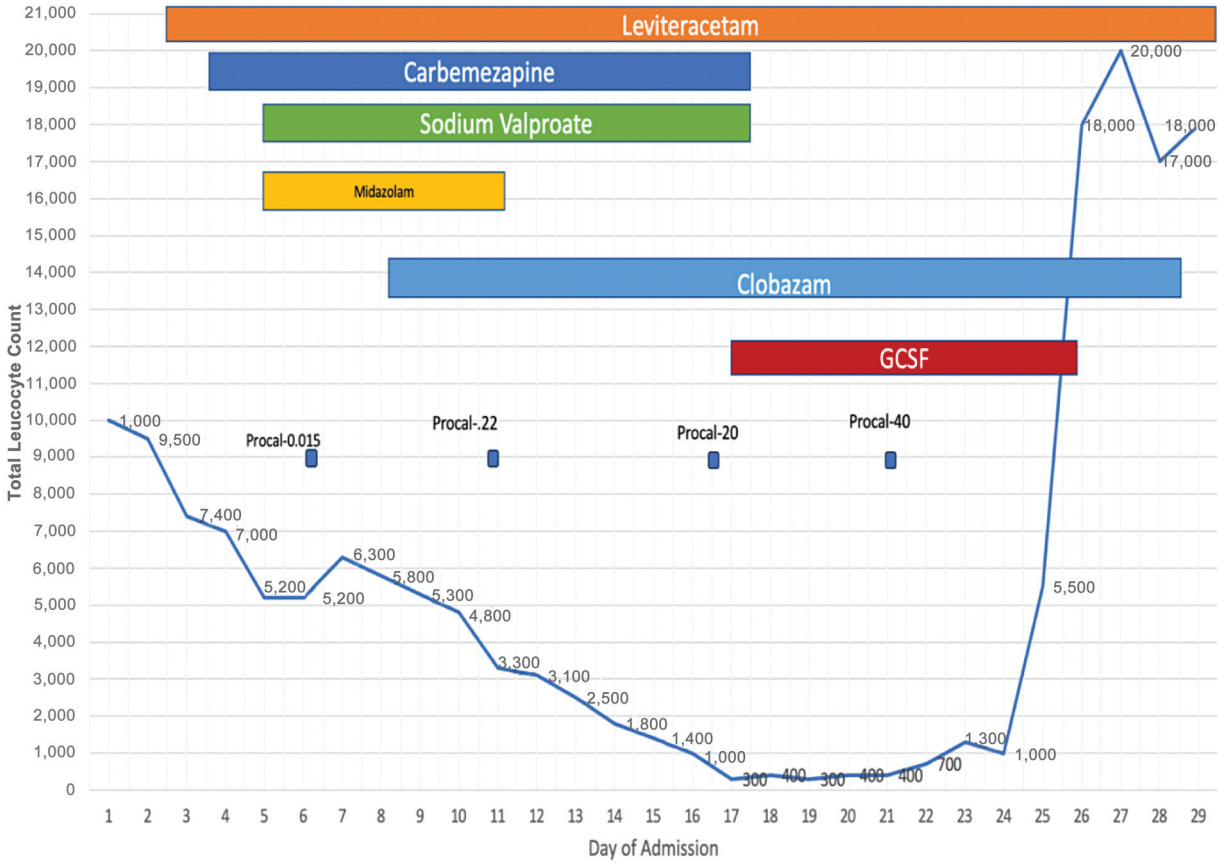

Fig. 1 Timeline depicting total leucocyte count, antiepileptics, procalcitonin levels, and antibiotics. GCSF, granulocyte colony-stimulating factor.

neutropenia. However, GCSF may also be utilized in patients with neutropenia due to other drugs to hasten count recovery and shorten hospital stay.[6] GCSF use can be associated with worsening pulmonary function and hence all pros and cons should be weighed before its use in patients with sepsis, especially if the focus is a pneumonia.

This case showcases a rare adverse event in the form of severe neutropenia and pancytopenia to drugs commonly used in neurointensive care setting. The intensive care team must be aware of drug interactions and such rare adverse events, as they can worsen outcomes if not recognized early. Prompt discontinuation of the offending drug is essential to ensure early count recovery. GCSF may be utilized in these conditions, especially in settings of severe neutropenia, to hasten neutrophil recovery.

Conflict of Interest

None declared.

References

1 Tahmasebivand M, Soltani F, Kouti L, et al. Frequency and risk factors of polypharmacy and drug interactions among patients in general intensive care unit of Golestan Hospital, Ahvaz, southwest of Iran. AIMS Med Sci 2020;7:69–78

2 Stephens RS. Neutropenic fever in the intensive care unit. In: Nates JL, Price KJ, eds. Oncologic Critical Care. Cham: Springer International Publishing; 2020:1297–1311

3 Sereeaphinan C, Kanchanasuwan S, Julamanee J. Mortality-associated clinical risk factors in patients with febrile neutropenia: a retrospective study. IJID Reg 2021;1:5–11

4 Schnell D, Azoulay E, Benoit D, et al. Management of neutropenic patients in the intensive care unit (NEWBORNS EXCLUDED) recommendations from an expert panel from the French Intensive Care Society (SRLF) with the French Group for Pediatric Intensive Care Emergencies (GFRUP), the French Society of Anesthesia and Intensive Care (SFAR), the French Society of Hematology (SFH), the French Society for Hospital Hygiene (SF2H), and the French Infectious Diseases Society (SPILF). Ann Intensive Care 2016;6(01):90

5 Andrès E, Maloisel F, Zimmer J. The role of haematopoietic growth factors granulocyte colony-stimulating factor and granulocyte-macrophage colony-stimulating factor in the management of drug-induced agranulocytosis. Br J Haematol 2010;150(01): 3–8

6 Mhaskar R, Clark OA, Lyman G, Engel Ayer Botrel T, Morganti Paladini L, Djulbegovic B. Colony-stimulating factors for chemotherapy-induced febrile neutropenia. Cochrane Database Syst Rev 2014;2014(10):CD003039

