




# Long-Term Outcome of Surgery for Grade 4 Gynecomastia: A Single-Center Experience

Aakanksha Goel<sup>1</sup>  Sudhanshu Punia<sup>1</sup> Amit Gupta<sup>1</sup>

<sup>1</sup>Department of Aesthetic Surgery, Divine Aesthetic Surgery, New Delhi, India

**Address for correspondence** Dr. Aakanksha Goel, MBBS, MS, DrNB, MNAMS, House No. 1, Sukh Vihar, Delhi 110051, India (e-mail: goelaakanksha@hotmail.com).

Indian J Plast Surg

## Abstract

**Background** Gynecomastia results in a feminine appearance of the male chest, leading to social embarrassment and loss of self-esteem in the afflicted males. Grade 4 gynecomastia is expected to have less than perfect results with liposuction and gland excision alone. This study was done to assess the long-term outcome of this surgery for grade 4 gynecomastia.

**Materials and Methods** From January 2021 to December 2022, 81 patients with grade 4 gynecomastia were treated by us. All the patients underwent vibration amplification of sound energy at resonance (VASER) and suction-assisted liposuction of the chest and side rolls with excision of the gland with crescentic lift in the cases with ptosis. A retrospective study was done to analyze the long-term surgical outcomes in these patients by review of clinical records.

**Results** Symmetry was achieved in 37/39 patients with grade 4a gynecomastia but only in 33/42 patients with grade 4b gynecomastia. The inframammary fold disappeared in 35/39 patients with grade 4a gynecomastia but only in 25/42 of grade 4b gynecomastia patients. Ptosis was corrected in 35/42 grade 4b gynecomastia patients. The mean follow-up was 15 months (range: 12–24 months). Only seven patients desired a second stage to correct the remaining deformity.

**Conclusion** Liposuction with gland removal alone in grade 4a gynecomastia and with liposuction with crescentic nipple–areola complex (NAC) lift in patients of grade 4b gynecomastia give satisfactory results in patients with massively enlarged breasts. While grade 4a gynecomastia has overall better results and lesser complications as compared with grade 4b gynecomastia, the latter also has acceptable outcomes. Realistic prognosis needs to be explained to the patient preoperatively.

## Keywords

- ▶ gynecomastia
- ▶ liposuction
- ▶ obesity
- ▶ severe grade

## Introduction

Gynecomastia results in a feminine appearance of the male chest, leading to social embarrassment and loss of self-esteem in the afflicted males.<sup>1,2</sup> Severest forms of gynecomastia (grade 4) are expected to have less than perfect

results with liposuction and gland removal alone. Although many male breast reduction techniques similar to those for women have been described,<sup>3–7</sup> most male patients do not accept more than a minimal scar on their chest, especially in populations where scarring can be hypertrophic or prone to pigmentary changes, such as those with darker skin tone.

DOI <https://doi.org/10.1055/s-0044-1789005>.  
ISSN 0970-0358.

© 2024. Association of Plastic Surgeons of India. All rights reserved. This is an open access article published by Thieme under the terms of the Creative Commons Attribution-NonDerivative-NonCommercial-License, permitting copying and reproduction so long as the original work is given appropriate credit. Contents may not be used for commercial purposes, or adapted, remixed, transformed or built upon. (<https://creativecommons.org/licenses/by-nc-nd/4.0/>)  
Thieme Medical and Scientific Publishers Pvt. Ltd., A-12, 2nd Floor, Sector 2, Noida-201301 UP, India

This study assessed the long-term outcome of liposuction and gland excision surgery for patients with grade 4 gynecomastia.

## Material and Methods

A retrospective study was done by evaluation of clinical records and photographs of all patients who underwent surgery for grade 4 gynecomastia at our institution from January 2021 to December 2022 to analyze the surgical outcome, especially with respect to symmetry, ptosis, and disappearance of the inframammary fold. The hospital is a high-volume center for gynecomastia surgeries, operating on 500 cases (approximately) annually. The current photographs were taken during follow-up visits or were sent by patients via email. The Punia and Gupta classification (►Table 1) was used to define grade 4 as severe enlargement of the breast (>750 g lipoaspirate).<sup>8</sup> Grade 4a cases had severe breast enlargement without significant ptosis. Grade 4b cases had severe breast enlargement with significant ptosis, needing a lift procedure for the nipple–areola complex (NAC; marking shown in ►Supplementary Fig. S1, available in the online version). Patients were also asked if they desired a second stage for correction of residual deformities.

Preoperative workup included routine hematology investigations along with hormonal profile. All the patients underwent vibration amplification of sound energy at resonance (VASER) and suction-assisted liposuction of the chest and side rolls with excision of the gland, with crescentic lift of the NAC in grade 4b gynecomastia. No reduction in size of the NAC was done. While no drains were placed in grade 4a gynecomastia, suction drains (16 gauge) were always inserted in grade 4b gynecomastia electively at the time of surgery. The patient is discharged with the drain and called for drain removal on postoperative day 4. Pressure garments were advised to be worn starting from the first

postoperative day for a period of 6 to 8 weeks. Massage was started after 2 to 3 weeks of surgery for 3 to 4 months.

At the time of long-term follow-up, we asked the patients to score if they were satisfied or dissatisfied and wanted a surgery for correction of residual deformities.

## Results

From January 2021 to December 2022, 81 patients with grade 4 gynecomastia were operated on at our center. This included 39 patients classified as 4a gynecomastia (no ptosis) and 42 patients classified as 4b gynecomastia (with ptosis). The mean age of the patients was 35 years, and the mean weight was 97.4 kg. The average body mass index (BMI) was 33.1 kg/m<sup>2</sup>. Thus, all the patients were obese at the time of surgery. ►Table 2 shows the average fluid infiltrated, amount of lipoaspirate, and gland excised on each side.

Most of the complications were seen in patients with grade 4b gynecomastia. Seroma occurred in 8/42 (19%) patients, hematoma in 1/42 (2%), wound dehiscence in 10/42 (23.8%), and partial necrosis of the NAC in 4/42 (9.5%) patients. The seromas were managed by aspiration and compression. The hematoma needed evacuation. Wounds were managed conservatively with dressings alone. These complications were not seen in patients with grade 4a gynecomastia. No infection was noted in any case, especially in grade 4b gynecomastia due to use of drains. In total, 7/81 grade 4 gynecomastia patients showed hypopigmentation of part of the NAC, which resolved spontaneously in 3 to 6 months.

It was noted that skin contracts significantly after liposuction. The NAC also reduces in size spontaneously. Symmetry was achieved in 37/39 grade 4a gynecomastia patients (►Figs. 1 and 2) but only in 33/42 of grade 4b gynecomastia patients. The inframammary fold disappeared in 35/39 grade 4a gynecomastia patients but only in 25/42 of grade 4b gynecomastia patients (►Figs. 3–6). Ptosis was corrected in 35/42 grade 4b gynecomastia patients. The mean follow-up was 15 months (range: 12–24 months). Only seven patients desired a second stage to correct the remaining deformity.

**Table 1** Summary of Punia and Gupta classification of gynecomastia

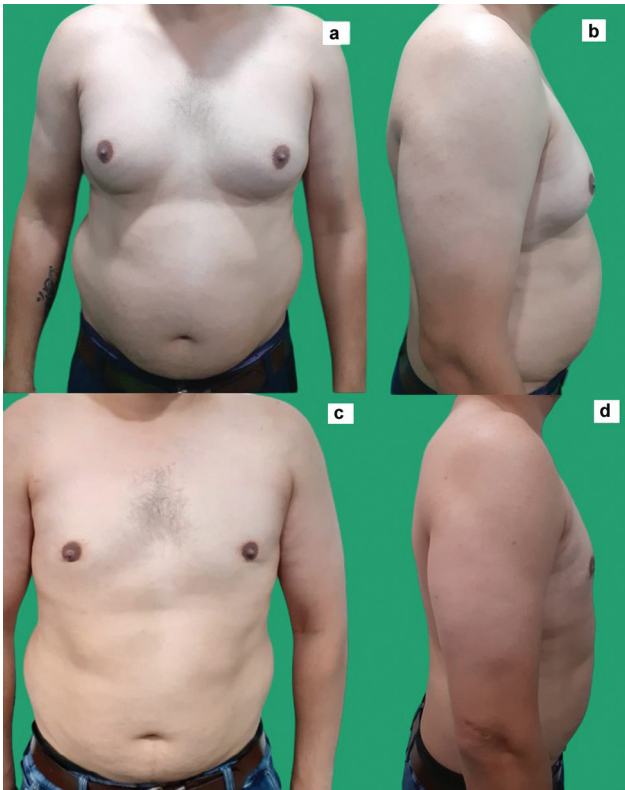Grade	Description
1a	Puffy nipple with no obvious problem except stretched areola with a button-type feel
1b	Minor breast enlargement with <250 mL fat, higher amount of fibroglandular tissue
2a	Moderate breast enlargement with fat component between 250 and 500 g. No ptosis
2b	Same as 2a with ptosis
3a	Large breast enlargement (500–750 mL fat) with side rolls without ptosis
3b	Same as 3a, with ptosis
4a	Severe breast enlargement (>750 mL fat) without significant ptosis + axillary rolls + side rolls
4b	Same as 4a, with significant ptosis

## Discussion

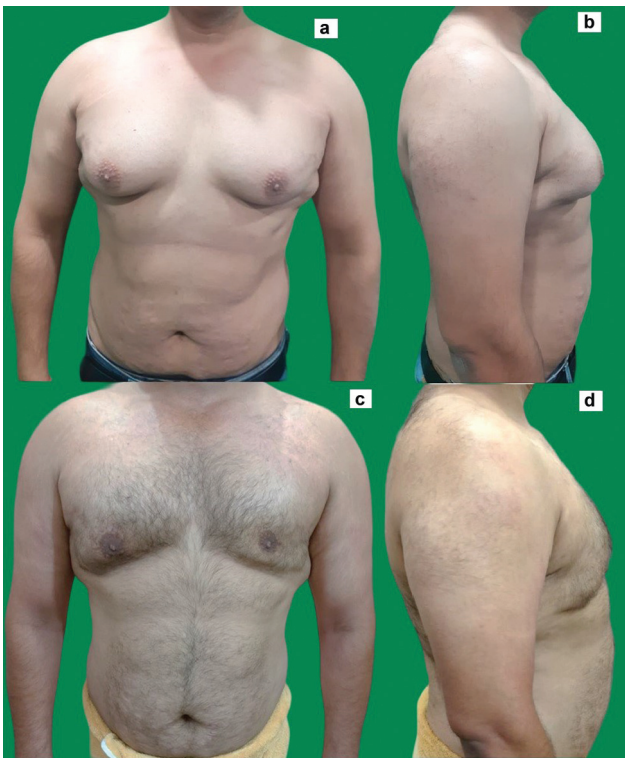Liposuction with near-total gland removal is the procedure of choice for gynecomastia surgery in most aesthetic surgery centers globally.<sup>9</sup> The goals of any gynecomastia surgery include smooth transition to surrounding subcutaneous tissues, absence of loose skin, appropriate size and position of the NAC, and minimal scars. Liposuction and pull-through

**Table 2** Fluid infiltrated versus fat aspirated and weight of excised gland from each side

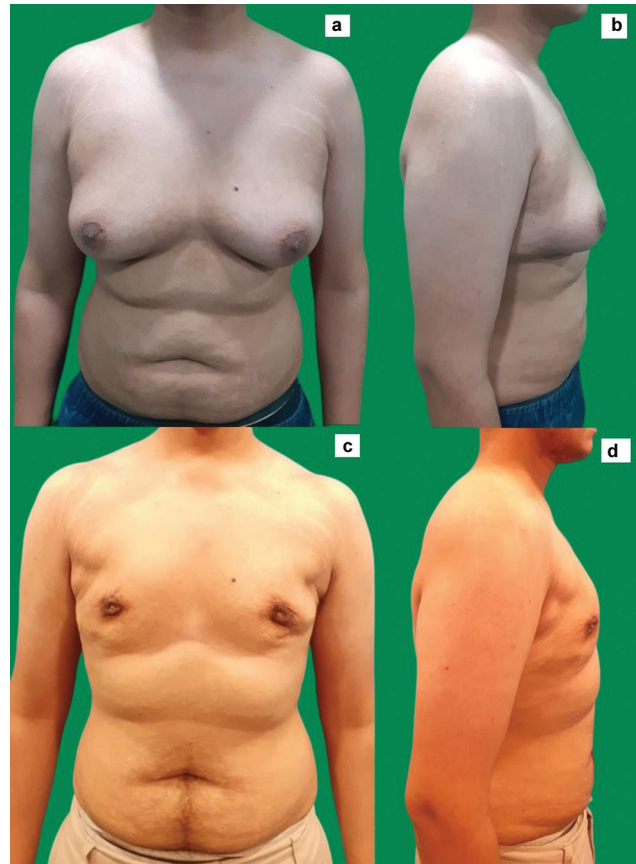Fluid infiltrated (each side)	1.96 L
Fat aspirated (each side)	1.7 L
Weight of excised gland (each side)	78 g



**Fig. 1** (a,b) Preoperative and (c,d) postoperative photographs of a patient with grade 4a gynecomastia. The skin has retracted completely and the inframammary fold (IMF) is obliterated.



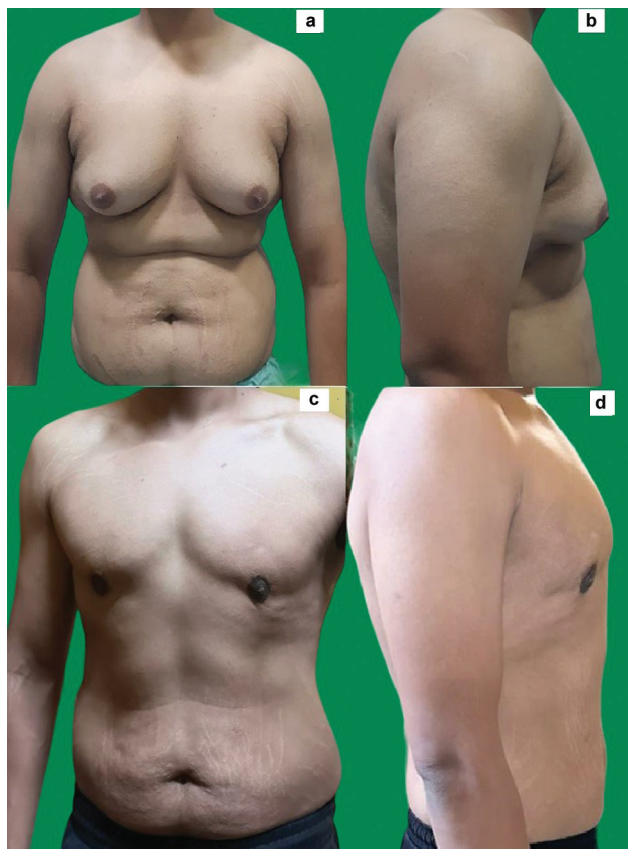**Fig. 2** (a,b) Preoperative and (c,d) postoperative photographs of a patient with grade 4a gynecomastia. Although the skin has retracted greatly, there still is some amount of skin excess.



**Fig. 3** (a,b) Preoperative and (c,d) postoperative photographs of a patient with grade 4b gynecomastia. He has a very good quality skin, which has retracted completely. Scars of the nipple-areola complex (NAC) lift are barely visible.

of gland through an infra-areolar incision allows a minimally invasive approach to the chest causing least visible scars with an excellent result in the lower grades. However, it is not universally accepted as the procedure of choice for severest grades of gynecomastia. To the best of our knowledge, there is no study in the literature that discusses the long-term outcomes of treatment of grade 4 gynecomastia. Although we used the Gupta and Punia classification for its objectivity, these cases are similar to Rohrich's grade 4 gynecomastia and the readers may use either of them.

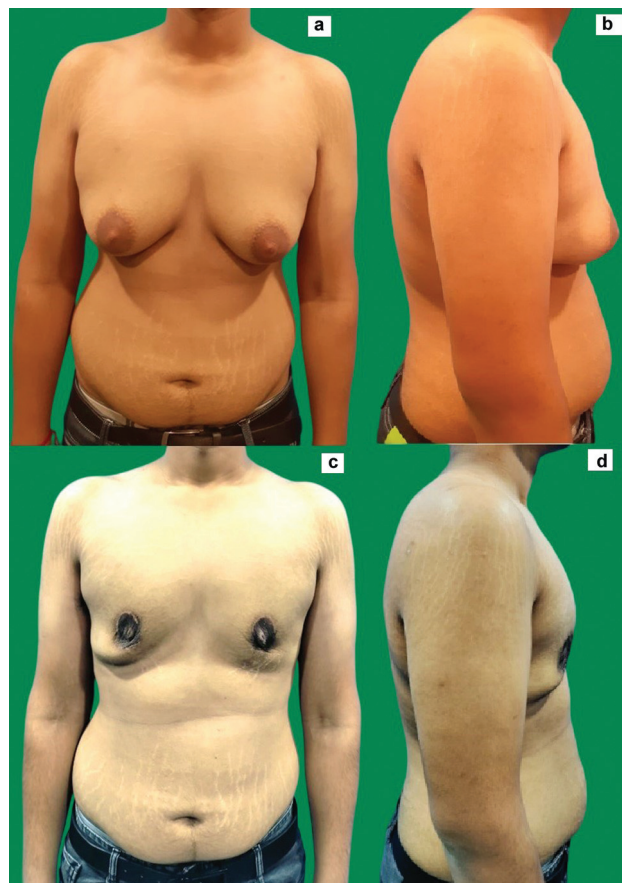The incidence of severe gynecomastia seems to be on the rise with increase in obesity in the population, more so in the young adult population. Gynecomastia occurs due to an imbalance of sexual hormones synthesized in adrenals. An increased level of estrogen and resistance to, or decreased levels of, testosterone favor growth of breast tissue in men.<sup>10</sup> Obesity leads to overall increase in subcutaneous fatty tissue, which further leads to increased estrogen levels due to peripheral conversion of androgens to estrogens. Thus, with raised BMI, some grade of gynecomastia is usually present. In our study, all the patients were seen to be obese, and thus they all had a higher grade of gynecomastia. Innocenti et al described three body types of patients who want gynecomastia surgery. In their experience, patients who were overweight were less concerned with scars and feminine appearance of the chest and primarily wanted to



**Fig. 4** (a,b) Preoperative and (c,d) postoperative photographs of a patient with grade 4b gynecomastia. Please note the excellent retraction of skin, especially after his weight loss and fitness journey.

lose weight.<sup>11</sup> However, all our patients were very much concerned about a femalelike chest and postsurgical scars and their minimization.

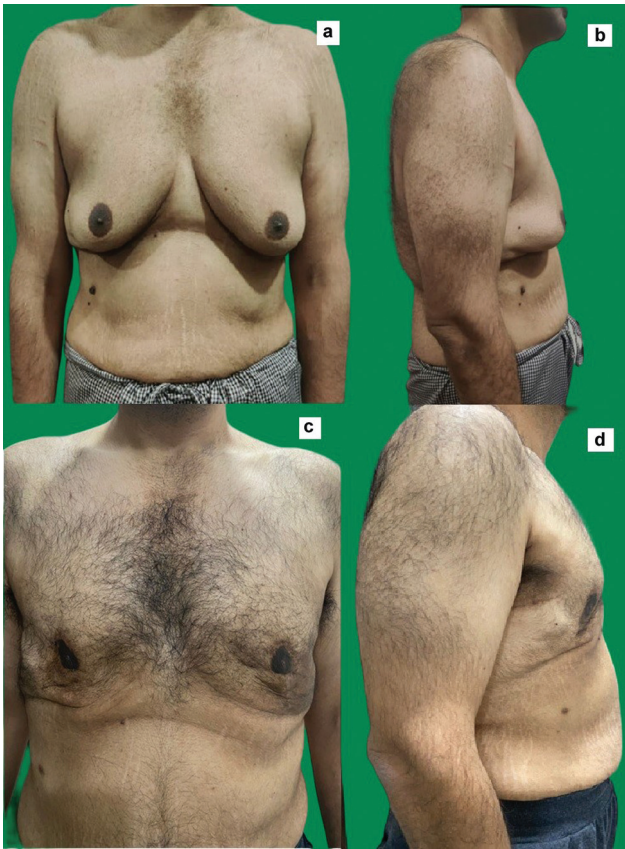Skin contraction is usually known to occur over a period of 6 months to even 1 year after liposuction.<sup>9,12</sup> VASER liposuction is known to preserve elastic connective tissue and dermis, leading to skin retraction.<sup>9</sup> The larger the volume of liposuction, the longer the time taken for skin retraction.<sup>13</sup> Due to this, the authors believe that a second stage to excise extra skin should be planned at least 6 to 9 months later. Similar view is held by other surgeons as well.<sup>14</sup> Mett et al did liposuction and gland removal for grade 2b gynecomastia where they noted that skin contracts in 3 months. However, for the largest grades they continued to do reduction with inferior pedicle and horizontal scars across the chest.<sup>4</sup> Abdelwahab et al also measured skin retraction at 3 months postsurgery in grade 3 gynecomastia and found significant skin retraction and repositioning of the NAC.<sup>15</sup> Ramasamy et al measured the amount of skin contraction after liposuction and gland excision objectively.<sup>16</sup> The measurements were done preoperatively and at 6 months postoperatively. Significant retraction of skin, elevation of the NAC, and reduction in area of the NAC were seen in all grades of gynecomastia, with maximum changes in severe grades of gynecomastia. However, the study does not mention residual skin laxity and other outcome parameters for grade 4 gynecomastia patients.



**Fig. 5** (a,b) Preoperative and (c,d) postoperative photographs of a patient with grade 4b gynecomastia. Skin has contracted significantly but loose skin around the inframammary fold (IMF) persists.

The rate of complications with liposuction in gynecomastia surgery has been reported to be from 3 to 30%.<sup>4,10,17</sup> In our study, grade 4a gynecomastia did not see any complications, while the incidence of different complications ranged from 2 to 24% in grade 4b gynecomastia patients. Most of these were managed conservatively. Only one needed re-exploration for evacuation of hematoma. Thus, we can conclude that higher grades of gynecomastia do not cause greater complications with liposuction and gland excision procedure. However, grade 4b gynecomastia has a significantly higher rate of complications compared with grade 4a gynecomastia.

We prefer to put negative suction drains in all grade 4b gynecomastia patients for 4 days as it facilitates skin flap adherence to the chest wall, further leading to lesser incidence of seroma. Decreased incidence of clinically relevant seromas was seen after drain placement in gynecomastia surgery by Chao et al.<sup>18</sup> Boccaro et al did not observe any seromas without drains in lower grades, which has been our experience as well.<sup>19</sup> In the initial few cases of grade 4b gynecomastia operated by us, where the drain was not inserted, seroma and subsequent superficial skin necrosis and wound dehiscence occurred. We took immediate corrective action and started inserting drains electively and did not have similar complications thereafter. The drain is exited

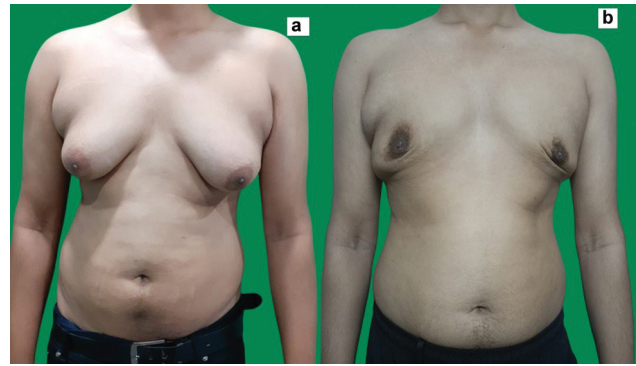


**Fig. 6** (a,b) Preoperative and (c,d) postoperative photographs of a patient after massive weight loss with grade 4b gynecomastia. Although skin was thin with poor quality and large number of stretch marks, skin retraction was achieved to near absence of loose skin and disappearance of the inframammary fold (IMF).

through the axillary incision and no infection caused by drains was noted by us in our series. The patients remained comfortable and no analgesics needed to be added beyond those administered to patients who did not have a drain (grade 4a). It has been noted by the authors that even early removal of the drain leads to increased incidence of seroma. The purpose of drain insertion by us is not to prevent hematomas. Although some studies suggest that drains do not have any added advantage in a gynecomastia surgery, they either have a lower grade of gynecomastia or a very small number of cases.<sup>20,21</sup>

We did not do circumferential peri-areolar mastopexy or decrease the size of the NAC surgically in the first surgery itself for better preservation of vascularity to the NAC as there is extensive undermining in severe gynecomastia. Moreover, it is difficult to predict the exact amount of retraction of skin (→ Fig. 7) and too much or too little excision can lead to malposition of the NAC, which is difficult to be corrected later, especially if placed too high on the chest.

Of the 81 patients operated upon by us, 11 were adolescents aged 16 to 18 years. Pinelli et al studied gynecomastia in 18 adolescents.<sup>22</sup> They operated on 18 grade II (Simon's classification) patients, although the title of their publication



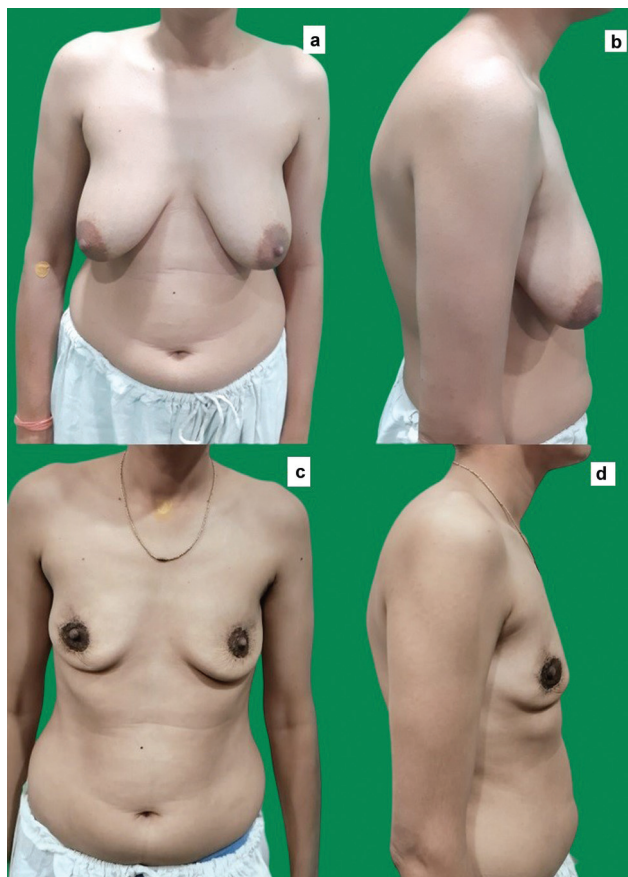**Fig. 7** Retraction of skin is quite unpredictable. Not all results are great. (a) Preoperative and (b) postoperative photographs of a patient with grade 4b gynecomastia. There is persistent postoperative asymmetry, leading to both patient and surgeon distress.

mentions “severe” gynecomastia. They used liposuction and round block de-epithelization with peri-areolar mastopexy to treat the excess skin while minimizing the scar while treating the excess skin. Ramasamy et al used a plaster technique of lifting the NAC postoperatively by using adhesive tape pulling in two different directions for a week.<sup>23</sup> It was a retrospective study and very mild ptosis was shown in the photographs. Absence of controls is a major limitation in the study. A randomized case control study is needed to prove that it is indeed of any significance or it is the biophysical properties of the skin alone, which are causing contraction and retraction of skin.<sup>23</sup> The same author in another publication mentions that some severe gynecomastia may still need tackling of excess skin.<sup>24</sup> Mett et al performed male breast reduction procedures for grade 4 gynecomastia, which led to conspicuous scarring on the chest, which was quite bothersome to the patients.<sup>4</sup>

Although results of VASER liposuction and gland removal procedures are not excellent in grade 4 gynecomastia, patients readily accept the results. Even if the residual deficits are correctable by surgery, most patients do not go ahead with them. This is because the feminine appearance of the chest is removed. Hence, the patients regain self-confidence and the taboo is no longer there. The authors believe that management of severe gynecomastia using techniques resulting in large scars across the chest are unwarranted/an overkill in the first stage. After skin retraction, a second-stage surgery with smaller skin excision and smaller scars is possible (→ Fig. 8).

## Conclusion

Even on long-term follow-up, liposuction with gland excision in the most severe grades of gynecomastia leaves a lot of redundant skin. However, most patients do not wish to undergo a second-stage surgery to correct the residual deformities. Grade 4a gynecomastia has overall better results and lesser complications as compared with grade 4b gynecomastia. Realistic prognosis needs to be explained to the patient preoperatively.



**Fig. 8** (a,b) Preoperative photographs of a patient with grade 4b gynecomastia with very severe ptosis. (c,d) Postoperative photographs after the second stage of peri-areolar skin excision. Minimal scars are seen and the patient is satisfied.

**Note**

This paper was presented by Dr. Aakanksha Goel at APSICON 2023, Indore on December 30, 2023.

**Funding**

None.

**Conflict of Interest**

None declared.

**References**

- 1 Kim DH, Byun IH, Lee WJ, Rah DK, Kim JY, Lee DW. Surgical management of gynecomastia: subcutaneous mastectomy and liposuction. *Aesthetic Plast Surg* 2016;40(06):877–884
- 2 Song YN, Wang YB, Huang R, et al. Surgical treatment of gynecomastia: mastectomy compared to liposuction technique. *Ann Plast Surg* 2014;73(03):275–278
- 3 Ibrahiem SMS. Severe gynecomastia: new technique using superior pedicle NAC flap through a circumareolar approach. *Ann Plast Surg* 2016;76:645–651
- 4 Mett TR, Pfeiler PP, Luketina R, Bingöl AS, Krezdorn N, Vogt PM. Surgical treatment of gynecomastia: a standard of care in plastic surgery. *Eur J Plast Surg* 2020;43:389–398

- 5 Arvind A, Khan MA, Srinivasan K, Roberts J. Gynaecomastia correction: a review of our experience. *Indian J Plast Surg* 2014;47(01):56–60
- 6 Holzmer SW, Lewis PG, Landau MJ, Hill ME. Surgical management of gynecomastia: a comprehensive review of the literature. *Plast Reconstr Surg Glob Open* 2020;8(10):e3161
- 7 Brown RH, Chang DK, Siy R, Friedman J. Trends in the surgical correction of gynecomastia. *Semin Plast Surg* 2015;29(02):122–130
- 8 Punia S, Gupta A. A new clinical classification for gynecomastia management and predictive outcome. *Indian J Plast Surg* 2023;56(04):332–337
- 9 Hurwitz DJ, Davila AA. Contemporary management of gynecomastia. *Clin Plast Surg* 2022;49(02):293–305
- 10 Zavlin D, Jubbal KT, Friedman JD, Echo A. Complications and outcomes after gynecomastia surgery: analysis of 204 pediatric and 1583 adult cases from a national multi-center database. *Aesthetic Plast Surg* 2017;41(04):761–767
- 11 Innocenti A, Melita D, Mori F, Ciancio F, Innocenti M. Management of gynecomastia in patients with different body types: considerations on 312 consecutive treated cases. *Ann Plast Surg* 2017;78(05):492–496
- 12 Dixit VV, Wagh MS. Unfavourable outcomes of liposuction and their management. *Indian J Plast Surg* 2013;46(02):377–392
- 13 Dhami LD. Liposuction. *Indian J Plast Surg* 2008;41(Suppl):S27–S40
- 14 Bailey SH, Guenther D, Constantine F, Rohrich RJ. Gynecomastia management: An evolution and refinement in technique at UT southwestern medical center. *Plast Reconstr Surg Glob Open* 2016;4(06):e734
- 15 Abdelwahab A, Eleowa S, Khalifa M. Assessment of skin redraping after liposuction in treatment of gynecomastia grade III Simon's classification. *Al Azhar Int Med J* 2021;2(07):79–86
- 16 Ramasamy K, Shet SM, Patil P, Tripathee S, Dhevi N, Alagarasan AR. Anthropometric measurements and analysis for objective assessment of gynecomastia surgery results. *Aesthet Surg J Open Forum* 2023;5:ojad073
- 17 Innocenti A, Melita D, Dreassi E. Incidence of complications for different approaches in gynecomastia correction: a systematic review of the literature. *Aesthetic Plast Surg* 2022;46(03):1025–1041
- 18 Chao JW, Raveendran JA, Maly C, Rogers G, Boyajian M, Oh AK. Closed-suction drains after subcutaneous mastectomy for gynecomastia: do they reduce complications? *Aesthetic Plast Surg* 2017;41(06):1291–1294
- 19 Boccara D, Serror K, Malca N, Chaouat M, Mimoun M. Closed-suction drains after subcutaneous mastectomy for gynecomastia: do they reduce complications? a different approach. *Aesthetic Plast Surg* 2018;42(03):908–910
- 20 Keskin M, Sutcu M, Cigsar B, Karacaoglan N. Necessity of suction drains in gynecomastia surgery. *Aesthet Surg J* 2014;34(04):538–544
- 21 Chao JW, Raveendran JA, Maly C, Rogers G, Boyajian M, Oh AK. Closed-suction drains after subcutaneous mastectomy for gynecomastia: do they reduce complications? *Aesthetic Plast Surg* 2017;41(06):1291–1294
- 22 Pinelli M, De Maria F, Ceccarelli P, et al. Surgical management of adolescents with severe gynecomastia: personal experience and outcome analysis. *Acta Biomed* 2023;94(02):e2023055
- 23 Ramasamy K, Jagadish Kiran ACV, Jesudass J, Raj S. NAC plaster lifting technique for the management of skin redundancy in severe gynecomastia. *Plast Reconstr Surg Glob Open* 2022;10(05):e4339
- 24 Ramasamy K, Tripathee S, Murugesh A, Jesudass J, Sinha R, Alagarasan AR. A Single-center experience with gynecomastia treatment using liposuction, complete gland removal, and nipple areola complex lifting plaster technique: a review of 448 patients. *Aesthet Surg J Open Forum* 2023;5:ojac095