



The Keystone Design Perforator Flap: A Flap to Simplify Complex Reconstructive Issues

Camilla Bonetti¹ Sergio Arleo² Luigi Valdatta³ Gianpaolo Faini⁴

¹Division of Plastic and Reconstructive Surgery, Department of Biotechnology and Life Sciences, University of Insubria, Ospedale di Circolo e Fondazione Macchi, Varese, Italy

²Department of Plastic Reconstructive Surgery, ASST Valle Camonica, Esine, Brescia, Italy

³Division of Plastic and Reconstructive Surgery, Department of Biotechnology and Life Sciences, University of Insubria, Ospedale di Circolo e Fondazione Macchi, Varese, Italy

⁴Department of Plastic Reconstructive Surgery, ASST Valle Camonica, Esine, Brescia, Italy

Address for correspondence Camilla Bonetti, MD, Division of Plastic and Reconstructive Surgery, Department of Biotechnology and Life Sciences, University of Insubria, Ospedale di Circolo e Fondazione Macchi, Viale Luigi Borri, 57, 21100, Varese, Italy (e-mail: Camilla.bonetti94@hotmail.com).

Indian J Plast Surg

Abstract

Background The keystone design perforator island flap (KDPIF) was first described by Behan in 2003 as a pliable flap, suitable for all body areas thanks to its curvilinear shape, which made it apt to fit mostly all cutaneous defects.

Materials and Methods In this article, we aim to share our experience using KDPIF for the reconstruction of different defects. A retrospective analysis of patients who underwent cutaneous excision after trauma or tumor resection and reconstruction with a KDPIF at our department from 2020 to 2023 was performed. Patients' characteristics, indications, and operative and postoperative details were analyzed.

Results There was no complete flap loss. One patient experienced partial flap loss without exposure to major structures and needed skin grafting.

Conclusion Mapping of the perforators makes the keystone flap even more manageable, with the possibility to safely stretch and modify its design according to individual necessities.

Keywords

- ▶ keystone flap
- ▶ local flaps
- ▶ perforators

Introduction

The keystone design perforator flap was first described by Behan¹ in 2003 as a trapezoid island flap based on a random vasculature consisting of perforators running along the major axis of the flap. The major advantages presented in Behan's first presentation regarded its adjustability and easy dissection and the fact that it allows closing cutaneous defects with reduced tension. These features made the keystone flap a workhorse in limb and trunk reconstruction from the very

beginning. Since then, it has been widely modified to make it suitable for different reconstructive demands.²⁻⁷

The design of the keystone flap requires the defect to be elliptical-shaped, with the long axis parallel to the cutaneous nerves, veins, and arteries from which the cutaneous perforators detach. The skin adjacent to the defect is bluntly dissected respecting the 1:1 (width of the defect:width of the flap) ratio and advanced until wound approximation is reached. When required, a deep fascial incision along the outer border of the flap provides further advancement.

DOI <https://doi.org/10.1055/s-0044-1788990>.
ISSN 0970-0358.

© 2024. Association of Plastic Surgeons of India. All rights reserved. This is an open access article published by Thieme under the terms of the Creative Commons Attribution-NonDerivative-NonCommercial-License, permitting copying and reproduction so long as the original work is given appropriate credit. Contents may not be used for commercial purposes, or adapted, remixed, transformed or built upon. (<https://creativecommons.org/licenses/by-nc-nd/4.0/>)

Thieme Medical and Scientific Publishers Pvt. Ltd., A-12, 2nd Floor, Sector 2, Noida-201301 UP, India

In the last few years, this easy-to-harvest island flap has gained increasing popularity in the fields of both posttraumatic and postoncologic resection reconstruction. The keystone design perforator island flap (KDPIF) is indeed suitable for covering wide full-thickness soft-tissue defects that would otherwise require more time-consuming free or myocutaneous flaps, still providing functional and aesthetically pleasant results.

This article aims to present a single-center experience with this type of flap, highlighting its great pliability and versatility. Here are described some modifications we have adopted to make the KDPIF safer and a valid competitor to more challenging flaps. In particular, the major objective of this retrospective study was to underline how a flap (which has always been considered based on random vasculature) could easily become a perforator flap to meet peculiar reconstructive demands. Knowing the exact location of perforators allows the surgeon to undermine a larger portion of the flap without the fear of injuring the vascular supply, providing a better resurfacing of a cutaneous defect.

Materials and Methods

Patients with skin defects who underwent reconstructive surgery using a KDPIF from January 2020 to May 2023 at our department were retrospectively reviewed. Given the retrospective nature of the study, approval of the ethical committee was not necessary. All patients enrolled in the study had signed an informed consent prior to surgery. Demographic data (age, sex, characteristics of skin defects, comorbidities, smoking habits), type of KDPIF, postoperative complications, wound dressing, and follow-up were revised. All the patients underwent accurate surgical debridement of the wound before preparing the flap. Four KDPIFs were used to reconstruct the lower leg area, 2 for the neck region, 1 for the shoulder, 1 for the fourth finger of the hand, 1 for the ischiatic area, 4 for the skin overlying the Achilles tendon, and 1 for

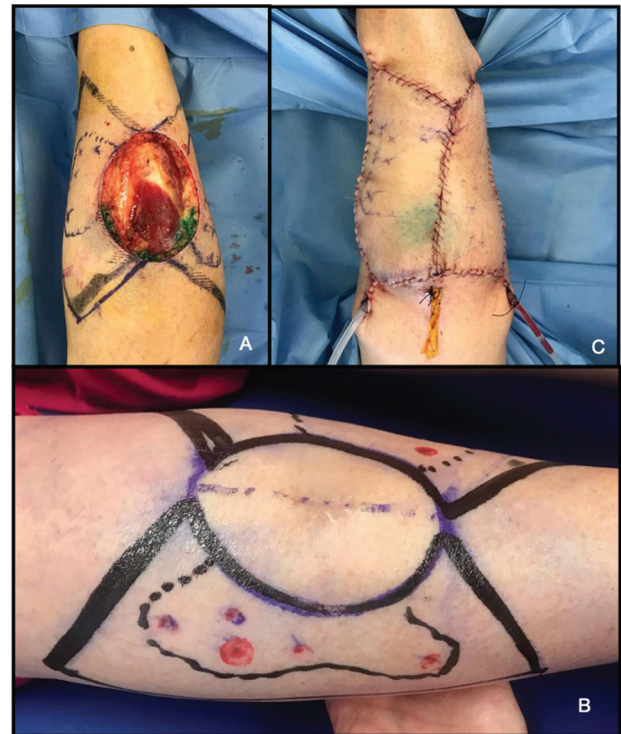

Fig. 2 (A) Postradicalization tissue defect. Detail of the underlying Achilles tendon. (B) Preoperative marking of the type III keystone design perforator island flap (KDPIF) before radicalization of a Merkel cell carcinoma of the Achilles tendon region in a 62 year old man. The perforators were marked as red dots. (C) Immediate postoperative. Two suction drainages in place.

the skin overlying the knee. The average defect size was 15.9 cm² (range: 2–48 cm²). All classical KDPIF variants were utilized: type IIA was the most frequent (6 patients, 46.2%), followed by type IV (3 patients, 23.1%; ► **Fig. 1**), then type IIb (1 patient, 7.7%), type III (1 patient, 7.7%; ► **Fig. 2**), and type I (1 patient, 7.7%). Patients' demographics are listed in ► **Table 1**.

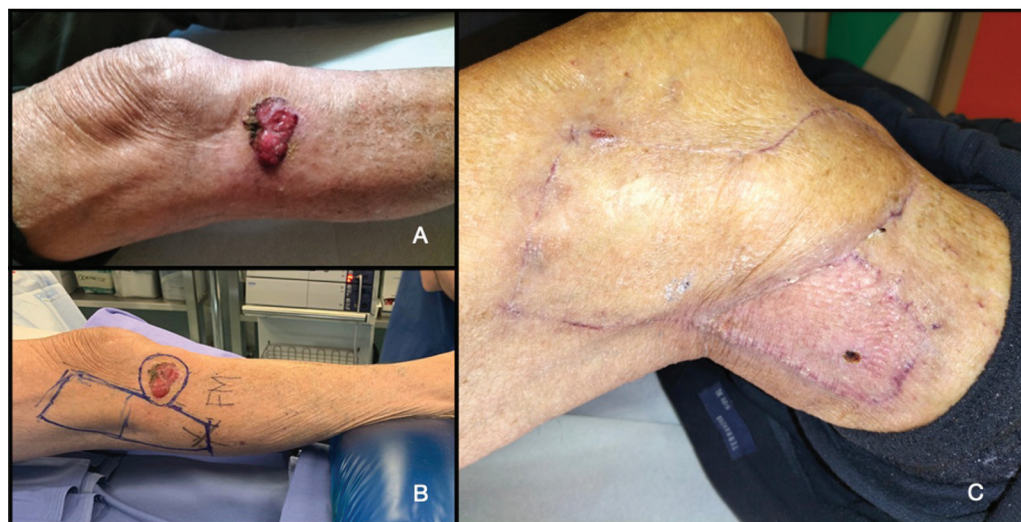

Fig. 1 (A) Ulcerated lesion (which later was diagnosed as a squamous cell carcinoma) of the lateral subpatellar region in an 87-year-old man. (B) Flap marking; type IV keystone design perforator island flap (KDPIF). (C) Picture of the fully healed lesion at the 1-month follow-up.

Table 1 Patients' characteristics and demographics

Age (y)	Sex	Indication	Body area	Comorbidities	Complications	Keystone type	Tissue loss dimension (cm ²)
34	M	Caustic burn	Shoulder	None	Partial posterior dehiscence	IIA	48
14	M	Retractive scar	4th finger—hand	None	None	IV (no skin graft)	2
79	M	Basal cell carcinoma	Neck	IHD	Partial posterior dehiscence	IIA	25
48	M	Pressure ulcer	Ischiatic	None	None	IIA	12
87	M	Squamous cell carcinoma	Lateral leg (proximal one-third)	None	None	IV (with skin graft)	20
48	M	Chronic osteomyelitis	Anterior leg (lower one-third)	None	None	IIA	18
80	M	Basal cell carcinoma	Lateral-anterior leg	DM, hypertension	Minimal dehiscence	IIA	6
74	M	Basal cell carcinoma	Neck	None	None	IIA	22
75	F	pT1 sarcoma	Achilles' tendon region	DM, hypertension	Partial flap loss	IV (with skin graft)	21
73	M	Hardware exposure	Knee	hypertension	None	IV (with skin graft)	10
62	M	Tendon exposure	Achilles' tendon region	None	None	IV (with skin graft)	4
83	F	Basal cell carcinoma	Lateral leg	None	None	IA	6
62	M	Merkel's cell carcinoma	Achilles' tendon region	None	None	III	16

Complications were divided into major (complete or partial flap loss) and minor (wound dehiscence and wound infection). All the patients were dismissed from the hospital within 10 days with bland analgesics (nonsteroidal anti-inflammatory drugs [NSAIDs], acetaminophen). The minimum follow-up period was 30 days.

Each patient underwent preoperative evaluation and selection of suitable perforators near the defect to treat and the flap marked upon, using a handheld ultrasound (US) color Doppler probe (Clarius L20 20 MHz).

This preoperative study of the perforators allowed us to model better the flap preserving its original shape, while also giving us the confidence to undermine the flap as needed or to even skeletonize the perforators when deemed necessary.

The surgery was performed under local anesthesia plus sedation or general anesthesia. Even when the tumors or cutaneous defects were located on the limbs, we did not use a tourniquet. The excisions were designed elliptical and the markings were done taking into account the size and location of the evaluated perforators. Possibly, dissection of the deep fascia was avoided and the perforator area was preserved with no need to fully skeletonize the perforators. Resorbable sutures (Monocryl 2–0 and 3–0) were used for skin closure of the double lateral V-Y advancements and for closing the outer

curvilinear line. The “front” of the flap was closed using a monofilament, nonresorbable suture (Prolene). Three patients were treated with Negative Pressure Therapy (NPT) applied above surgical incisions and skin grafted areas (where present) for 7 days postoperatively at a pressure of –90 mm Hg, whereas the majority of patients were treated with classical wound dressing. Antibiotic ointment (fusidic acid) was used daily for 15 days on sutures only. No antibiotic therapy was administered a priori.

Results

The analysis of our medical records reported a total of 13 patients treated with a KDPIF from January 2020 to May 2023. The average age was 63 years (range: 14–87 years), and all the patients were nonsmokers. Six patients (46.2%) suffered from hypertension, ischemic heart disease, or diabetes. Basal cell carcinoma (Basal Cell Carcinoma [BCC]) excision was the most frequent cause (30.8%), followed by previous trauma (23.8%), decubitus ulcer (7.7%), retractive scar correction (7.7%), squamous cell carcinoma (Squamous Cell Carcinoma [SCC]) excision (7.7%), sarcoma resection (7.7%), Merkel's cell carcinoma radicalization (7.7%), and knee hardware exposure (7.7%). As regards posttraumatic

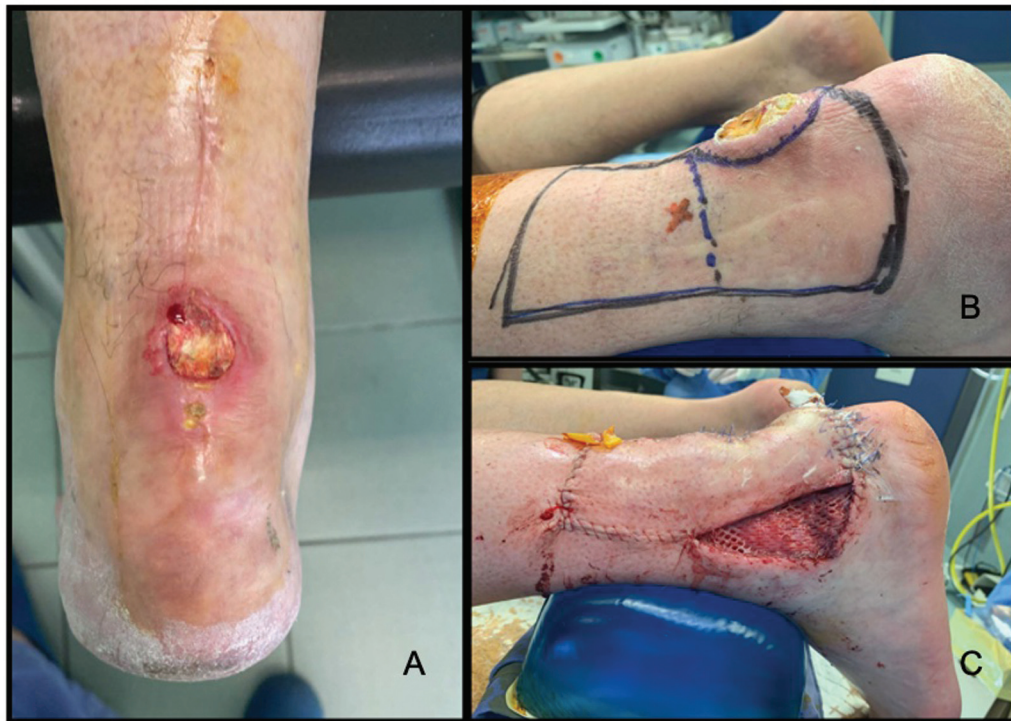


Fig. 3 (A) Preoperative picture of wound dehiscence after surgical tendon repair in a 62-year-old man. (B) Marking of the type IV keystone design perforator island flap (KDPIF) with evidence of the main perforator (red cross). The dotted line separates the part of the flap that will be raised underneath the fascia (right side) from the one that will remain mostly untouched (to preserve the perforator). (C) Immediate postoperative picture shows the details of the grafted donor site. The split-thickness skin graft was meshed 1:1.5.

reconstructions, one patient was treated for a third-degree caustic burn of the shoulder, one patient experienced wound dehiscence and Achilles' tendon exposure after surgical tendon repair (► Fig. 3), and another patient had a chronic ulcer of the lower leg (► Fig. 4). The follow-up ranged from 7 to 36 months, with a mean follow-up period of 13 months. Minor complications occurred in three cases (23.1%) and did not compromise the overall outcome. They were treated with local wound care and no patient required hospitalization or surgical revision. We experienced one major complication (7.7%) in a patient in which the KDPIF was used to resurface the Achilles tendon area. The flap suffered from partial superficial necrosis and required surgical revision and coverage with a split-thickness skin graft. Notably, the patient suffered from diabetes and did not strictly stick to the given directions. Details regarding complication rates and management are specified in ► Table 2.

Discussion

Unlike free flaps or perforator flaps, the KDPIF is simple in its dissection and does not require any preoperative imaging. Behan first described four variations of the flap, each one suited for specific reconstructive issues. Type I does not allow fascia dissection and is suitable for defects up to 2 cm in width; type IIA is ideal for greater cutaneous defects located over muscular compartments since the deep fascia has to be dissected along the outer curvature of the flap; type IIB differs from type IIA for the grafting of the donor area in body

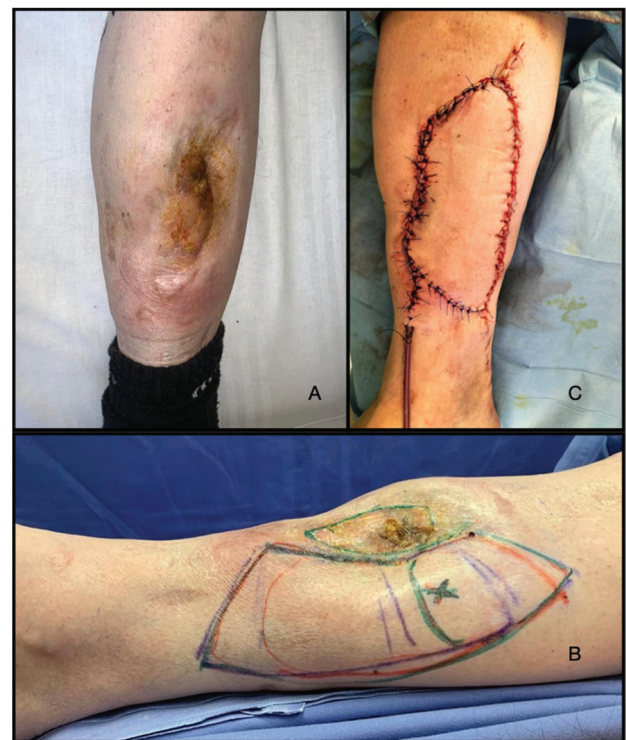

Fig. 4 (A) Preoperative picture of a chronic wound with underlying chronic osteomyelitis of the anterior region of the leg in a 48-year-old man. (B) Marking of the type IV keystone design perforator island flap (KDPIF) with evidenced of the main perforator (green cross). (C) Immediate postoperative. One suction drainage in place.

Table 2 Complication rates and details

Postoperative complication	N (%)	Body region	Management
Major complication	1 (7.7%)		
Complete flap loss	–	–	
Partial flap loss	1 (7.7%)	Achilles' tendon region	NPT, toilette + skin graft
Minor complication	3 (23.1%)		
Wound dehiscence	2 (15.4%)	Shoulder, lower leg	Local wound care
Wound infection	1 (7.7%)	Neck	Local wound care, oral antibiotics

regions where excess tension cannot be mitigated; type III is chosen when resurfacing larger cutaneous defects (up to 10 cm) since it consists of two juxtaposed keystone design flaps. Type IV facilitates resurfacing of joints since it may be raised with subfascial undermining up to 50% of its size.

Several other modifications, as the omega variant and the Sydney Melanoma Unit variation, have been described during the last decade.⁸

In this article, we have illustrated how it is possible to adapt the KDPIF to everyday surgical practice. The additional Doppler study of the nearby perforators prior to surgery allows surgeons to perfectly tailor the flap and makes it safer by identifying and thus preserving vascular supply, nevertheless avoiding pedicle dissection. This procedure is not vital for a positive outcome when using this flap, but we still prefer to perform it since it is easy and not time-consuming, and it allows surgeons to perform a more reliable procedure in body regions where the paucity of blood supply represents a major problem. We deem the keystone flap particularly adequate when there is the need to resurface wide cutaneous defects quickly and easily, especially in patients in which microvascular flaps are not an option.^{9,10}

Even if we usually think about the KDPIF as the first reconstructive option when feasible, we also recommend it as a great backup flap for secondary reconstruction or in combination with other regional flaps to overcome reconstructive challenges.¹¹

Key points about skin reconstruction with a KDPIF are listed:

- It is “easy to design” and can adapt to different reconstructive demands. It is therefore a very approachable flap, especially for young surgeons and institutions for which a more complex flap might become challenging. Unlike perforator flaps, the KDPIF does not have a steep learning curve and can be easily tailored on the patient.¹²
- Microscope and microsurgical instruments are not needed, which means that there is no need for a microsurgery-experienced surgeon, either. Nevertheless, the lack of magnification does not make the KDPIF a “hazardous” flap: the reliability of blood supply lies on its design and orientation, which allow random perforators to be included in the skin island. This theory was first formulated and confirmed by Milton in 1971,¹³ when he published the experiments that gave him the idea that a cutaneous pedicle was not only unnecessary but also possibly detrimental to

flap survival. From these first studies, Behan could conceive of an island flap that was sufficiently wide to contain enough perforators and with a design that evenly distributes tension forces.

- There is no need to skeletonize perforators. This can be a tedious procedure that sometimes engages surgeons for a great amount of time. The KDPIF does not rely on a single perforator, so its design is easy and this translates into a reduction of operating and surgical planning time.
- It can be adapted to almost every region of the body. Several authors have described its use not only for limb and trunk reconstruction but also for resurfacing soft-tissue defects located on the face, hands, and feet,¹⁴ slightly modifying the original markings.^{15–17} Although the KDPIF is a naturally “thin” flap (its harvesting does not include muscle masses), it can be in part de-epithelialized, buried, and grafted to fill deeper defects.
- The KDPIF is perfectly suitable for lower limb reconstruction.^{4,6} The paucity of alternatives makes it a workhorse flap when it comes to resurfacing soft-tissue defects in these body areas, in particular above the joints. The amount of subcutaneous tissue included in the KDPIF is usually sufficient to protect noble structures, without providing the annoying bulky effect that is typical of myocutaneous flaps. This also means that refining “touch-up” surgeries are usually not necessary, leading to easier and quicker recovery and, consequently, swifter access to rehabilitation and normal mobilization.
- The lymphatic drainage is somehow preserved despite the island nature of this flap. Probably, blunt dissection preserves a part of the deep lymphatic drainage and this, combined with the incision of the superficial cutaneous lymphatics, might lead to a lymphangiogenetic stimulus that may guide a quicker-than-usual restoration of the lymphatic flow. This leads to an extremely rare incidence of pincushioning and trap-door deformity, and the postoperative flap swelling is greatly minimized.
- The KDPIF is a flap with both a low rate of major and minor complications that are easily treated most of the times. Furthermore, for this type of reconstruction, flap loss can be considered a rare event.

We were able to achieve excellent results with various types of KDPIF applied to different reconstructive demands across the entire body surface. The main limitations of this study are represented by the small sample size and the

different applications of this typology of flap. Results may vary according to the location and the size of the defect to be reconstructed; specifically, we would not recommend the use of the KDPIF when reconstructing defects located on the face because of the major risk of distortion of aesthetically relevant structures. As described earlier, we routinely use this flap in case of upper and lower limb reconstruction as well as for covering defects located on the thorax or above mobile joints.

Conclusion

The KDPIF is suitable for all body areas “from the scalp to the feet” thanks to its curvilinear shape, which made it apt to resurface mostly all cutaneous defects consequent to tumor resection or trauma. Together with preoperative US-assisted planning, we deem this flap very versatile and safe, a real workhorse flap if not the first choice in selected cases.

Ethical Approval

Permission of the Ethic Committee was not necessary due to the retrospective nature of the study.

Authors' Contributions

All the authors have made a substantial contribution to the concept of the article, equally cooperating on the drafting and revisions of the article, giving their precious opinion and contributing with their own personal experience. The final version of this article was approved by all of the authors. All the authors agree to be accountable for all aspects of the work presented here.

Funding

None.

Conflict of Interest

None declared.

References

- Behan FC. The keystone design perforator island flap in reconstructive surgery. *ANZ J Surg* 2003;73(03):112–120
- Moncrieff MD, Thompson JF, Stretch JR. Extended experience and modifications in the design and concepts of the keystone design island flap. *J Plast Reconstr Aesthet Surg* 2010;63(08):1359–1363
- Hassani M, Hertess I, Tucker S, Coetzer-Botha M, Kittler H, Rosen-dahl C. The UQ flap: a novel modification of the keystone flap. *Plast Reconstr Surg Glob Open* 2022;10(10):e4619
- Rao AL, Janna RK. Keystone flap: versatile flap for reconstruction of limb defects. *J Clin Diagn Res* 2015;9(03):PC05–PC07
- Petukhova TA, Navrazhina K, Minkis K. V-Y hemi-keystone advancement flap: a novel and simplified reconstructive modification. *Plast Reconstr Surg Glob Open* 2020;8(02):e2654
- Huang J, Yu N, Long X, Wang X. A systematic review of the keystone design perforator island flap in lower extremity defects. *Medicine (Baltimore)* 2017;96(21):e6842
- Yushan M, Hamiti Y, Yalikun A, Lu C, Yusufu A. Clinical application of keystone design perforator island flap (KDPIF) in trunk defects: a retrospective study. *ANZ J Surg* 2022;92(09):2280–2285
- Moncrieff MD, Bowen F, Thompson JF, et al. Keystone flap reconstruction of primary melanoma excision defects of the leg—the end of the skin graft? *Ann Surg Oncol* 2008;15(10):2867–2873
- Monarca C, Rizzo MI, Sanese G. Keystone flap: freestyle technique to enhance the mobility of the flap [corrected]. *ANZ J Surg* 2012; 82(12):950–951
- Lo Torto F, Frattaroli JM, Kaciulyte J, et al. The keystone flap: a multi-centric experience in elderly patients treatment. *J Plast Reconstr Aesthet Surg* 2022;75(01):226–239
- Mohan AT, Rammos CK, Akhavan AA, et al. Evolving concepts of keystone perforator island flaps (KPIF): principles of perforator anatomy, design modifications, and extended clinical applications. *Plast Reconstr Surg* 2016;137(06):1909–1920
- Demir A, Kucuker I, Keles MK, Demirtas Y. The effect of learning curve on flap selection, re-exploration, and salvage rates in free flaps; a retrospective analysis of 155 cases. *Microsurgery* 2013;33(07):519–526
- Milton SH. Experimental studies on island flaps. 1. The surviving length. *Plast Reconstr Surg* 1971;48(06):574–578
- Lim SY, Yoon CS, Lee HG, Kim KN. Keystone design perforator island flap in facial defect reconstruction. *World J Clin Cases* 2020; 8(10):1832–1847
- Virág TH, Kadar IA, Matei IR, Georgescu AV. Surgical management of hidradenitis suppurativa with keystone perforator island flap. *Injury* 2020;51(Suppl 4):S41–S47
- Rini IS, Gunardi AJ, Yashinta KJ, et al. Quality of life in palliative post-mastectomy reconstruction: keystone versus rotational flap. *Plast Reconstr Surg Glob Open* 2021;9(03):e3457
- Kim KH, Yoo BW, Lim SY, et al. Modified keystone perforator island flap for tension-reducing coverage of axillary defects secondary to radical excision of chronic inflammatory skin lesions: a retrospective case series. *BioMed Res Int* 2022;2022:5600450