



Building a Stronger Backbone: 3D Printing's Role in Treating Spinal Cord Conditions

Arwa Jader^{1,2} Barbara Buccilli^{1,3} Danisha Kumar^{1,4} Oday Atallah^{1,7} Luqman Munir^{1,6}
Yasser F. Almealawy^{1,5} Michelle Ennabe^{1,8} Neil Joshi⁹ Urooj Imdad¹⁰ Albert Alan^{1,9}
Martin Weinand⁹

¹ Global Neurosurgical Alliance, Phoenix, Arizona, United States

² Neurosurgery Department, Kufa University, Kufa, Iraq

³ Department of Neurosurgery, Icahn School of Medicine at Mount Sinai, New York, New York, United States

⁴ Department of Neurosurgery, Hannover Medical School, Hannover, Germany

⁵ Faculty of Medicine, University of Kufa, Kufa, Iraq

⁶ King Edward Medical University, Lahore, Pakistan

⁷ Hannover Medical School, Hannover, Germany

Asian J Neurosurg

Address for correspondence Albert Alan, BS, BA, BSHS, Department of Neurosurgery, University of Arizona, P.O. Box 245070, 1501 N Campbell Avenue, Room 4303, Tucson, AZ 85724-5070, United States (e-mail: AlbertAlan@arizona.edu).

⁸ University of Arizona College of Medicine, Phoenix, Arizona, United States

⁹ Department of Neurosurgery, University of Arizona, Tucson, Arizona, United States

¹⁰ National Hospital for Neurology and Neurosurgery, Queen Square, London

Abstract

Spinal cord injuries (SCIs) pose significant challenges as complete nerve regeneration remains limited. The demand for improved technologies in SCI treatment is evident. One such emerging technology is three-dimensional printing (3DP), which, coupled with advancements in medical imaging and bioengineering, has significantly enhanced precision in surgical procedures. This systematic review aims to explore 3DP as a treatment option for SCIs, examining its cost, efficacy, safety, and the associated technological constraints. A systematic search of Medline was conducted through PubMed for literature published since 2019. The search results were exported to Rayyan for abstract and full-text screening following predefined criteria. The risk of bias in the selected studies was assessed using the RoB2 tool and the Newcastle-Ottawa Scale. From a total of 89 articles screened, 11 studies met the eligibility criteria, collectively assessing 237 individuals with various types of SCIs, including lumbar degeneration, en bloc resection of thoracolumbar metastasis, adult spinal deformity, and cervical degeneration. These studies examined the utilization of 3DP devices such as hand orthosis, interbody fusion cages, lamellar titanium cages, artificial vertebral bodies, and others. Most of the reviewed studies reported positive treatment outcomes, with the actual procedure costs varying from \$65 to \$5,000. Recent literature shows positive outcomes in the use of 3DP technologies for SCIs, highlighting its potential for enhancing both surgical and nonsurgical interventions. These advancements usher in a new era in SCI treatment, providing enhanced precision and a wider range of treatment options, ultimately leading to more comprehensive and effective patient care.

Keywords

- ▶ 3D bioprinting
- ▶ SCI surgery
- ▶ bioengineering
- ▶ cost-efficiency
- ▶ neuroregeneration

DOI <https://doi.org/10.1055/s-0044-1788916>.
ISSN 2248-9614.

© 2024. Asian Congress of Neurological Surgeons. All rights reserved.

This is an open access article published by Thieme under the terms of the Creative Commons Attribution-NonDerivative-NonCommercial-License, permitting copying and reproduction so long as the original work is given appropriate credit. Contents may not be used for commercial purposes, or adapted, remixed, transformed or built upon. (<https://creativecommons.org/licenses/by-nc-nd/4.0/>)

Thieme Medical and Scientific Publishers Pvt. Ltd., A-12, 2nd Floor, Sector 2, Noida-201301 UP, India

Introduction

Spinal cord injury (SCI) is considered to be one of the most challenging central nervous system injuries. The serious complications and high rates of paraplegia caused by SCIs have brought a great burden to individuals, families, and society.¹ As nerve cells become damaged or degenerate, they cannot be repaired on their own the way other cells do, and this can lead to lifelong loss of function. From a pathological perspective, there are two main causes of SCI: primary injury and secondary injury. The primary injury occurs primarily as acute injuries caused by mechanical forces such as extrusion and dislocation, which cause damage to neurons or glial cells in corresponding sections that result in hemorrhage.² Secondary injury can be relatively complicated and have multiple potential mechanisms, including local edema, ischemia, free radical excess, and intense inflammatory responses.³ Furthermore, differentiation of neurons is influenced by both primary and secondary injury. These changes can lead to cystic lesions, while astrocyte proliferation leads to the formation of scar tissue.⁴ The formation of dermal scar tissue also prevents the regeneration of neurons, leading to the loss of natural sensation and volitional action.⁴

At present, the clinical treatment of SCI is mainly divided into nonsurgical treatment and surgical treatment. One of the nonsurgical treatments for SCIs is postinjury shock therapy with excessive doses of methylprednisolone (MP).⁵ MP is a corticosteroid that inhibits the peroxidation of lipids. It also reduces the inflammatory response, protects the blood-brain barrier of the spinal cord, and increases the vascular flow to the injured spine when employed as a scavenging agent for free radicals. However, some adverse effects limit the use of this medicine, as its therapeutic benefits are also controversial, including an increased risk of urinary tract, respiratory, and wound infections.⁶ Decompression and fixation have always been the most important techniques for the surgical treatment of SCIs. Eliminating compression factors and restoring spinal structure to the most stable state is a key aim of SCI therapy.⁷ Some progress has been made in repairing SCIs with these methods; however, at the present time, all clinical treatment techniques can only address injury factors to a limited extent and are not yet capable of creating functionally functional nerve regeneration. It is therefore concluded that the injury has not been repaired to its full extent.⁸

The three-dimensional printing (3DP) approach to health care and surgery has come a long way since its introduction, with an apparent increase in interest only over the last several years. It is currently regarded as one of the most recent and sophisticated tools in orthopaedic surgery. To improve the precision and reproducibility of surgical techniques, 3DP is widely promoted and applied in a wide range of orthopaedic subdisciplines. This has been possible due to parallel advances made both in medical imaging and bioengineering (► **Fig. 1**). The demand for the technology is only going to increase with more and more emerging technologies that are becoming available on a day-to-day basis.⁹ It is most frequently used for complicated regions, such as spine

or pelvic surgery, which can be seen with the increasing number of articles available in recent years.¹⁰ The literature relating to 3DP in spine care is largely based on case reports and series of cases, although there has been some progress over the last decade. However, the technology of 3DP is expensive, time-consuming, and requires specialized personnel and equipment. In addition, its use has been restricted to specialist centers of care due to strict regulations in place.¹¹

This review aims to provide a brief introduction to this technology and draw attention to the existing evidence that underpins various spine care applications. Additionally, it includes discussions on the limitations of 3DP technology and the challenges it faces for further expansion.

Materials and Methods

PICOT

- Population (P): This systematic review focuses on adults aged 18 years and above with degenerative spinal cord conditions or SCI.
- Intervention (I): The intervention of interest is the use of 3DP technology for creating spinal implants, surgical tools, or simulating preoperative procedures.
- Comparison (C): Studies comparing 3DP technology with conventional surgical methods or non-3D-printed spinal interventions are included, as well as studies focusing on 3DP interventions.
- Outcome (O): The primary outcomes of interest include the assessment of the effectiveness, safety, and long-term outcomes of 3DP technology in treating degenerative spinal conditions. This encompasses factors such as patient recovery, postoperative complications, pain management, and the necessity for reoperation.
- Timeframe (T): The systematic review includes studies published between 2019 and 2023.

To be eligible for inclusion in this systematic review, studies were required to meet the following criteria: a population of adults aged 18 years and above who have experienced a spinal cord degenerative condition or SCI; provide data that enables the evaluation of the efficacy, safety, and enduring consequences of 3DP technology in the treatment of degenerative spinal conditions, including aspects such as patient recovery, postoperative complications, pain control, and the necessity for subsequent surgical intervention; and be published in the English language between 2019 and 2023. Study designs eligible for inclusion are randomized controlled trials (RCTs), cohort studies, longitudinal studies, and case reports.

Studies meeting any of the following criteria were excluded from the systematic review: a population of pediatric patients (age < 18 years); involving patients with diagnoses other than spinal cord conditions; do not provide data on the aforementioned outcomes; and languages other than English or published before 2019. Review articles, letters to the editor, and gray literature were excluded. Studies for which the complete text was not accessible were also excluded.

Developing a 3D *ex vivo* Peripheral Nerve Injury model

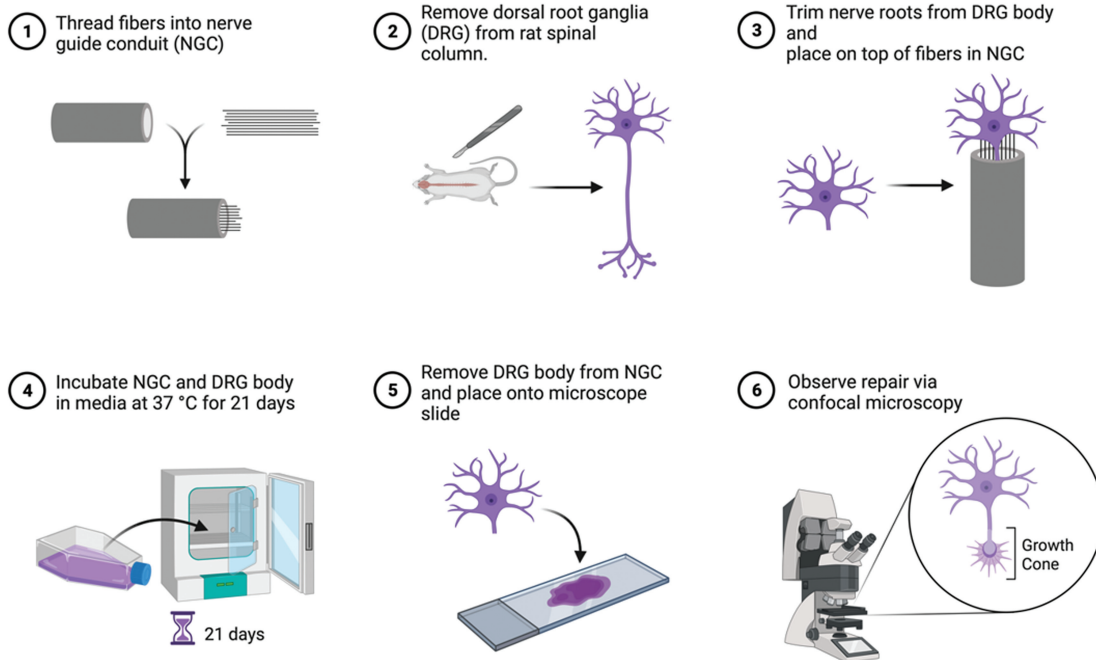


Fig. 1 This figure depicts the development of a three-dimensional (3D) *ex vivo* fiber testing model that replicates a peripheral nerve injury. This model can be used to test new materials for peripheral nerve repair. Nerve guide conduits (NGCs) are 3D printed and fibers manufactured by electrospinning are threaded into NGCs. Dorsal root ganglia are dissected and explanted on top of the NGC. The NGCs and dorsal root ganglia (DRGs) are incubated in cell culture medium for 21 days. Fibers can then be removed, immunolabeled with specific cell antigens and imaged with confocal microscopy for analysis.

Study Screening and Selection

Study screening and selection were conducted using the Rayyan software. Two independent reviewers assessed titles and abstracts for eligibility based on the inclusion and exclusion criteria outlined above. Any disagreements between reviewers were resolved through discussion or by involving a third reviewer if necessary.

Assessment of Methodological Quality and Risk of Bias

The methodological quality and risk of bias of the included studies were assessed using the Cochrane Risk of Bias 2 (RoB-2) tool and Newcastle-Ottawa Scale.

Literature Search

A comprehensive literature search was conducted in PubMed. The search strategy combined relevant keywords and Medical Subject Headings (MeSH) where applicable.

The search terms used were ((“Printing, Three-Dimensional”[MeSH]) OR (3D Printing) OR (3D bio printing)) AND ((Spinal Degenerative Disease) OR (Spinal cord injury)).

Data Extraction

A standardized data extraction form was developed and used to extract relevant information from the included studies. Data extraction covered study characteristics, participant

details, intervention descriptions, outcome measures, results, and adverse events related to 3DP.

Results

Initially, a search of the PubMed database yielded a total of 89 articles. After meticulous screening based on title, abstract, and full text, 11 studies met the inclusion criteria. The present study involved the analysis of patient-level data from various study designs, encompassing a cohort of 237 individuals with spinal cord conditions.

The average age of the patients was 51 years, with 108 individuals identified as male, accounting for 45.57% of the total sample. Only one study did not mention the male-to-female ratio. ► **Table 1** provides an overview of patient characteristics, including their initial symptoms and the duration of these symptoms. ► **Table 2** presents a comprehensive overview of the role of 3DP in managing the patients' conditions. ► **Table 3** offers a detailed overview of perioperative conditions, along with patient details regarding the duration of follow-up and prognosis.

Data provided in ► **Table 1** reveals that out of the total sample of 237 patients, 9.28% reported impaired hand function as a result of SCI.^{3,12,13} Additionally, 237 patients, making up 10.97% of the sample, cited low back pain as their presenting complaint, primarily due to metastatic epidural

Table 1 Clinical characteristics and outcomes of 237 patients across multiple studies, detailing spinal degenerative conditions, patient demographics, fusion rates, and presenting symptoms

Study ID	No. of patients	Gender (M:F)	Mean age	Spinal degenerative condition	Fusion rate	Patient presentation
Yoo 2019 ¹³	10	9:1	50.1	Spinal cord injury	–	Impaired hand function
Sun 2023 ¹⁴	26	14:12	56.5	Metastatic epidural spinal cord compression	21.50%	Low back pain
Kapadia 2021 ²⁰	8	5:3	46.7	Spinal cord injure	–	Impaired hand function
Yeh 2023 ¹²	8	6:2	34.5	Spinal cord injure	–	Impaired hand function
Shin 2021 ¹⁸	4	4:0	59.7	Severe quadriplegia	–	Quadriplegia
Jin 2021 ¹⁹	30	18:12	60.2	Cervical degeneration	100%	Cervical pain and arms
Mokawem 2019 ²¹	93	43:50	61.0	Lumber degeneration	98.8%	Low back pain and lower extremities
Petrone 2020 ¹⁶	37	–	57.9	Lumber degeneration	92.4%	Low back pain and lower extremities
Cao 2023 ¹⁷	10	5:5	55.4	Thoracolumbar metastasis	–	Low back pain and lower extremities
Segi 2023 ¹⁵	11	6:5	74.7	Lumber degeneration	–	Low back pain and lower extremities

Abbreviations: F, female; M, male.

spinal cord compression.¹⁴ A significant portion, comprising 36.71% of the patients, presented with both low back pain and lower extremity deficits.¹⁵ Among these, 130 patients suffered from lumbar degeneration,¹⁶ 10 patients had en bloc resection of thoracolumbar metastasis,¹⁷ and 11 patients suffered from lumbar degenerative disease or adult spinal deformity. A smaller percentage, 1.69%, presented with quadriplegia,¹⁸ and only 12.66% reported cervical and arm pain due to cervical degeneration.¹⁹

Based on the data provided in ► **Table 2**, it is evident that perioperative 3DP was employed for all patients. Among them, 9.28% of patients were managed with 3D-printed hand orthosis, utilizing SolidWorks, Dassault Systèmes, and France software.¹³ Preoperatively, 10.97% of patients underwent 3D simulation/3DP using reconstruction software (Mimics Innovation Suite 21.0).¹⁴ Notably, 36.71% of the patients were managed with various 3D-printed interventions, including lamellar titanium cages, preoperative surgical planning

Table 2 Overview of perioperative 3D printing interventions, including the types of 3D printing participation, materials used, associated costs, and the software employed in the management of various spinal conditions

Type of 3D printing participation	Material used for 3D printing	Cost for 3D printing	Software used
3D-printed hand orthosis	Nylon	250\$ US	SolidWorks, Dassault Systèmes, and France software
Preoperative 3D simulation/printing	–	5,000\$ US	Reconstruction software (Mimics Innovation Suite 21.0)
Rehabilitation hand function	–	2,500\$ US	GRASSP
3D-printed hand orthosis	–	65\$ US	Design Simulation Technologies
Power wheelchair joysticks	–	–	Mimics Innovation Suite 14.0 software
3D-printed interbody fusion cages	Titanium	–	–
3D-printed lamellar titanium cages	Silicate substituted calcium phosphate bone graft	–	Surgimap Spine software
Preoperative surgical simulation	–	–	Mimics Innovation Suite software
3D-printed autostable artificial vertebral body	Polylactic acid	–	Mimics Innovation Suite 17.0 software
3D-printed porous titanium cage	Titanium	–	–

Abbreviation: 3D, three-dimensional.

Table 3 Outcomes and follow-up of patients undergoing 3D printing-assisted spinal interventions, including complication rates, hospital stay durations, and intraoperative metrics. Among the sample, 26 patients had dural damage, with 82.28% achieving favorable outcomes during follow-ups ranging from 2 weeks to 2 years

Primary outcome measure	Incidence of reoperation	Intraop duration	Intraop blood loss	Hospital stay duration	Complications	Outcome	Prognosis	Follow-up
The Toronto Rehabilitation Institute Hand Function Test (TRI-HFT) and functional independence in daily living	–	–	–	–	–	Patients were satisfied with the effectiveness of orthosis	Good	–
The Toronto Rehabilitation Institute Hand Function Test (TRI-HFT)	–	2.15 ± 0.25 h	478.85 ± 125.83 mL	–	Dural damage in 11 cases	6 improvements, 18 small improvements, 2 no improvement	–	2 y
The Toronto Rehabilitation Institute Hand Function Test (TRI-HFT)	–	–	–	–	–	–	–	6 mo
Box and block test, Spinal Cord Independence Measures III questionnaire	–	–	–	–	–	Help in the early stage of G-SCI to learn and use tendinosis easily	–	2 wk
PIDA assessment; NASA-TLX index; PIADS index	–	–	–	–	–	Improvement of driving abilities and more psychological satisfaction	Good	2 wk
JOA score	0%	–	–	–	No	Restore curvature of the cervical spine	Good	65.23 ± 3.54 mo
CT and Oswestry Disability Index	2.2%	–	–	4–6 d	Intraoperative endplate damage, fracture, segmental bleeding, new pain, chest infection, thrombosis	Excellent fusion rate and ODI = 21–43	Good	12 mo
VAS score	0%	124 min	–	2.2 d	No	Excellent fusion rate	Good	32.2 mo
VAS score and Frankel grading	–	8.1 ± 2.3 h	1614.3 ± 1052.6 mL	–	Hypoesthesia, leakage of CSF	Shorter operation time, less bleeding, and faster recovery	Good	21.8 mo
Marchi classification	–	–	–	–	Thigh pain	Lower cage subsidence successfully	Good	12 mo

Abbreviations: G-SCI, cervical spinal cord injury; CSF, cerebrospinal fluid; CT, computed tomography; JOA, Japanese Orthopaedic Association; ODI, Oswestry Disability Index; NASA-TLX, National Aeronautics and Space Administration-Task Load Index; PIADS, Psychosocial Impact of Assistive Devices Scale; PIDA, Power-Mobility Indoor Driving Assessment; VAS, Visual Analog Scale.

through 3D and multiplanar reconstruction, autostable artificial vertebral bodies, and porous titanium cages. These were executed using Surgimap Spine software, Mimics (Materialise, Leuven, Belgium), and Mimics 17.0 software, respectively.^{16,17,21} A smaller proportion, 1.69% of patients, were managed with power wheelchair joysticks, employing Mimics Innovation Suite 3-matic ver. 14 (Materialise) software.¹⁶ Lastly, 12.66% of the patients received treatment involving 3D-printed interbody fusion cages.¹⁹

The data presented in **Table 3** illustrates the outcomes and follow-up of patients. Among the sample, 26 patients had dural damage, with 11 of them experiencing complications.¹⁴ Additionally, 93 patients faced complications such as intraoperative endplate damage, fracture, segmental bleeding, new pain, chest infection, and thrombosis. Only 10 patients experienced hypesthesia and cerebrospinal leakage, showing a lower incidence compared to patients who did not benefit from 3DP techniques.¹⁷ Furthermore, 11 patients had thigh symptoms,¹⁵ while 97 patients did not encounter any complications.¹⁶

Follow-up duration ranged from 2 weeks to 2 years. Note that 82.28% of the total sample had a favorable outcome.

Discussion

A 3D-printed hand orthosis was developed to improve hand function and functional independence for patients with cervical SCIs (C-SCIs).¹³ The orthosis proved effective in enhancing hand function, as indicated by significant improvements in the Toronto Rehabilitation Institute Hand Function Test (TRI-HFT) and functional independence in daily living, particularly in tasks like eating. Notably, the orthosis demonstrated cost-effectiveness, customizability, and lightweight attributes compared with alternative assistive devices, making it a promising solution for individuals with C-SCIs. A 3D-printed orthosis with a triple four-bar linkage was designed to enhance hand function and functional independence for patients with chronic C-SCIs.¹² The results revealed that the orthosis significantly improved pinch force and hand dexterity, although it did not demonstrate substantial improvements in self-care abilities. This suggests that orthosis may be especially beneficial for individuals in the early stages of chronic C-SCIs, offering them an easier means of utilizing the tenodesis grip.

The potential of 3DP in the treatment of symptomatic metastatic epidural spinal cord compression are as follows: Patients who received preoperative 3D simulation/3DP-assisted surgery exhibited favorable outcomes, including reduced operation time, lower blood loss, and decreased complications when compared with the nonsimulated group.¹⁰ While there were no significant differences in pain relief and postoperative neurological function improvement, the study highlighted that 3DP technologies can practically enhance surgical procedures for this condition.

Researchers assessed the applicability of the 3D TRI-HFT in evaluating unilateral hand gross motor function for individuals with SCIs.²⁰ The results indicated high reliability of the 3D TRI-HFT for both subacute and chronic SCI cases, with

strong correlations observed between the assessment and functional independence measures. This finding supports the utility of the 3D TRI-HFT as a reliable and valid tool for evaluating hand gross motor function, thereby facilitating more comprehensive care for individuals with SCI.

Power wheelchair driving for patients with quadriplegia by creating customized joysticks using 3DP technology has been developed.¹⁸ The results were highly encouraging as all patients showed improvements in their power wheelchair driving abilities, reporting greater satisfaction with the customized joysticks. These customized joysticks not only reduced workload and improved performance but also enhanced self-efficacy and reduced negative emotional reactions associated with disability. The study effectively demonstrated the potential of 3DP to create tailored aids, enhancing the convenience and quality of life for patients with severe disabilities.

Patients with cervical spondylotic myelopathy were investigated using 3D-printed interbody fusion cages in anterior cervical discectomy and fusion (ACDF).²⁰ The results, derived from a long-term follow-up, revealed several benefits. Patients who received 3D-printed cages experienced significant improvements in their symptoms, quality of life, neurological function, cervical curvature, intervertebral height, and fusion rate. Importantly, the study noted the safety and stability of 3D-printed cages in ACDF and their advantages over traditional cages, as no severe complications or cage subsidence were observed.

A retrospective review of prospectively collected data explored the use of silicate-substituted calcium phosphate (SiCaP)-packed 3D-printed lamellar titanium cages in lumbar surgery for degenerative diseases and deformities.²¹ The findings demonstrated that these cages achieved a high fusion rate with excellent integration and improvements in patient-reported outcomes. Minor complications, unrelated to the cages, were recorded, affirming their safety and effectiveness in lumbar surgery.

The study involved patients undergoing lumbar fusion with cortical bone trajectory (CBT) screws and interbody fusion. Patients were categorized into three groups based on the surgical technique.² The research emphasized that CBT techniques were safe and reliable, especially with precise preoperative computed tomography (CT) scan-based planning. The use of 3D template patient-matched guides yielded superior results, enhancing accuracy, reducing operative time, and lowering complication rates. The clinical outcomes were satisfactory, featuring significant improvements in pain and disability scores. A high fusion rate was observed in patients with longer follow-up periods.

Patients with thoracolumbar metastases who underwent en bloc resection and reconstruction using either 3D-printed autostable artificial vertebrae or titanium cages were examined.¹⁷ The results indicated that the 3D-printed artificial vertebrae led to numerous advantages, including reduced operation time, decreased blood loss, fewer complications, and faster fusion. Patients in the observation group experienced lower rates of nerve-related issues, such as paralysis, weakness, hypoaesthesia, and infection, without any

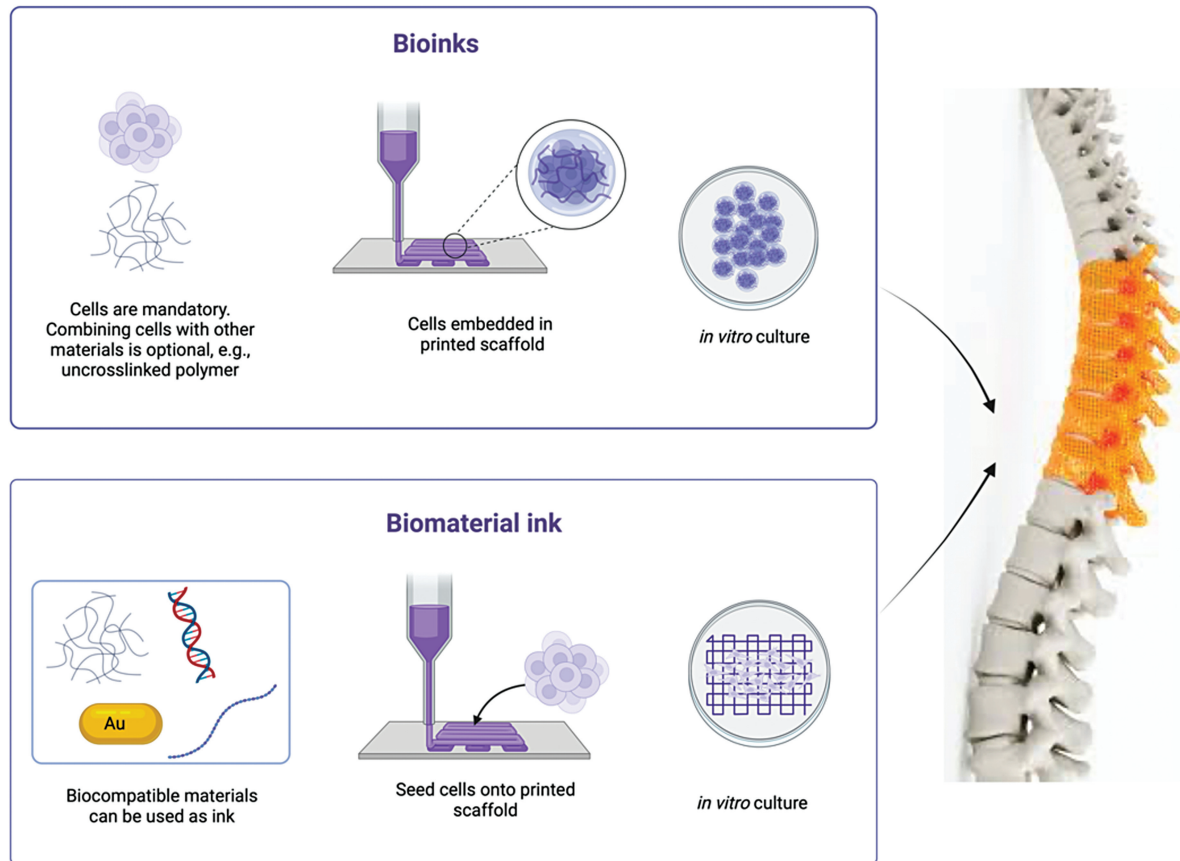


Fig. 2 This figure shows how both bioinks and biomaterial inks can be used as an alternative to synthetic inks in three-dimensional (3D) printing.

significant difference in survival, pain levels, or spinal function recovery.

Promising results are evident with 3D-printed vertebrae printed using both bioinks and biomaterial inks (►Fig. 2).

A retrospective analysis compared the use of two types of cages—3DTi and sPEEK—in anterior and posterior combined surgery with extreme lateral interbody fusion for lumbar degenerative disease or adult spinal deformity.¹⁵ The findings showed that the 3DTi cage demonstrated significantly less vertebral endplate concavity (VEC) and cage subsidence when compared with the sPEEK cage, both immediately and 3 months postsurgery. Moreover, the 3DTi cage exhibited superior correction and maintenance of the local lordotic angle. The study concluded that the 3DTi cage reduced endplate injuries during cage insertion, suggesting its effectiveness in enhancing spinal deformity corrections.

Effectiveness of 3D Printing

The effectiveness of 3DP is providing valuable preoperative information to surgeons, aiding in enhanced surgical planning, and simplifying procedures.¹⁴ The simulated group, which underwent 3D digital simulation before surgery, demonstrated better clinical outcomes compared with the nonsimulated group, with improvements in operation time, blood loss, screw adjustments, fluoroscopy use, and a lower incidence of dural injury or cerebrospinal fluid leakage.

Although there was no significant difference in terms of pain relief, neurological function improvement, and tumor recurrence, the study emphasizes the benefits of 3DP in surgical planning.

The effectiveness, improvement, and safety of a 3D-printed hand orthosis for patients with C-SCI is remarkable.¹² The results indicate a remarkable 558% increase in pinch force after wearing the assistive device, with further improvements during the 2-week follow-up period. Additionally, there was a 37% enhancement in hand dexterity postassistive device use. These findings emphasize the substantial improvement provided by the 3D-printed hand orthosis in terms of hand function, highlighting its effectiveness and safety.

3DP technology was employed to create customized power wheelchair joysticks for patients with severe quadriplegia.¹⁸ The study reveals that all patients experienced improvements in their power wheelchair driving abilities and expressed greater satisfaction with the customized joysticks. The joysticks were noted for their lightweight design, simplicity, and ease of use. These findings underscore the safety and effectiveness of 3DP technology in customizing aids to enhance the mobility and satisfaction of patients with severe disabilities.

The effectiveness of 3D-printed lamellar titanium cages and SiCaP bone grafts in achieving spinal fusion is exceptional.²¹ The 98.9% fusion rate observed at

12 months postsurgery, with 92 out of 93 patients achieving solid fusion, emphasizes the reliability and success of using 3D-printed cages and SiCaP grafts for spinal fusion procedures.

The CBT technique is a dependable alternative to traditional pedicle screws in posterior lumbar fusion.¹⁶ It indicates that the CBT technique offers multiple advantages, including reduced muscle damage, decreased blood loss, shorter operation times, perioperative pain, and hospital stays compared with traditional pedicle screws. This underlines the effectiveness of the CBT technique in achieving positive clinical and radiological outcomes.

Impact and Improvement after 3D Printing

3D-printed hand orthosis improved hand function and activity of daily living (ADL) (related to eating) in clinical tests, such as TRI-HFT, Functional Independence Measure (FIM), and Spinal Cord Independence Measure (SCIM) III.¹³ The myoelectric orthosis, designed to enhance grip through tenodesis, significantly improved hand function, particularly in grasp, lift, and object manipulation. Statistically significant improvements were observed in most items of the TRI-HFT, particularly when dealing with objects of various sizes and shapes. Larger objects, such as a mug, paper, or a dice, showed significant improvement. However, no significant improvements were noted when handling smaller or relatively flat objects like a book, credit card, mobile phone, or pencil. In the second part of the test, which assessed the strength and stability of grip using wooden blocks, participants were able to handle objects efficiently, regardless of weight and friction. Most subjects showed statistically significant improvements in this part. Significant improvements were observed in the total SCIM III and FIM scores, indicating enhanced independence in daily activities. Notably, the most affected ADL category, eating, displayed significant improvement in FIM scores, emphasizing the impact of improved hand function on this task. However, other ADL tasks, such as grooming, bathing, and dressing, did not show significant improvements, suggesting that fine motor function and lower extremity abilities were not significantly affected by the orthosis. Participants provided feedback on the orthosis' usability and effectiveness. Overall, subjects were satisfied with the orthosis' effectiveness, giving it high scores. While some mentioned that the orthosis' dimensions were somewhat bulky due to the linear motor and challenging to adjust, most participants expressed satisfaction with the developed orthosis.

For 3D simulation/3DP-assisted surgery for symptomatic metastatic epidural spinal cord compression of posterior column, the Visual Analog Scale (VAS) scores of the stimulated group improved significantly after the treatment and at the last follow-up compared with before the treatment.¹⁴ VAS score is a measure of pain intensity. The American Spinal Injury Association (ASIA) grading of the stimulated group also improved after the treatment. ASIA grading is a measure of neurological function based on sensory and motor assessments. The stimulated group showed significant or slight

improvement in 20 out of 20 patients, while the nonstimulated group showed improvement in 24 out of 26 patients. This suggests that electrotherapy can enhance the recovery of neurological function in fibromyalgia patients. The simulated group had a shorter operation time (1.94 hours) compared with the nonsimulated group (2.15 hours). Intraoperative blood loss was lower in the simulated group (382.50 mL) compared with the nonsimulated group (478.85 mL). The simulated group had a lower screw adjustment rate (12.33%) compared with the nonsimulated group (21.50%). The simulated group required fewer intraoperative fluoroscopy times (1.30) compared with the nonsimulated group (1.73). Fewer patients in the simulated group experienced dural damage/cerebrospinal fluid leakage (3 patients) compared with the nonsimulated group (11 patients). Both groups experienced significant relief of low back pain symptoms after surgery. There was no significant difference in pain scores before and after surgery between the two groups. Neurological function improved in both groups, and there was no significant difference in the improvement of neurological function between the two groups. During the 2-year follow-up period, 25% of patients in the simulated group and 34.61% in the nonsimulated group experienced a relapse, but there was no statistical difference between the two groups.

After wearing the 3D-printed hand orthosis device, the pinch force significantly increased to 1.71 lb, representing a 558% improvement compared with baseline.¹² During the 2-week follow-up assessment, the average pinch force further increased to 1.86 lb. After wearing the assistive device (posttest), patients took an average of 17.75 blocks, showing a 37% improvement in hand dexterity compared with baseline. The improvement in hand dexterity between the posttest and the 2-week follow-up assessment was statistically significant, indicating that hand dexterity continued to improve after 2 weeks of using the device. Among the self-care items, grooming showed a slight improvement after wearing the assistive device, but the difference was not statistically significant. The average grooming score was 1 point at baseline and 1.25 points in both posttest and 2-week follow-up assessments.

The study used the Power-Mobility Indoor Driving Assessment (PIDA) to evaluate the patients' driving abilities with the customized joysticks.¹⁸ While there were no statistically significant differences, the time required to complete tasks was generally shorter with the customized joysticks. In some cases, there was an improvement in the PIDA scores, indicating better driving performance. The National Aeronautics and Space Administration-Task Load Index assessment indicated reduced workload and improved performance for all patients after using the customized joysticks. Patients reported lower mental and physical demands, reduced effort, and lower frustration levels. Psychosocial Impact of Assistive Devices Scale was used to evaluate the impact of the customized joysticks on patients' subjective well-being. The results showed positive scores in all subscales (competence, adaptability, self-esteem), indicating that using the customized joysticks did not negatively affect patients' well-being. Instead, it led to increased self-

efficacy and decreased negative emotional reactions to disability. The study suggests that the customized joysticks significantly improved the driving abilities and user satisfaction of patients with severe upper extremity disabilities. While not all improvements reached statistical significance, the qualitative improvement in patients' well-being and driving performance was evident.

There was improvement of 3D-printed cage procedure in patients who underwent ACDF.²⁰ According to Odom's criteria for neurological function, there was a significant improvement at 6 months after the operation and at the last follow-up compared with before the operation. The Japanese Orthopaedic Association score, which assesses the severity of myelopathy and neurological function, improved significantly. The study reports that all patients experienced significant improvement in their symptoms of cervical spondylosis. Specific symptoms are not detailed, but patients' overall conditions improved. The study indicates that the cervical curvature index improved significantly from the preoperative value. The curvature of the cervical spine was restored, which is important for maintaining proper spinal alignment and function. Height of the intervertebral space between the cervical vertebrae improved significantly, indicating that the procedure helped restore and preserve intervertebral height. The study concludes that the application of 3D-printed cages in ACDF is safe and stable. The cage fusion rate was 100% at the 6-month and last follow-ups, indicating that the 3D-printed cages effectively promoted vertebral fusion.

Patients who received CBT screws for posterior lumbar fusion reported preoperative symptoms, which included pain (100% of patients), sensory involvement (66.8%), weakness (29.1%), and incontinence/impotence (2.5%).¹⁶ The study measured improvement using the VAS for pain and the Oswestry Disability Index (ODI) to assess disability. The mean preoperative VAS score for pain was 8.2, and the mean preoperative ODI was 59.6. At the 1-month follow-up, the mean VAS score for pain improved to 3.8, and the mean ODI improved to 27.4. At the last follow-up (mean follow-up of 32.3 months), the mean VAS score for pain further improved to 2.7, and the mean ODI improved to 16.7. In patients with a follow-up longer than 24 months (53.4% of patients), fusion was obtained in 92.4% of cases. The study also compared different groups based on patient characteristics, procedural time, and other factors. The groups were divided into group 1, group 2, and group 3. Group 1 had a mean age of 47.5 years, group 2 had a mean age of 58.6 years, and group 3 had a mean age of 57.9 years. The procedural time was 187 minutes for group 1, 142 minutes for group 2, and 124 minutes for group 3. The groups showed differences in procedural time, age, X-ray dose, and hospital stay. Complications were also compared among the groups, with group 1 having a higher complication rate (16.3%) compared with group 2 (3.8%) and group 3 (0.0%). The study suggests that there is a learning curve for surgeons in adopting the CBT technique. As surgeons gained more experience with the technique, procedural times improved, and the accuracy of screw placement increased. The reduction in complications over time may be

attributed to the learning curve as surgeons became more proficient in performing CBT procedures.

The 3DP group had a shorter operation time, with a mean operation time of 8.1 hours.² The control group (titanium cage group) had a longer operation time, with a mean operation time of 9.1 hours. The 3DP group had less intraoperative blood loss, with a mean blood loss of 1614.3 mL. The control group (titanium cage group) had greater intraoperative blood loss, with a mean blood loss of 1850.5 mL. Preoperative VAS scores were similar between the two groups. VAS scores 24 hours postoperative were slightly lower in the 3DP group (4.9) compared with the titanium cage group (5.4). At 3 months postoperative, the 3DP group showed a significant improvement in pain relief with a VAS score of 3.3 compared with the control group. One year postoperative, the 3DP group maintained better pain relief with a VAS score of 2.1 compared with the control group. The 3DP group had a fusion time of 12.5 months, which was slightly longer than the titanium cage group (10.9 months). Implant subsidence was significantly lower in the 3DP group (1.8 mm) compared with the titanium cage group (5.2 mm).

Preoperative local lordotic angles were not significantly different between the 3DTi and sPEEK cage groups.¹⁵ At 3 months postoperatively, the local lordotic angles in the 3DTi group were significantly improved and better maintained compared with the sPEEK group. VEC is a condition where there is an inward, concave deformation of the vertebral endplates. The study reported that VEC was observed in a significantly lower percentage of levels in the 3DTi cage group compared with the sPEEK group. Furthermore, at 3 months postoperatively, no progression of VEC was seen in the 3DTi group, while 21% of levels in the sPEEK group showed VEC progression.

Complications

In patients with symptomatic metastatic epidural spinal cord compression of the posterior column, 3 patients in the simulated group experienced dural damage or cerebrospinal fluid leakage during surgery.¹⁰ In contrast, 11 patients in the nonsimulated group had these complications.

In adult patients with lumbar degenerative disease or deformity who underwent transforaminal lumbar interbody fusion or lateral lumbar interbody fusion surgery with SiCaP-packed 3D-printed lamellar titanium cages reported a low rate of complications, with 9.7% of patients experiencing complications.²¹ These complications included revisions to S1 screws, cage subsidence, fractures, segmental bleeding, chest infection, deep vein thrombosis, superficial wound infection, and increased leg pain. It is important to note that none of these complications were directly related to the inserted cages or SiCaP, indicating that the use of 3D-printed lamellar titanium cages and SiCaP bone grafts did not lead to additional safety risks.

In adult patients with degenerative lumbar spine disorder who underwent lumbar fusion with CBT screws and interbody fusion, the study reports that the total rate of complications was 4.2%, with complications decreasing as the

surgical team gained experience with the CBT technique.¹⁶ The most common complications included misplaced screws requiring delayed repositioning, cage dislocation requiring repositioning, wound infections, and incidental durotomy (tearing of the dura mater). There were no reports of neurologic deficits. The accuracy of screw placement was assessed using the Raley pedicle break classification, and most screws (78.9–93.9%) were classified as grade 0, indicating good placement.

Twenty patients with thoracolumbar metastases underwent en bloc resection and reconstruction with either 3D-printed autostable artificial vertebrae or titanium cages.¹⁷ Fewer complications were noted in the 3DP group compared with the titanium cage group. Specific complications mentioned included nerve paralysis, lower limb weakness, hypoesthesia, cerebrospinal fluid leakage, and infection.

Cage subsidence, a condition where the cage sinks into the vertebral body, was less common with 3DTi cages.¹⁵ The sPEEK cages exhibited more cage subsidence at 3 months postoperatively. The study reported a lower occurrence of complications with 3DTi cages. Complications were primarily observed in the sPEEK cage group.

Limitations

The application of 3DP in medical contexts presents certain limitations. The cost of 3DP, which is often not covered by national health insurance, can restrict access to patients who face financial constraints.¹⁴ Additionally, due to the limited availability of 3DP technology in some hospitals, third-party involvement may be required, potentially complicating communication between health care providers and patients, and leading to issues of patient mistrust.

It is a relatively expensive approach, with an average cost of approximately \$2,500.²⁰ The administration of the test is time-consuming, taking more than an hour, and demands extensive training for correct execution. There is also a concern that if the assessment is not employed consistently over time, the reliability of the test may be compromised.

The study's relatively small sample may constrain the generalizability of findings.¹⁸ Furthermore, the use of different assessment designs for various tests could impact comparability between assessments, limiting the depth of insights.

The retrospective nature of the study places constraints on the significance level of the results.¹⁶ The study's ability to provide comprehensive data on patient-matched 3D-printed guides for the comparison of homogeneous subgroups with substantial sample size is hindered.

Segi et al offer several study limitations to consider.¹⁵ It was not conducted as a RCT, and the surgical procedure and fusion range were based on surgeon preferences. The relatively short follow-up period, although attributed to the novelty of 3DTi cages, limits the study's ability to capture long-term changes. The study population's heterogeneity, the absence of patient-reported outcomes, and potential measurement errors in assessing alignment, VEC, and cage subsidence in radiographs and CT images should also be acknowledged.

Clinical Implications

The clinical implications of these studies demonstrate the remarkable potential of 3DP technology in enhancing patient outcomes across a range of medical conditions. From improving hand function for C-SCI patients to streamlining surgical procedures for metastatic spinal cord compression, 3DP offers a promising avenue for health care advancement. Furthermore, the reliability of 3D-printed assessments in evaluating motor function and the creation of customized aids for mobility significantly contribute to patient well-being. These findings underscore the importance of incorporating 3DP into clinical practice, offering cost-effective, customized solutions that can enhance patient independence, reduce complications, and ultimately improve their overall quality of life.

Conclusion

The current literature reflects favorable outcomes from the application of 3DP technologies in the treatment of SCIs, with minimal adverse effects. This heralds a new era in both surgical and nonsurgical interventions for SCIs, offering improved precision and a diverse array of treatment options for more comprehensive patient care.

Ethical Approval

This systematic review adheres to ethical guidelines and standards for conducting research. Data used are from published studies and do not involve human subjects directly.

Conflict of Interest

None declared.

Acknowledgments

We would like to thank our mentor, Dr. Martin Weinand, for supporting our endeavors and for his role in shaping us into becoming future academic neurosurgeons. Without him, the Global Neurosurgical Alliance would never have been created, and the assembly of our 160-plus researchers would not have been possible. Thank you for helping us change the world by creating high-quality research that benefits patients worldwide.

References

- Venugopal C, Chandanala S, Prasad HC, Nayeem D, Bhonde RR, Dhanushkodi A. Regenerative therapy for hippocampal degenerative diseases: lessons from preclinical studies. *J Tissue Eng Regen Med* 2017;11(02):321–333
- Sobrido-Cameán D, Barreiro-Iglesias A. Role of caspase-8 and Fas in cell death after spinal cord injury. *Front Mol Neurosci* 2018; 11:101
- Orr MB, Gensel JC. Interactions of primary insult biomechanics and secondary cascades in spinal cord injury: implications for therapy. *Neural Regen Res* 2017;12(10):1618–1619
- Sabelström H, Stenudd M, Frisén J. Neural stem cells in the adult spinal cord. *Exp Neurol* 2014;260:44–49

- 5 Breslin K, Agrawal D. The use of methylprednisolone in acute spinal cord injury: a review of the evidence, controversies, and recommendations. *Pediatr Emerg Care* 2012;28(11):1238–1245, quiz 1246–1248
- 6 Hurlbert RJ. Methylprednisolone for the treatment of acute spinal cord injury: point. *Neurosurgery* 2014;61(Suppl 1):32–35
- 7 Silva NA, Sousa N, Reis RL, Salgado AJ. From basics to clinical: a comprehensive review on spinal cord injury. *Prog Neurobiol* 2014;114:25–57
- 8 Yuan TY, Zhang J, Yu T, Wu JP, Liu QY. 3D bioprinting for spinal cord injury repair. *Front Bioeng Biotechnol* 2022;10:847344
- 9 Garg B, Mehta N. Current status of 3D printing in spine surgery. *J Clin Orthop Trauma* 2018;9(03):218–225. Doi: 10.1016/j.jcot.2018.08.006
- 10 Tong Y, Kaplan DJ, Spivak JM, Bendo JA. Three-dimensional printing in spine surgery: a review of current applications. *Spine J* 2020;20(06):833–846
- 11 Kabra A, Mehta N, Garg B. 3D printing in spine care: a review of current applications. *J Clin Orthop Trauma* 2022;35:102044
- 12 Yeh PC, Chen CH, Chen CS. Using a 3D-printed hand orthosis to improve three-jaw Chuck hand function in individuals with cervical spinal cord injury: a feasibility study. *IEEE Trans Neural Syst Rehabil Eng* 2023;31:2552–2559
- 13 Yoo HJ, Lee S, Kim J, Park C, Lee B. Development of 3D-printed myoelectric hand orthosis for patients with spinal cord injury. *J Neuroeng Rehabil* 2019;16(01):162
- 14 Sun Z, Jia R, Wang X, Pang X. Three-dimensional simulation/printing-assisted surgery for symptomatic metastatic epidural spinal cord compression of posterior column: efficacy assessment based on 2-year follow-up. *Front Surg* 2023;10:1177280
- 15 Segi N, Nakashima H, Shinjo R, et al. Vertebral endplate concavity in lateral lumbar interbody fusion: tapered 3D-printed porous titanium cage versus squared PEEK cage. *Medicina (Kaunas)* 2023;59(02):372
- 16 Petrone S, Marengo N, Ajello M, et al. Cortical bone trajectory technique's outcomes and procedures for posterior lumbar fusion: a retrospective study. *J Clin Neurosci* 2020;76:25–30
- 17 Cao Y, Yang N, Wang S, et al. The application of 3D-printed auto-stable artificial vertebral body in en bloc resection and reconstruction of thoracolumbar metastases. *J Orthop Surg Res* 2023;18(01):638
- 18 Shin HD, Ahn DH, Lee HA, et al. Customized power wheelchair joysticks made by three-dimensional printing technology: a pilot study on the environmental adaptation effects for severe quadriplegia. *Int J Environ Res Public Health* 2021;18(14):7464
- 19 Jin YZ, Zhao B, Lu XD, et al. Mid- and long-term follow-up efficacy analysis of 3D-printed interbody fusion cages for anterior cervical discectomy and fusion. *Orthop Surg* 2021;13(07):1969–1978
- 20 Kapadia N, Jovanovic L, Musselman K, Wang R, Marquez-Chin C, Popovic MR. Preliminary evaluation of the reliability and validity of the 3D printed Toronto Rehabilitation Institute-Hand Function Test in individuals with spinal cord injury. *J Spinal Cord Med* 2021;44(sup1):S225–S233
- 21 Mokawem M, Katzouraki G, Harman CL, Lee R. Lumbar interbody fusion rates with 3D-printed lamellar titanium cages using a silicate-substituted calcium phosphate bone graft. *J Clin Neurosci* 2019;68:134–139