

Variation in the Distribution of the Middle Trunk: Potential Contraindication for C7 Harvest?

Rajendra Nehete¹ Anil Bhatia²

¹ Department of Plastic Surgery, Vedant Hospital, Nashik, Maharashtra, India

² Department of Brachial Plexus Surgery, Deenanath Mangeshkar Hospital, Pune, Maharashtra, India

Indian J Plast Surg

Experience with direct repairs of the opposite C7 with the lower trunk has made restoration of useful finger flexion a realistic objective in the management of total posttraumatic brachial plexus injuries, particularly in younger individuals. This entails a detailed exploration of the injured brachial plexus with certain essential maneuvers for proximal mobilization of the medial cord.¹ It is based on the premise that the lower trunk is discrete and communicates with the posterior cord via its posterior division alone. However, we have noted a distinct contribution from the middle trunk to the lower trunk on three consecutive occasions (►**Fig. 1**). Further distal dissection revealed its continuity with the medial root of the median nerve. A similar anatomical

Address for correspondence Rajendra Nehete, Department of Plastic Surgery, Vedant Hospital, Nashik 422002, Maharashtra, India (e-mail: rajendranehete@gmail.com).

distribution was anticipated on the uninjured side. The fear of potential deficit in the motor territory of the median nerve following harvest of the opposite C7 deterred us from using the technique in these three patients. The anomalies of the middle trunk have been reported by Woźniak et al in the cadaveric study in fetuses.² We communicated our observations to the original author of this technique (Dr. Shufeng Wang)^{3,4} who confirmed having had similar cases. However, in his experience, this branch of the C7 continued to the lateral root of the median nerve and sectioning it did not produce significant deficit.

Our experience has been different, and we would like to stress the need for a detailed surgical exploration of the injured plexus in each case and that the strategy for reconstruction should be decided only on the basis of the findings.

Conflict of Interest

None declared.

References

- 1 Bhatia A, Doshi P, Koul A, Shah V, Brown JM, Salama M. Contralateral C-7 transfer: is direct repair really superior to grafting? *Neurosurg Focus* 2017;43(01):E3
- 2 Woźniak J, Kędzia A, Dudek K. Variability of the trunks and divisions of the brachial plexus in human fetuses. *Adv Clin Exp Med* 2013;22(03):309–318
- 3 Wang SF, Li PC, Xue YH, Yiu HW, Li YC, Wang HH. Contralateral C7 nerve transfer with direct coaptation to restore lower trunk function after traumatic brachial plexus avulsion. *J Bone Joint Surg Am* 2013;95(09):821–827, S1–S2
- 4 Wang SF, Xue YH. Contralateral C7 nerve transfer with direct coaptation to restore lower trunk function after traumatic brachial plexus avulsion injuries. *JBSJ Essent Surg Tech* 2014;4(01):e5

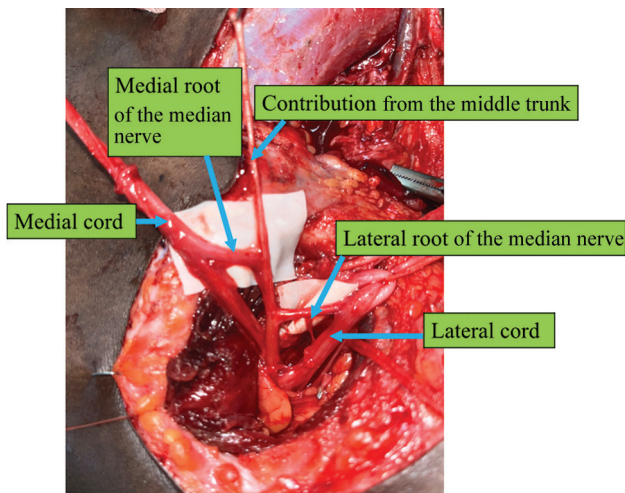


Fig. 1 Contribution from the middle trunk to the medial root of the median nerve.

DOI <https://doi.org/10.1055/s-0044-1788897>.
ISSN 0970-0358.

© 2024. Association of Plastic Surgeons of India. All rights reserved. This is an open access article published by Thieme under the terms of the Creative Commons Attribution-NonDerivative-NonCommercial-License, permitting copying and reproduction so long as the original work is given appropriate credit. Contents may not be used for commercial purposes, or adapted, remixed, transformed or built upon. (<https://creativecommons.org/licenses/by-nc-nd/4.0/>)

Thieme Medical and Scientific Publishers Pvt. Ltd., A-12, 2nd Floor, Sector 2, Noida-201301 UP, India