



Complex movement disorders in early onset hypoparathyroidism

Distúrbios do movimento complexos em hipoparatireoidismo de início precoce

Filipe Sarmiento^{1,2} João Vitor Gerdulli Tamanini² Sofia Mônaco Gama²
Leonardo Furtado Freitas^{1,3} Orlando Graziani Povoas Barsottini² José Luiz Pedroso²

¹University of Florida, Norman Fixel Institute for Neurological Diseases, Gainesville FL, United States.

²Universidade Federal de São Paulo, Departamento de Neurologia e Neurocirurgia, São Paulo SP, Brazil.

³University of Iowa, Department of Radiology, Division on Neuroradiology, Iowa City IA, United States.

Address for correspondence Filipe Sarmiento
(email: filipe.sarmiento@neurology.ufl.edu).

Arq. Neuro-Psiquiatr. 2024;82(12):s00441788778.

A 23-year-old female patient with long-standing untreated idiopathic hypoparathyroidism presented with complex involuntary movements. Physical examination revealed generalized dystonia, painful spasms, and stereotypies (►**Video 1**). Brain magnetic resonance imaging (►**Figure 1**) and brain CT (►**Figure 2**) revealed extensive bilateral calcification.

Video 1.

Complex movement disorders in early onset hypoparathyroidism. Online content including video sequences viewable at: <https://www.thieme-connect.com/products/ejournals/html/10.1055/s-0044-1788778>.

Hypoparathyroidism can present with a variety of neurological symptoms (►**Figure 3**), including, though less commonly, movement disorders such as chorea, parkinsonism, dystonia, choreoathetosis, and paroxysmal dyskinesia.^{1,2} Notably, stereotypic-like movements were only previously described by Galvez-Jimenez et al.¹ Central nervous system calcifications are present in up to 74% of patients with hypoparathyroidism.³ Despite its prevalence, there is no clear relationship between the location and extent of the calcifications and the clinical phenotype.³

received
May 24, 2024
accepted
June 29, 2024

DOI <https://doi.org/10.1055/s-0044-1788778>.
ISSN 0004-282X.

© 2024. The Author(s).

This is an open access article published by Thieme under the terms of the Creative Commons Attribution 4.0 International License, permitting copying and reproduction so long as the original work is given appropriate credit (<https://creativecommons.org/licenses/by/4.0/>).

Thieme Revinter Publicações Ltda., Rua do Matoso 170, Rio de Janeiro, RJ, CEP 20270-135, Brazil

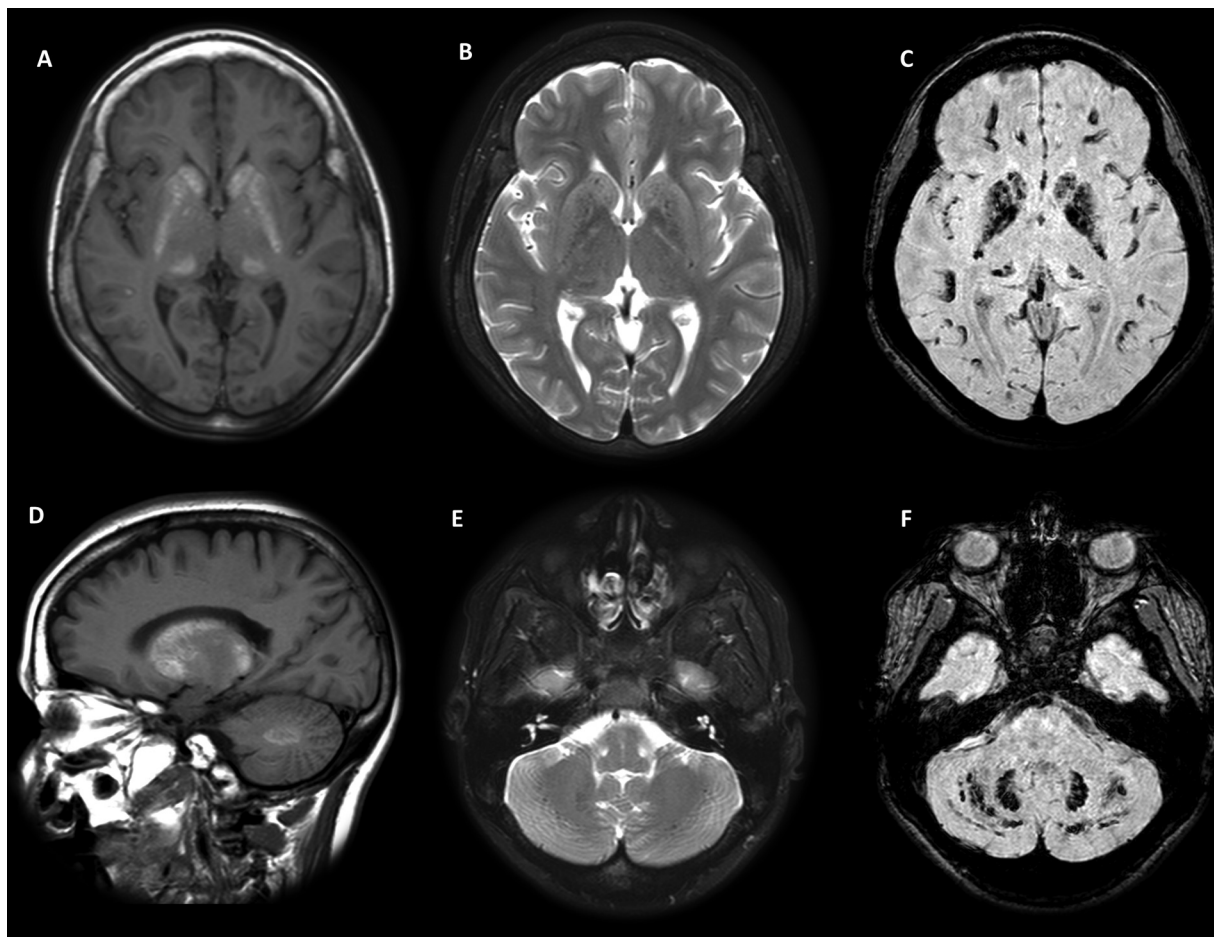


Figure 1 Brain MRI: A/D - T1 hyperintense signal in the basal ganglia and dentate nuclei; B/E - T2 low to isointense signal in the basal ganglia and dentate nuclei; C/F - SWI hyposignal in the basal ganglia, dentate nuclei and subcortical white matter.

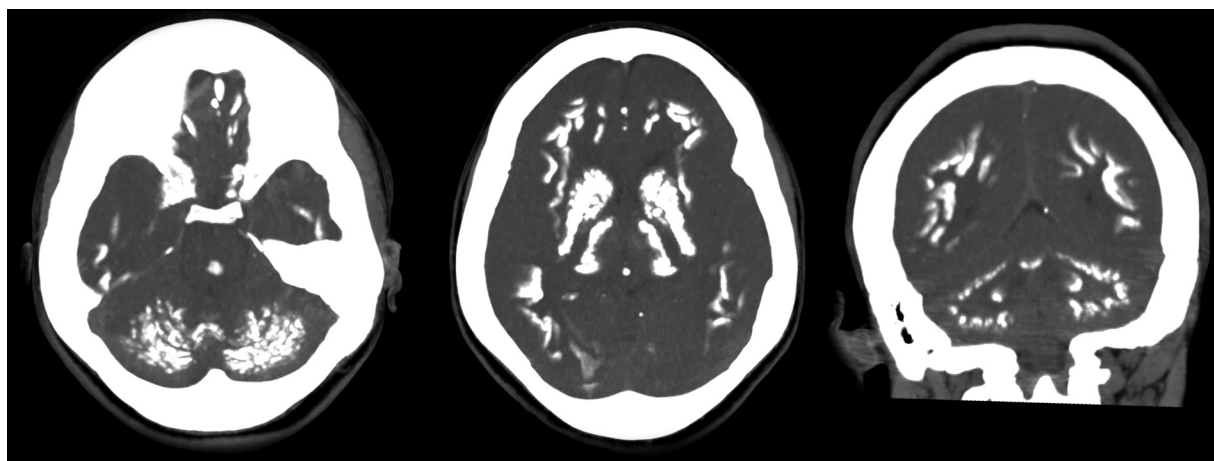


Figure 2 Brain CT scan disclosing bilateral and symmetrical calcification in the basal ganglia, thalamus, dentate nuclei, and subcortical white matter.

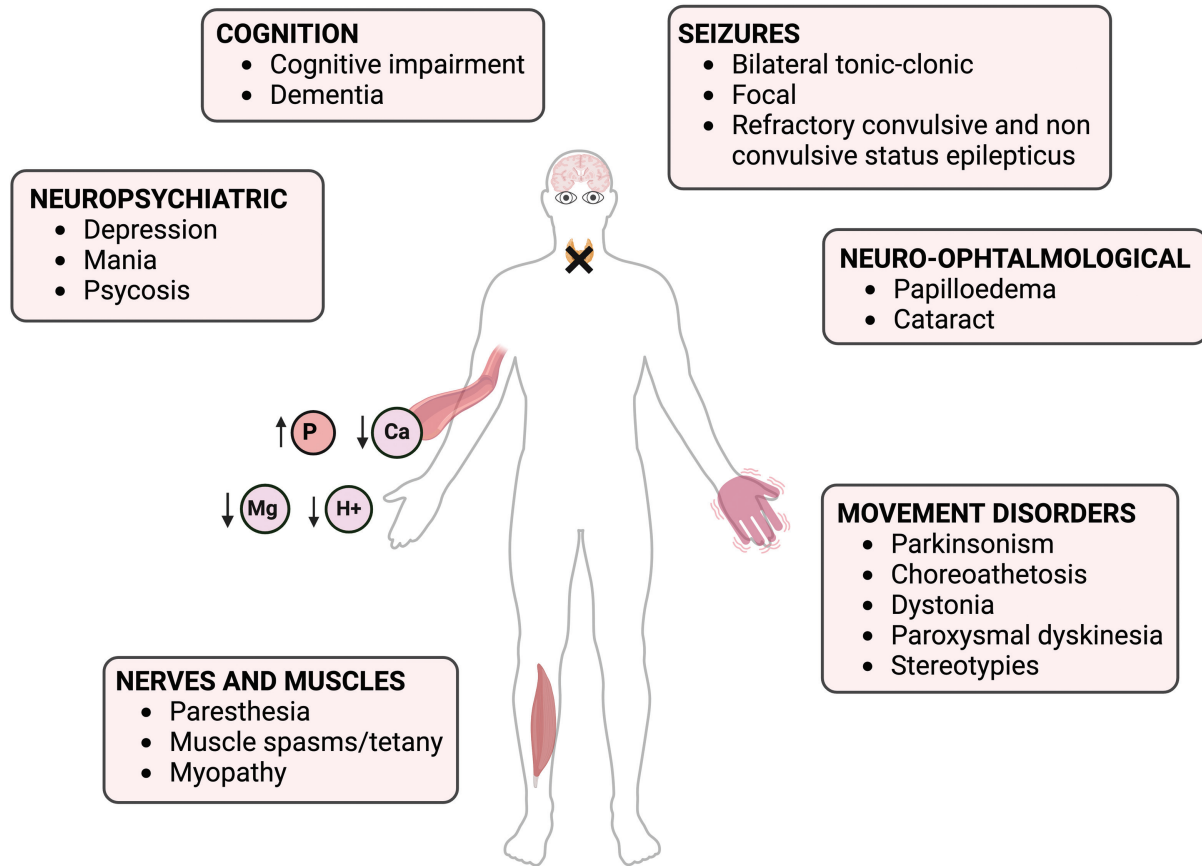


Figure 3 The figure demonstrates the broad spectrum of neurological manifestations associated with hypoparathyroidism. Additionally, it depicts ion changes in the blood.

Authors' Contributions

FPS: conceptualization, data curation, project administration, supervision, writing – original draft, writing – review & editing; JVGT, SMG: writing – original draft, writing – review & editing; LFF: data curation, writing – review & editing; OGPB: supervision; JLP: conceptualization, data curation, project administration, supervision, writing – review & editing.

Conflict of Interest

The authors have no conflict of interest to declare.

References

- 1 Gálvez-Jiménez N, Hanson MR, Cabral J. Dopa-resistant parkinsonism, oculomotor disturbances, chorea, mirror movements, dyspraxia, and dementia: the expanding clinical spectrum of hypoparathyroidism. A case report. *Mov Disord* 2000;15(06):1273–1276. Doi: 10.1002/1531-8257(200011)15:6<1273::aid-mds1038>3.0.co;2-o
- 2 Manyam BV, Walters AS, Narla KR. Bilateral striopallidodentate calcinosis: clinical characteristics of patients seen in a registry. *Mov Disord* 2001;16(02):258–264. Doi: 10.1002/mds.1049
- 3 Mannstadt M, Bilezikian JP, Thakker RV, et al. Hypoparathyroidism. *Nat Rev Dis Primers* 2017;3:17080. Doi: 10.1038/nrdp.2017.55