




Randomized, Blinded, Controlled Clinical Trial of Polylactide–Collagen Scaffold in Treatment of Shoulder Osteochondritis Dissecans in Dogs

Helka Heikkilä^{1,2} Vilma Reunanen¹ Heli K. Hyytiäinen¹ Jouni J.T. Junnila³ 
Outi Laitinen-Vapaavuori¹ Pauli Keränen¹

¹ Department of Equine and Small Animal Medicine, Faculty of Veterinary Medicine, University of Helsinki, Helsinki, Finland

² Lahti Veterinary Hospital, IVC Evidensia, Lahti, Finland

³ EstiMates OY, Turku, Finland

Address for correspondence Pauli Keränen, DVM, PhD, Department of Equine and Small Animal Medicine, Faculty of Veterinary Medicine, University of Helsinki, P.O. Box 57, FI-00014 Helsinki, Finland (e-mail: pauli.keranen@helsinki.fi).

Vet Comp Orthop Traumatol

Abstract

Objective The aim of our study was to investigate a degradable polylactide–collagen scaffold (COPLA) in the treatment of shoulder osteochondritis dissecans (OCD) in dogs. **Study Design** The study was a controlled, randomized, blinded clinical trial with a parallel group design with a 1.5-year follow-up. Twenty dogs with uni- or bilateral shoulder OCD (29 shoulders) were randomized to receive a COPLA or arthroscopic debridement only (Control). The outcome of treatment was assessed with gait and stance analysis, passive range of motion measurement, pain and lameness evaluation, Helsinki Chronic Pain Index, and computed tomography (CT).

Results Eighteen dogs (25 shoulders) completed the study. The clinical outcome variables improved significantly from baseline in COPLA and Control groups after treatment but no significant differences emerged between groups. Significantly fewer COPLA than Control shoulders had osteoarthritis (OA) in CT at 6 months ($p = 0.019$) but the difference was not significant at 1.5 years. At 1.5 years, all dogs were sound and pain-free in joint palpation, but OA was diagnosed in 13/18 dogs (18/25 shoulders) with CT.

Conclusion The results suggest that COPLA scaffold slowed down the development of OA at 6 months but it did not improve the clinical recovery or prevent OA in dogs with shoulder OCD in long-term follow-up at 1.5 years compared with arthroscopic debridement only. Regardless of the treatment method, clinical recovery was good, but OA developed in the majority of dogs.

Keywords

- ▶ arthroscopy
- ▶ canine
- ▶ polylactide–collagen scaffold
- ▶ osteochondritis dissecans
- ▶ restorative technique

Introduction

The aim of treatment in canine osteochondritis dissecans (OCD) is to relieve pain, regain function, and prevent secondary osteoarthritis (OA). The current standard of care is the removal of the cartilaginous flap and debridement of the

cartilage defect at an early age via arthroscopy or arthroplasty.^{1,2} To enhance tissue healing, preparative techniques, like abrasion arthroplasty, curettage, microfracture, and forage, have been used to treat OCD lesions to create vascular access from underlying bone to bring stem cells and growth factors to the site.³ In addition, restorative techniques, such as

received

February 9, 2024

accepted after revision

July 8, 2024

DOI <https://doi.org/>

10.1055/s-0044-1788726.

ISSN 0932-0814.

© 2024. The Author(s).

This is an open access article published by Thieme under the terms of the Creative Commons Attribution-NonDerivative-NonCommercial-License, permitting copying and reproduction so long as the original work is given appropriate credit. Contents may not be used for commercial purposes, or adapted, remixed, transformed or built upon. (<https://creativecommons.org/licenses/by-nc-nd/4.0/>)

Georg Thieme Verlag KG, Rüdigerstraße 14, 70469 Stuttgart, Germany

osteocondral autografts and allografts, and polyurethane implants, have been reported in the treatment of canine OCD.^{4–7} However, to our knowledge, no prospective controlled clinical trials are investigating the benefits of any treatment of OCD in dogs. The existing literature consists of retrospective studies and case series describing OCD lesion debridement in arthroscopy or arthrotomy and different restorative surgical techniques and their outcome.^{8–13} Due to a lack of comparison to a control group, the true benefits of the previously reported restorative techniques are unknown.

A novel, biodegradable polylactide–collagen scaffold (COPLA Scaffold, Askel Healthcare, Helsinki, Finland) has been developed for the repair of chondral and osteochondral defects in animals. It comprises a three-dimensional structure of synthetic polylactide incorporated with collagen. The polylactide frame provides mechanical support, while the incorporated collagen improves water absorption and mimics native cartilage extracellular matrix components, enhancing chondrocyte activity *in vitro*.¹⁴

Similar types of scaffolds have been studied in experimental porcine cartilage defects. Muhonen and colleagues reported hyaline cartilage formation in porcine cartilage defects covered with a poly-(L/D)-lactide mesh incorporated with recombinant human collagen type II and containing autologous chondrocytes.¹⁵ Salonius and colleagues evaluated a scaffold consisting of a poly-(L/D)-lactide mesh incorporated with recombinant human collagen type III without the application of chondrocytes.¹⁶ Although hyaline cartilage was formed in some of the cartilage defects covered with the scaffold, overall, the use of the scaffold did not differ from spontaneous healing.

This study aimed to investigate the COPLA scaffold in the treatment of shoulder OCD in dogs in a randomized, blinded, controlled clinical trial. Our hypothesis was that dogs treated with the COPLA scaffold would recover faster and develop less OA than dogs treated with arthroscopic debridement only.

Materials and Methods

The study was approved by the Project Authorization Board of the Regional State Administrative Agency for Southern Finland (ESAVI-5478-04.10.07-2017 on June 8, 2017, and ESAVI/7533/2020 on April 17, 2020). Dog owners provided written informed consent. They were free to discontinue the trial at any time.

Animals

Client-owned dogs with uni- or bilateral shoulder OCD requiring surgical treatment were eligible to participate. The inclusion and exclusion criteria are presented in ►Appendix Table 1 (available in the online version). To screen for study eligibility, physical and orthopaedic examinations, serum biochemistry, haematology, and urinalysis were performed. In addition, testing for methicillin-resistant *Staphylococcus aureus* and *Staphylococcus pseudointermedius* was conducted.¹⁷ In addition, radiographs were taken of the shoulder, elbow, stifle, and hip joints, and computed tomography (CT) of the shoulder and elbow joints was performed.

Study Design

The study was performed as a prospective, controlled, randomized, blinded clinical trial with a stratified parallel group design. The dogs were randomized in a 1:1 ratio to receive arthroscopic debridement and a COPLA scaffold or arthroscopic debridement only (Control). In dogs with bilateral OCD, both shoulders were allocated to the same group. For randomization, the dogs were stratified into four strata based on the size of the lesion (diameter 6–10 or >10 mm) evaluated with CT and the status of either uni- or bilateral OCD. Block randomization was used. The block size was two within each stratum. Randomization was performed by an assistant using a randomization list from randomizer.org. The dog owners and investigators were blinded to treatment allocation.

The response to treatment was evaluated at 2 weeks and 2, 6, 12, and 18 months with gait and stance analysis, shoulder passive range of motion measurement (PROM), pain and lameness evaluation, Helsinki Chronic Pain Index (HCPI), and CT. The detailed schedule for evaluations is provided in ►Fig. 1.

Surgery

Dogs received acepromazine (0.02 mg/kg, IM) and methadone (0.2 mg/kg, IM) as premedication. Anaesthesia was induced with propofol (2–4 mg/kg, IV) and ketamine (1 mg/kg, IV) and maintained using sevoflurane in oxygen and fentanyl (3–10 µg/kg/h, constant rate infusion (CRI), rate depending on nociception). Antibiotic medication prophylaxis was provided with cefazolin (22 mg/kg, IV, repeated every 90 minutes).

The shoulders were entered via a standard arthroscopic approach with a 2.7-mm arthroscope and the cartilage was palpated with a hook probe.^{18–20} The cartilage flap was removed, and the lesion was treated with an abrasion technique using a shaver to the bleeding bone.²⁰

In the COPLA group, the instrumental portal was bluntly extended to a 3.5 cm long incision between the deltoid muscle heads after arthroscopy. The joint capsule was opened and kept open with retractors. The dimensions of the OCD lesion were obtained by using a Castroviejo Caliper Orthopedic Measuring Gauge. A plastic template was cut to fit the shape of the lesion, and the COPLA scaffold was cut accordingly. The joint was flushed, the prepared lesion bed was suctioned dry, and the cut scaffold was meticulously implanted into the lesion. Fibrin sealant (Tisseel, Baxter, Deerfield, IL; or Evicel, Ethicon, Raritan, NJ) was instilled on the scaffold at the edges of the cartilage lesion and was left to set for 5 minutes before continuing the joint irrigation. The wound was closed routinely. In the Control group, after arthroscopy, the skin incision of the instrumental portal was extended into a similar 3.5-cm length as in the COPLA group. Postoperative analgesia was provided by morphine (0.1 mg/kg, intra-arterial), meloxicam (0.2 mg/kg, IV), and methadone (0.2 mg/kg, IV). Buprenorphine (0.02 mg/kg, IV) was given at discharge. Cold compresses were used for 48 hours.

At home, meloxicam (0.1 mg/kg, PO) was continued once daily for 14 days. Additionally, tramadol (2–4 mg/kg, PO) was given three times daily for 3 days. Glucosamine sulphate

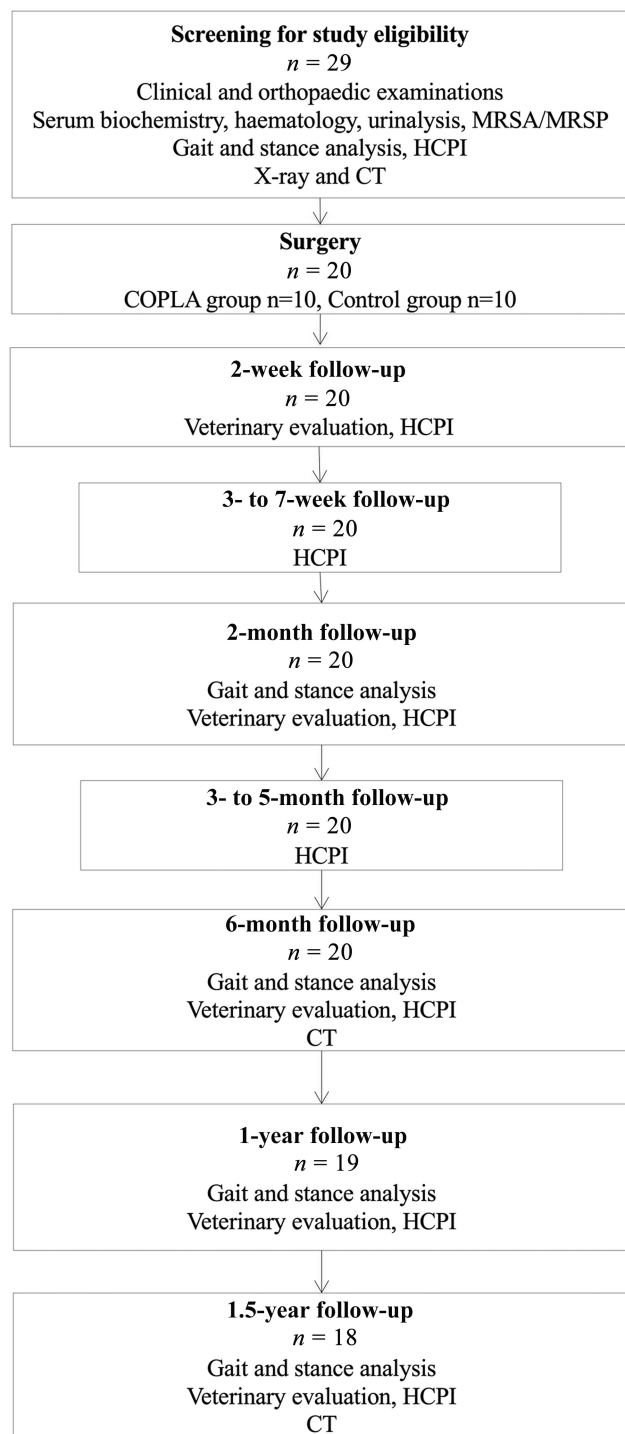


Fig. 1 Detailed schedule for the recruitment of dogs and evaluation of response to treatment after surgical treatment with arthroscopic debridement and a polylactide–collagen scaffold (COPLA) or arthroscopic debridement only (Control). Gait and stance analyses were performed with force platforms. Veterinary evaluation comprised passive range of motion measurement and subjective scoring of lameness and pain. CT, computed tomography; HCPI, Helsinki Chronic Pain Index; MRSA/MRSP, screening for methicillin-resistant *Staphylococcus aureus* and *Staphylococcus pseudointermedius*.

(750 mg, PO) was prescribed once daily for 3 months. Omega-3 fatty acid supplement was started. Passive range of motion exercises were started 4 days and active physiotherapy 2 weeks postoperatively.

Outcome Variables

Gait Analysis

The dogs were trotted over a piezoelectric force platform (Kistler force plate, type 9286, Kistler Instrumente AG, Winterthur, Switzerland) with a loose lead. The velocity of the dogs was measured by three photoelectric cells positioned 1 m apart from each other and a related start–interrupt timer system (Sharon Software Inc.). The data were recorded on a system-related software program (Acquire 7.3, Sharon Software Inc.). The mean of three to five steps of both left and right limbs were selected for statistical purposes for each dog at each visit. For a step to be included in the analysis, there had to be full paw contact of only the ipsilateral fore and hindlimbs on the plate. The acceptable variance in acceleration for each step was $\pm 0.5 \text{ m/s}^2$ and the acceptable range in velocity was $\pm 0.5 \text{ m/s}$ of the mean velocity of each dog. All forces were normalized to body weight in kilograms. Peak vertical force (PVF) and vertical impulse were used for the analysis.

Stance Analysis

Static weight distribution was measured with a force platform (Stance Analyzer, PetSafe, Knoxville, TN) according to a previously published protocol.²¹ Three series of at least five individual recordings were done at each visit.

Owner Evaluation

Owners assessed their dog's response to treatment with HCPI.²²

Veterinary Evaluation

The pain-free shoulder PROM was measured with a universal plastic goniometer as described previously.²³ Degrees of lameness and pain on palpation of the joint were subjectively scored using a five-point scale.²⁴

Imaging

The dogs were sedated with dexmedetomidine (5 $\mu\text{g}/\text{kg}$, IM), butorphanol (0.3 mg/kg, IM), and ketamine (1 mg/kg, IM) for imaging. Intravenous propofol was used, if necessary. Helical shoulder CT imaging (GE LightSpeed VCT 64, GE Healthcare, Fairfield, CT) was performed in dorsal recumbency with shoulders at a 140-degree angle using a bone algorithm and a slice thickness of 0.625 mm.²⁵

Assessment of Images

The images were analysed with an OsiriX DICOM Viewer (Pixmeo OsiriX, version 11.0.4, Bernex, Switzerland). The greatest length, width, and depth of the lesion and the presence and severity of OA were established. Osteoarthritis was scored subjectively (0 = normal, 1 = mild changes, 2 = moderate changes, and 3 = severe changes) based on osteophytosis (size, shape, number of locations; the margins of the humeral head, bicipital groove, glenoid margins; persistent subchondral sclerosis, remodelling, and new intra-articular fragments). The subjective scoring system was modified from previously published information regarding OA changes in the canine shoulder and elbow joints.^{26–30}

Adverse Events

Adverse events were assessed with physical and orthopaedic examinations, CT imaging, and by owner interviews. Incidents that required shoulder reoperation, were life-threatening, or resulted in death during the study were considered major adverse events. Incidents managed without further consequences were considered minor adverse events. Adhering to the intention-to-treat principle, all data were included in the statistical analysis despite adverse events.³¹

Statistical Analysis

All continuous data were summarized with descriptive statistics by treatment and time point. Categorical data were summarized with frequency tables with percentages by treatment and time point. For selected variables, the treatment groups were further divided into bilateral and unilateral groups.

The differences between treatments in the change from baseline of the ground reaction forces, pain-related continuous variables, and OCD lesion size were analysed with linear mixed models, where treatment group, visit, and their interaction were used as fixed effects and the dog as a random term. The differences between the treatments and the within-group changes from baseline at each time point were estimated from the models using contrasts including 95% confidence intervals. The ground reaction forces were analysed separately for bilaterally and unilaterally operated dogs.

The differences between the treatments in CT categorical variables OA and dichotomized OA grade (no/mild vs. moderate/severe) were tested by visit utilizing Fisher's exact tests. The differences between treatments in change from baseline in pain-related categorical variables were analysed with subject-specific cumulative logit models where treatment group, visit, and their interaction were used as fixed effects and the dog as the random term. Odds ratios were estimated from the models.

All statistical calculations were performed using the SAS software, version 9.4 (SAS Institute Inc.).

Results

Animals

Of the 29 recruited dogs, 20 dogs proved eligible. Thirty-five shoulders of the 20 dogs had surgery but 6 shoulders were excluded after arthroscopy because no OCD lesion was detected ($n=4$) or it was <6 mm ($n=2$). Therefore, 29 shoulders were allocated in the study. Fourteen shoulders (10 dogs) were assigned to COPLA and 15 shoulders (10 dogs) to the Control group. Detailed treatment allocation is presented in ►Appendix Table 2 (available in the online version).

No significant differences were present in signalment between the groups (►Appendix Table 3, available in the online version). Eighteen dogs (25 shoulders) completed the study. Two Control dogs (four shoulders) did not complete the study: one dog was euthanized due to an adverse event after 6 months and another dog was lost from follow-up after 1 year.

Surgery

Mean \pm standard deviation for surgical time was 102 ± 25 minutes for the COPLA group and 81 ± 20 minutes for the Control group ($p=0.012$).

Outcome Variables

Gait Analysis

The peak vertical force and vertical impulse improved significantly from baseline in both groups during the study (►Fig. 2). No significant between-group differences were detected (►Appendix Table 4, available in the online version).

Stance Analysis

Static weight-bearing on the operated limb increased from baseline in both groups during the study (►Table 1). However, the increase from baseline was significant only in the unilaterally operated COPLA limbs at 1.5 years ($p=0.015$). No significant between-group differences were detected (►Appendix Table 4, available in the online version).

The proportion of body weight-bearing on both forelimbs increased slightly from baseline in both groups during the study (►Table 2) but this increase was not significant. No significant between-group differences were detected (►Appendix Table 4, available in the online version).

Owner Evaluation

At 1 week postoperatively, the HCPI was significantly higher than at baseline in the COPLA ($p=0.001$) but not in the Control group ($p=0.182$; ►Fig. 3). The HCPI decreased significantly from baseline in both groups starting at 5 weeks postoperatively. No significant between-group differences were detected (►Appendix Table 4, available in the online version).

Veterinary Evaluation

The pain and lameness scores decreased significantly from baseline in both groups during the study (►Fig. 4). No significant between-group differences were detected (►Appendix Table 4, available in the online version).

Pain-free shoulder PROM increased from baseline in both groups during the study. In the Control group, the increase was significant starting from week 8 ($p < 0.05$), while in the COPLA group, the increase was significant only at 6 months ($p=0.012$), after which the PROM started to decrease (►Fig. 5). No significant between-group differences were detected (►Appendix Table 4, available in the online version).

Imaging

The length, width, and depth of the OCD lesion did not differ between the groups at baseline. The length and width of the OCD lesion decreased significantly from baseline in both groups (►Table 3). At 6 months, the OCD lesion was deeper than at baseline in the COPLA but not in the Control group ($p=0.026$). At 1.5 years, the lesion was significantly shallower than at baseline in both groups ($p=0.031$ for COPLA and $p=0.010$ for Control).

No dog had OA at baseline. At 6 months, there were significantly less COPLA than Control shoulders with OA

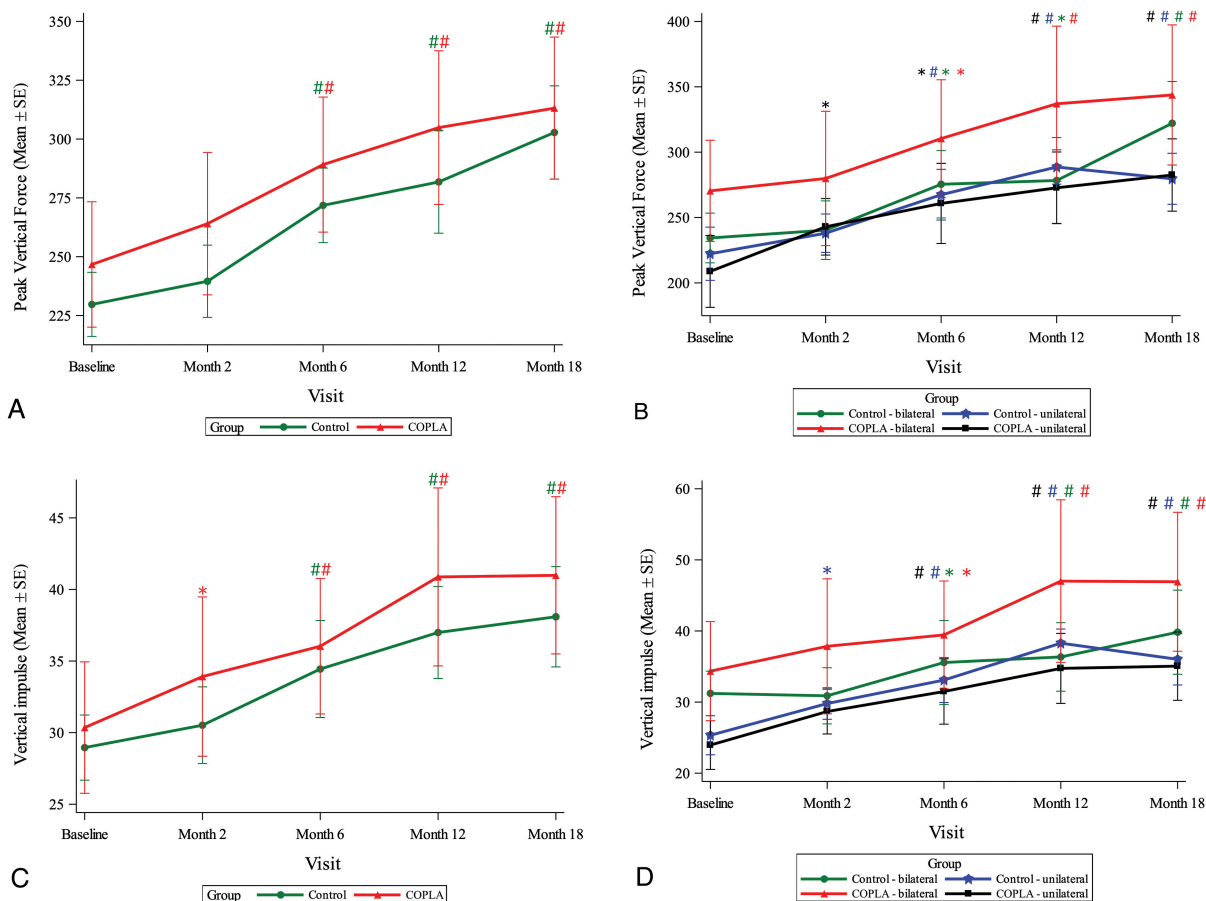


Fig. 2 (A) Peak vertical force (100 N/N) measured with a force platform in dogs with shoulder osteochondritis dissecans treated with arthroscopic debridement and a poly lactide–collagen scaffold (COPLA) or arthroscopic debridement only (Control). #: $p < 0.01$ compared with baseline within group. $n = 12–14$ for COPLA and $n = 11–15$ for Control. (B) Peak vertical force (100 N/N) measured with a force platform in dogs with shoulder osteochondritis dissecans treated with arthroscopic debridement and a COPLA or Control. Data for unilaterally and bilaterally operated dogs are presented separately. *: $p < 0.05$ compared with baseline within group, #: $p < 0.01$ compared with baseline within group. $n = 5–8$ for COPLA and $n = 4–10$ for Control. (C) Vertical impulse (100 N s/N) measured with a force platform in dogs with shoulder osteochondritis dissecans treated with arthroscopic debridement and a COPLA or Control. *: $p < 0.05$ compared with baseline within group, #: $p < 0.01$ compared with baseline within group. $n = 12–14$ for COPLA and $n = 11–15$ for Control. (D) Vertical impulse (100 N s/N) measured with a force platform in dogs with shoulder osteochondritis dissecans treated with arthroscopic debridement and a COPLA or Control. Data for unilaterally and bilaterally operated dogs are presented separately. *: $p < 0.05$ compared with baseline within group; #: $p < 0.01$ compared with baseline within group. $n = 5–8$ for COPLA and $n = 4–10$ for Control.

(2 [14%] vs. 10 [67%], $p = 0.019$). However, this difference was not significant at 1.5 years (9 [64%] vs. 9 [60%], $p = 0.407$; ►Fig. 6). Fewer dogs developed moderate or severe OA in COPLA compared with the Control group (1 [7%] vs. 6 [40%] at 6 months and (2 [14%] vs. 5 [33%] at 1.5 years, but the difference was not significant ($p = 0.091$ and $p = 0.178$, respectively; ►Fig. 6; ►Appendix Table 5 [available in the online version]).

Adverse Events

Two major adverse events were recorded. One dog in the Control group was euthanized due to severe lameness and pain in the operated shoulder 6 months postoperatively. Severe OA was observed with CT. A gross examination of the shoulder revealed synovitis and loose connective tissue in the OCD lesion.

One dog in the COPLA group became lame 6 months postoperatively. Imaging showed a loose fragment in a pit

on the humeral joint surface at the site of the former OCD lesion. A round, convex, and sharp-edged fragment of 5 mm diameter was removed in arthroscopy. Fibrous cartilage with some necrotic areas covered the surface of the pit. The pit was debrided to the bleeding bone. The histopathology of the fragment was consistent with calcified cartilage joint mice; no inflammation or foreign material was detected.

Four minor adverse events were recorded. Two COPLA dogs had skin irritation in the wound, and one Control dog had seroma and mild wound dehiscence. These healed with local treatment. One Control dog had an allergic reaction following IV cefazolin. The dog recovered with IV hydrocortisone, and surgery was rescheduled.

Discussion

We investigated the use of a novel biodegradable COPLA scaffold in the treatment of shoulder OCD in dogs in a

Table 1 Proportion of static weight-bearing on the operated limb expressed as a percentage of body weight measured with a force platform

Variable	Group	Baseline	Month 2	Month 6	Month 12	Month 18	
Proportion of weight-bearing on operated limb (%)	COPLA Bilateral	<i>n</i>	8	8	8	8	
		Mean ± SD	31.3 ± 6.5	30.4 ± 3.4	31.1 ± 3.8	33.6 ± 6.0	32.1 ± 4.7
		Total range	22.3–41.0	26.5–34.5	24.7–36.0	26.0–35.6	18.0–41.8
COPLA Unilateral	Control Bilateral	<i>n</i>	6	6	6	6	
		Mean ± SD	27.7 ± 4.2	28.6 ± 6.0	33.2 ± 5.3	30.0 ± 6.0	35.3 ± 4.3 ^a
		Total range	21.7–34.3	21.3–33.0	23.5–38.0	23.3–32.3	31.3–41.0
Control Bilateral	Control Unilateral	<i>n</i>	8	10	10	8	
		Mean ± SD	29.7 ± 8.4	30.7 ± 3.6	30.2 ± 4.9	31.9 ± 7.0	31.5 ± 6.2
		Total range	18.0–41.8	25.5–36.8	23.0–38.0	24.5–37.2	26.5–43.5
Control Unilateral	Control Unilateral	<i>n</i>	5	5	5	4	
		Mean ± SD	29.1 ± 4.8	31.3 ± 3.2	32.8 ± 4.1	31.8 ± 4.7	32.3 ± 2.0
		Total range	26.0–35.6	23.3–32.3	24.5–37.2	26.7–35.4	30.3–34.3

Abbreviations: Control, dogs with shoulder osteochondritis dissecans (OCD) treated with arthroscopic debridement only; COPLA, dogs with shoulder OCD treated with arthroscopic debridement and a poly(lactide–collagen scaffold); SD, standard deviation.

^aResult is significant ($p < 0.05$ for change from baseline within the group).

Table 2 Proportion of static weight-bearing on forelimbs expressed as a percentage of body weight measured with a force platform

Variable	Group	Baseline	Month 2	Month 6	Month 12	Month 18	
Proportion of weight-bearing on forelimbs (percent)	COPLA Bilateral	<i>n</i>	4	4	4	4	
		Mean ± SD	62.7 ± 4.7	60.8 ± 2.0	62.2 ± 2.6	67.2 ± 9.0	64.1 ± 2.9
		Total range	58.3–67.3	58.0–62.3	60.3–66.0	60.5–80.3	61.4–68.0
COPLA Unilateral	Control Bilateral	<i>n</i>	6	6	6	6	
		Mean ± SD	60.4 ± 3.6	62.6 ± 2.4	62.1 ± 2.1	64.5 ± 1.1	63.5 ± 1.7
		Total range	54.3–64.3	59.0–66.5	59.8–65.3	63.3–66.2	60.7–65.3
Control Bilateral	Control Unilateral	<i>n</i>	4	5	5	4	
		Mean ± SD	59.4 ± 0.8	61.3 ± 3.4	60.4 ± 3.9	63.7 ± 4.2	63.1 ± 6.0
		Total range	58.3–60.0	57.5–65.8	56.8–66.8	59.3–69.3	59.5–70.0
Control Unilateral	Control Unilateral	<i>n</i>	5	5	5	4	
		Mean ± SD	61.6 ± 5.9	62.6 ± 3.9	64.5 ± 2.5	61.0 ± 4.1	63.4 ± 2.2
		Total range	53.2–69.7	59.8–68.4	62.4–68.3	56.7–66.0	60.3–66.0

Abbreviations: Control, dogs with shoulder osteochondritis dissecans (OCD) treated with arthroscopic debridement only; COPLA, dogs with shoulder OCD treated with arthroscopic debridement and a poly(lactide–collagen scaffold); SD, standard deviation.

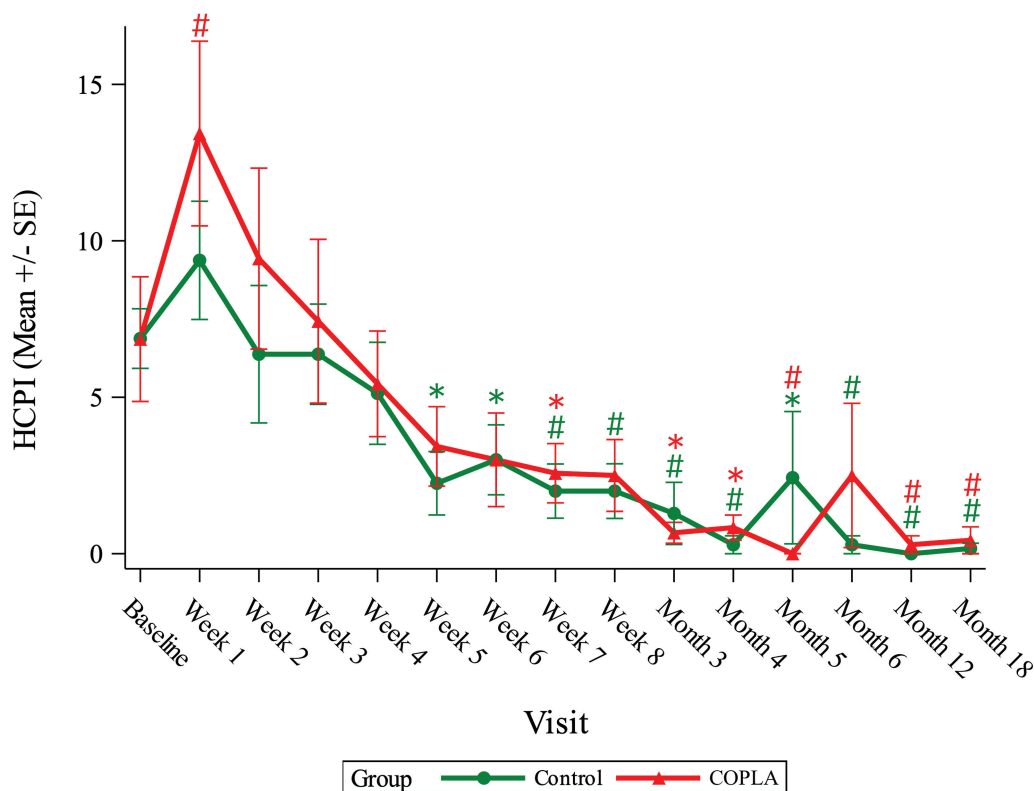


Fig. 3 Helsinki Chronic Pain Index (HCPI) in dogs with shoulder osteochondritis dissecans treated with arthroscopic debridement and a poly lactide–collagen scaffold (COPLA) or with arthroscopic debridement only (Control). *: $p < 0.05$ compared with baseline within group; #: $p < 0.01$ compared with baseline within group. $n = 6–7$ for COPLA and $n = 6–8$ for Control.

randomized, blinded, controlled clinical trial. Contrary to our hypothesis, the COPLA scaffold did not improve recovery or prevent OA compared with arthroscopic debridement only. Although no difference in OA prevalence was detected between the groups at 1.5 years posttreatment, the prevalence of OA was significantly lower in COPLA than in Control shoulders at 6 months. While the reason for this is unknown, we speculate that sealing and filling in the cartilage defect

might have led to a more favourable microenvironment, delaying degenerative changes in the joint.

We report good clinical recovery after shoulder OCD treatment in both the COPLA and Control groups during the 1.5-year follow-up. The results of our prospective study confirm the findings of most previously published retrospective studies and case series on the treatment of canine shoulder OCD. Only Zann and colleagues have published

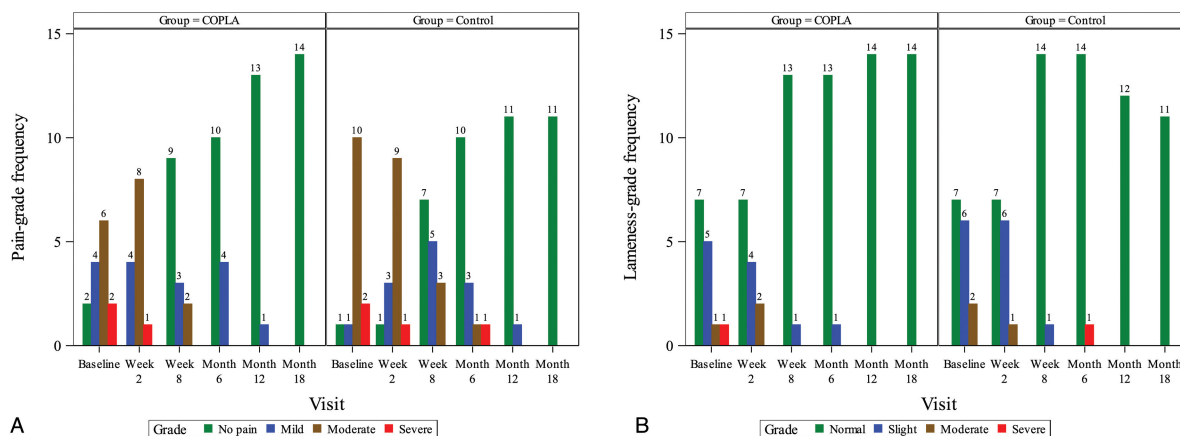


Fig. 4 (A) Pain scores evaluated by a veterinarian in dogs with shoulder osteochondritis dissecans treated with arthroscopic debridement and a poly lactide–collagen scaffold (COPLA) or with arthroscopic debridement only (Control). $n = 13–14$ for COPLA and $n = 11–15$ for Control. (B) Lameness scores were evaluated by a veterinarian in dogs with shoulder osteochondritis dissecans treated with arthroscopic debridement and a poly lactide–collagen scaffold (COPLA) or with arthroscopic debridement only (Control). $n = 13–14$ for COPLA and $n = 11–15$ for Control.

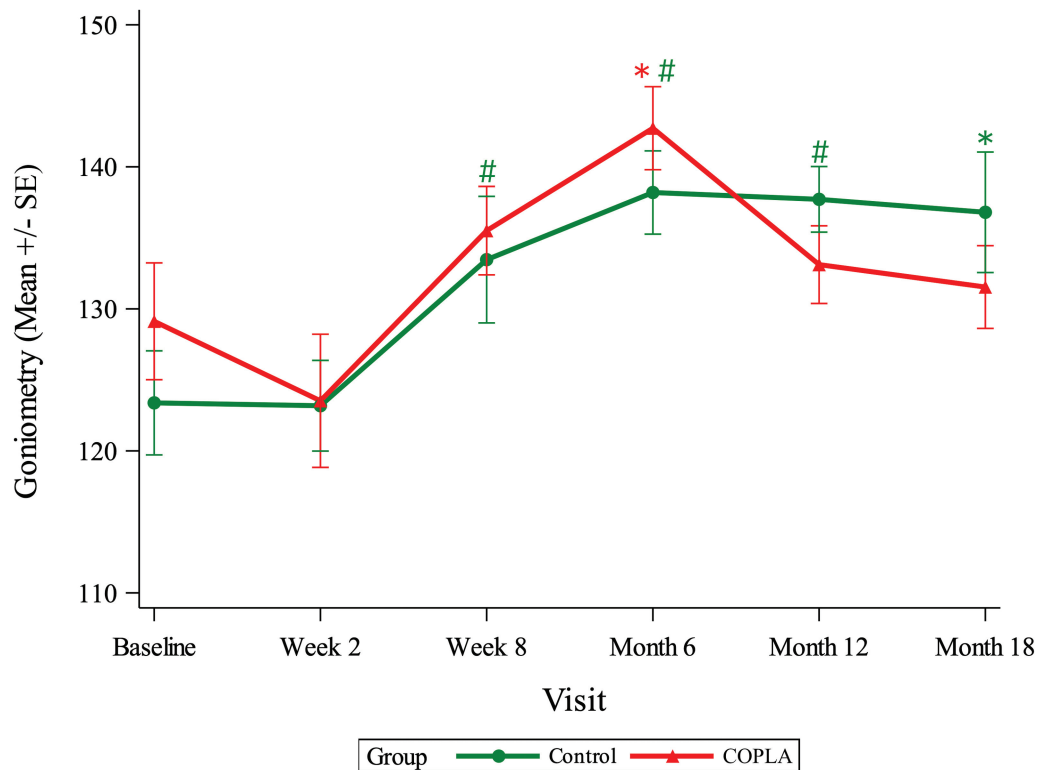


Fig. 5 Passive range of motion (degrees) of shoulder joints measured with a goniometer in dogs with osteochondritis dissecans treated with arthroscopic debridement and a poly lactide–collagen scaffold (COPLA) or with arthroscopic debridement only (Control). *: $p < 0.05$ compared with baseline within group; #: $p < 0.01$ compared with baseline within group. $n = 12–14$ for COPLA and $n = 9–15$ for Control.

Table 3 Length, width, and depth of shoulder osteochondritis dissecans lesion evaluated with computed tomography

Variable	Group		Baseline	Month 6	Month 18
OCD lesion length (mm)	COPLA	<i>n</i>	14	12	14
		Mean ± SD	9.7 ± 2.6	9.1 ± 2.5 ^a	7.3 ± 2.8 ^b
		Total range	5.6–14.1	5.2–14.2	1.5–11.0
	Control	<i>n</i>	15	15	11
		Mean ± SD	10.9 ± 1.6	9.2 ± 2.1 ^b	8.2 ± 2.9 ^b
		Total range	7.8–14.0	5.0–12.0	3.3–11.7
OCD lesion width (mm)	COPLA	<i>n</i>	14	12	14
		Mean ± SD	9.5 ± 2.8	8.6 ± 2.7 ^a	6.6 ± 3.2 ^b
		Total range	4.0–13.0	3.9–13.0	1.0–13.0
	Control	<i>n</i>	15	15	11
		Mean ± SD	10.2 ± 2.9	8.0 ± 3.1 ^b	6.9 ± 3.6 ^b
		Total range	5.5–14.0	2.3–13.0	2.0–13.0
OCD lesion depth (mm)	COPLA	<i>n</i>	14	12	14
		Mean ± SD	2.4 ± 1.3	3.4 ± 1.3 ^{a,c}	1.6 ± 1.2 ^a
		Total range	1.2–6.3	1.0–5.8	0.4–3.7
	Control	<i>n</i>	15	15	11
		Mean ± SD	2.2 ± 0.9	2.0 ± 1.2 ^c	1.4 ± 1.0 ^b
		Total range	1.1–4.0	0.7–5.5	0.5–3.8

Abbreviations: Control, dogs with shoulder OCD treated with arthroscopic debridement only; COPLA, dogs with shoulder OCD treated with arthroscopic debridement and a poly lactide–collagen scaffold; OCD, osteochondritis dissecans; SD, standard deviation.

^aResult is significant ($p < 0.05$ for change from baseline within group).

^bResult is significant ($p < 0.01$ for change from baseline within group).

^cResult is significant ($p < 0.05$ for change from baseline between groups).

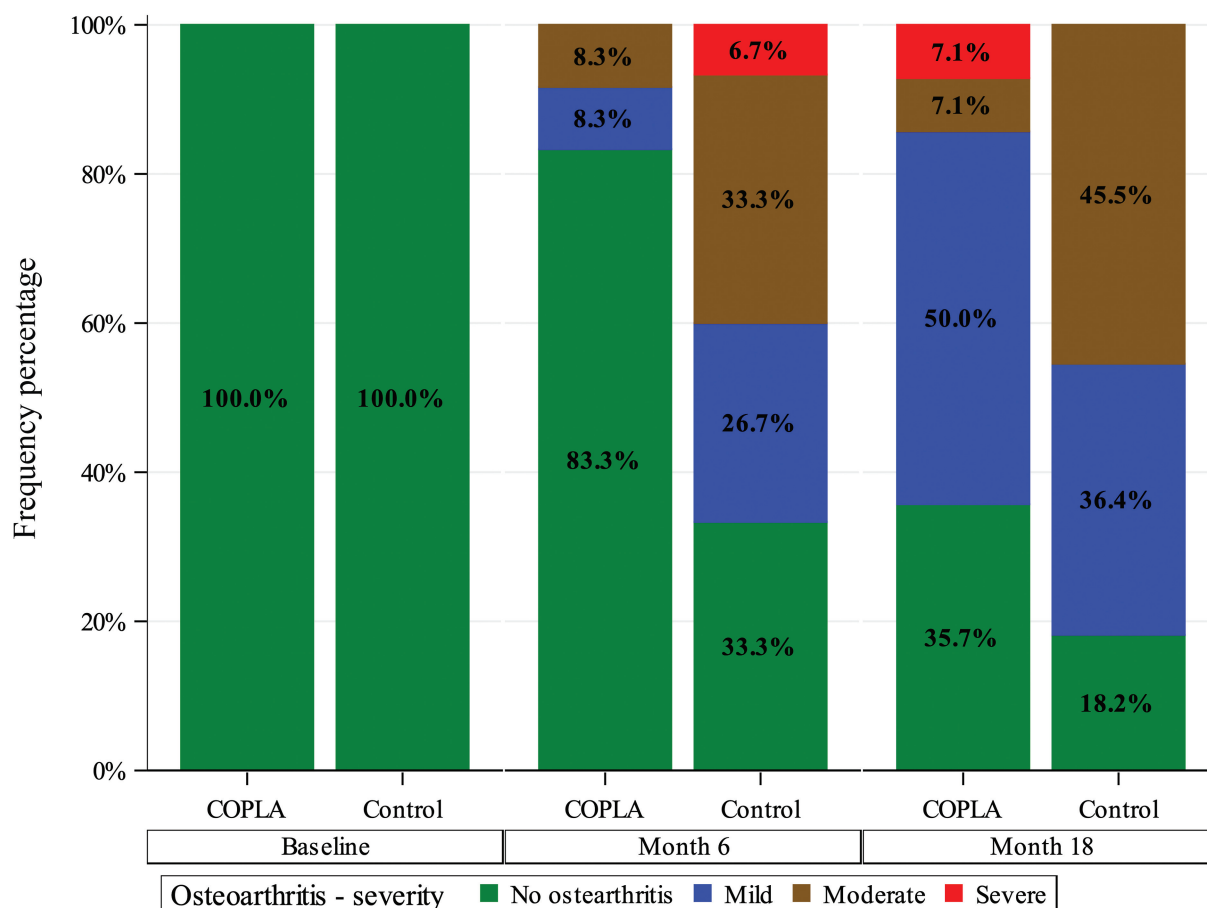


Fig. 6 Severity of osteoarthritis in shoulder joints of dogs with osteochondritis dissecans treated with arthroscopic debridement and a poly lactide–collagen scaffold (COPLA) or with arthroscopic debridement only (Control) evaluated in computed tomography. $n = 12–14$ for COPLA and $n = 11–15$ for Control.

contradictory results.¹³ In their report, lameness, muscle atrophy, and decreased range of joint motion were seen in most dogs at a mean of 3.5 years after shoulder OCD debridement. However, direct comparison with our results is difficult because Zann and colleagues provide examination findings from a single postoperative time point, and details of the study population at the time of surgery, such as size of OCD lesion, presence of OA, and age and weight of dogs, are not presented.¹³

Although the ground reaction forces at trot improved significantly in our dogs, indicating better dynamic weight-bearing on the operated limbs during the study, only mild increases were detected in static weight-bearing. Thus, we speculate that shoulder OCD might be manifested more as pain during trot than as pain in static joint loading. Static weight-bearing improved significantly only in the unilaterally operated COPLA limbs. At 1.5 years, unilaterally operated dogs in the COPLA group bore 35% of body weight on the operated limbs, while bearing 63.5% of body weight on forelimbs. This would indicate more weight-bearing on the operated limb than on the contralateral healthy limb. Although interesting, we do not have an explanation for this finding. One consideration might be the tool itself. The Stance Analyzer has been studied for its reliability with hindlimb lame dogs but not with forelimb lame ones.³² Actually, the

forelimb-related measurements were found not to be repeatable in the named cohort of hindlimb lame dogs. The Stance Analyzer's validity and accuracy have been tested against a pressure-sensitive walkway with weights.³³ It was shown to be accurate and consistent but was not tested with dogs. This should be considered when interpreting the result of our study. Having said that, the tool is calibrated against known weight prior to each measurement time, and the measurement method is standardized. Thus, despite the lack of forelimb-specific reliability and clinical validity-related information, the Stance Analyzer was used as an objective outcome measure. Moreover, the information gained from this tool is of interest, as there are no studies reporting static weight-bearing in dogs with shoulder OCD or with other orthopaedic conditions of the forelimb. However, we do not want to overemphasize our findings as the improvement from baseline did not differ significantly between the groups.

Interestingly, the PROM improved more in Control than COPLA shoulders during the study. The scaffold was placed in mini-arthrotomy, while the Control shoulders were debrided in arthroscopy. The more invasive mini-arthrotomy could have incurred more periarticular fibrosis. The dogs in the COPLA group also had longer surgical time and a significant increase in HCPI, indicating more pain at 1 week postoperatively. These findings should be considered when considering

restorative techniques requiring mini-arthrotomy in OCD treatment.

Despite good clinical recovery, OA was detected in 18/25 shoulders (72%) at 1.5 years. Zann and colleagues detected OA in all examined dogs at a mean of 3.5 years postoperatively, and this might be the fate of also our dogs.¹³ However, in contrast to Zann and colleagues, our dogs were not lame.¹³ The clinical relevance of OA in asymptomatic dogs is unclear. Whether our dogs develop lameness impairing their welfare later in life is a subject for future research.

A relatively small number of studied joints increases the likelihood of type II error in our results. Thus, at least our study does not give an overly positive picture of the use of this scaffold. Another limitation is that we were unable to evaluate cartilage regeneration, as cartilage is not visible in CT. Our National Animal Experimental Board's approval did not include permission to perform a second-look arthroscopy because this would have been regarded as too invasive considering the good clinical recovery of client-owned dogs.

Conclusion

The indicators of functionality showed good clinical recovery in dogs with shoulder OCD treated either with a COPLA scaffold or with arthroscopic debridement only. In long-term follow-up at 1.5 years, the use of the COPLA scaffold did not improve clinical recovery or prevent OA relative to dogs treated with arthroscopic debridement only. However, shoulders treated with the scaffold had significantly less OA at 6 months. Our study emphasizes the importance of a prospective controlled study design and a long-term follow-up.

Authors' Contribution

H.H. contributed to the study design, performed the veterinary evaluations, prepared the manuscript, and was responsible for owner communication and dogs' visits at the hospital. V.R. contributed to the study design, performed the data collection, analysis, and interpretation of results of diagnostic imaging, and contributed to the manuscript. H.K. H. performed the data collection, analysis, and interpretation of results of biomechanical measurements, and contributed to the manuscript. J.J.T.J. performed the statistical analysis, wrote the "Statistical Analysis" section, and provided the figures. O.L.-V. contributed to study design, supervised, and contributed to the manuscript. P.K. developed the concept of the study, contributed to the study design, developed, and performed the surgical part of the study, supervised, and contributed to the manuscript.

Funding

This study was supported by grants from the Finnish Foundation of Veterinary Research, the Finnish Veterinary Foundation, and the Helsinki University Orthopedic Research Unit. Askel Healthcare provided the COPLA scaffolds and paid one-fifth of the study costs.

Conflict of Interest

None declared.

Acknowledgment

The authors acknowledge Mikael Morelius, DVM, for help in rehearsing the surgery and for performing arthroscopy for the last patient. Askel Healthcare participated in study planning, provided the COPLA Scaffolds used in the study, and paid one-fifth of the study costs, but the company had no impact on the results.

References

- van Bree HJ, Van Ryssen B. Diagnostic and surgical arthroscopy in osteochondrosis lesions. *Vet Clin North Am Small Anim Pract* 1998;28(01):161–189
- Johnston SA. Osteoarthritis. Joint anatomy, physiology, and pathobiology. *Vet Clin North Am Small Anim Pract* 1997;27(04):699–723
- Breur GJ, Lambrechts NE. Osteochondrosis. In: Johnston SA, Tobias KM, eds. *Veterinary Surgery Small Animals*. St. Louis: Elsevier; 1998:1372–1385
- Fitzpatrick N, van Terheijden C, Yeadon R, Smith TJ. Osteochondral autograft transfer for treatment of osteochondritis dissecans of the caudocentral humeral head in dogs. *Vet Surg* 2010;39(08):925–935
- Danielski A, Farrell M. Use of synthetic osteochondral implants to treat bilateral shoulder osteochondritis dissecans in a dog. *Vet Comp Orthop Traumatol* 2018;31(05):385–389
- Murphy SC, Egan PM, Fitzpatrick NM. Synthetic osteochondral resurfacing for treatment of large caudocentral osteochondritis dissecans lesions of the humeral head in 24 dogs. *Vet Surg* 2019;48(05):858–868
- Franklin SP, Stoker AM, Murphy SM, et al. Outcomes associated with osteochondral allograft transplantation in dogs. *Front Vet Sci* 2021;8:759610
- Ryssen BV, Bree HV, Missinne S. Successful arthroscopic treatment of shoulder osteochondrosis in the dog. *J Small Anim Pract* 1993;34:521–528
- Person MW. Arthroscopic treatment of osteochondritis dissecans in the canine shoulder. *Vet Surg* 1989;18(03):175–189
- Olivieri M, Ciliberto E, Hulse DA, Vezzoni A, Ingravalle F, Peirone B. Arthroscopic treatment of osteochondritis dissecans of the shoulder in 126 dogs. *Vet Comp Orthop Traumatol* 2007;20(01):65–69
- Biezyński J, Skrzypczak P, Piatek A, Kościółek N, Drozdzyńska M. Assessment of treatment of osteochondrosis dissecans (OCD) of shoulder joint in dogs—the results of two years of experience. *Pol J Vet Sci* 2012;15(02):285–290
- Vezzoni A, Vezzoni L, Boiocchi S, Miolo A, Holsworth IG. A modification of the Cheli craniolateral approach for minimally invasive treatment of osteochondritis dissecans of the shoulder in dogs: description of the technique and outcome in 164 Cases. *Vet Comp Orthop Traumatol* 2021;34(02):130–136
- Zann GJ II, Jones SC, Selmic LS, et al. Long-term outcome of dogs treated by surgical debridement of proximal humeral osteochondrosis. *Vet Surg* 2023;52(06):810–819
- Haaparanta A-M, Järvinen E, Cengiz IF, et al. Preparation and characterization of collagen/PLA, chitosan/PLA, and collagen/chitosan/PLA hybrid scaffolds for cartilage tissue engineering. *J Mater Sci Mater Med* 2014;25(04):1129–1136
- Muhonen V, Salenius E, Haaparanta A-M, et al. Articular cartilage repair with recombinant human type II collagen/poly lactide scaffold in a preliminary porcine study. *J Orthop Res* 2016;34(05):745–753
- Salenius E, Meller A, Paatela T, et al. Cartilage repair capacity within a single full-thickness chondral defect in a porcine autologous matrix-induced chondrogenesis model is affected by the location within the defect. *Cartilage* 2021;13(2_suppl):744S–754S
- Grönthal T, Moodley A, Nykäsenoja S, et al. Large outbreak caused by methicillin resistant *Staphylococcus pseudintermedius* ST71 in a

- Finnish Veterinary Teaching Hospital—from outbreak control to outbreak prevention. *PLoS One* 2014;9(10):e110084
- 18 Kennedy EJ, Corriveau KM, Wilhite R. Evaluation of canine shoulder arthroscopy for anatomical and safety considerations. *Vet Comp Orthop Traumatol* 2024;37(04):181–188
 - 19 Holman SN, Schaefer SL. Quantification of the field of view for standard lateral arthroscopy of the canine shoulder. *Vet Comp Orthop Traumatol* 2024;37(01):37–42
 - 20 Beale BS, Hulse DA, Schulz KS, Whitney WO. Arthroscopically assisted surgery of the shoulder joint. In: *Small animal arthroscopy*. Philadelphia: Saunders; 2003:23–49
 - 21 Mölsä SH, Hyytiäinen HK, Morelius KM, Palmu MK, Pesonen TS, Lappalainen AK. Radiographic findings have an association with weight bearing and locomotion in English bulldogs. *Acta Vet Scand* 2020;62(01):19
 - 22 Hielm-Björkman AK, Rita H, Tulamo RM. Psychometric testing of the Helsinki Chronic Pain Index by completion of a questionnaire in Finnish by owners of dogs with chronic signs of pain caused by osteoarthritis. *Am J Vet Res* 2009;70(06):727–734
 - 23 Jaegger G, Marcellin-Little DJ, Levine D. Reliability of goniometry in Labrador retrievers. *Am J Vet Res* 2002;63(07):979–986
 - 24 Heikkilä HM, Hielm-Björkman AK, Morelius M, et al. Intra-articular botulinum toxin A for the treatment of osteoarthritic joint pain in dogs: a randomized, double-blinded, placebo-controlled clinical trial. *Vet J* 2014;200(01):162–169
 - 25 Reis Silva H, Uosyte R, Clements DN, Bergkvist GT, Schwarz T. Computed tomography and positive contrast computed tomographic arthrography of the canine shoulder: normal anatomy and effects of limb position on visibility of soft tissue structures. *Vet Radiol Ultrasound* 2013;54(05):470–477
 - 26 Carrig CB. Diagnostic imaging of osteoarthritis. *Vet Clin North Am Small Anim Pract* 1997;27(04):777–814
 - 27 Lande R, Reese SL, Cuddy LC, Berry CR, Pozzi A. Prevalence of computed tomographic subchondral bone lesions in the scapulo-humeral joint of 32 immature dogs with thoracic limb lameness. *Vet Radiol Ultrasound* 2014;55(01):23–28
 - 28 Eivers CR, Corzo-Menéndez N, Austwick SH, et al. Computed tomographic arthrography is a useful adjunct to survey computed tomography and arthroscopic evaluation of the canine shoulder joint. *Vet Radiol Ultrasound* 2018;59(05):535–544
 - 29 Moores AP, Benigni L, Lamb CR. Computed tomography versus arthroscopy for detection of canine elbow dysplasia lesions. *Vet Surg* 2008;37(04):390–398
 - 30 Shubert MP, Filliquist B, Chou PY, et al. Results of using multi-planar reconstructed CT images for assessing elbow joint osteoarthritis in dogs are consistent with results of radiographic assessment. *Am J Vet Res* 2022;83(10):10
 - 31 European Medicines Agency. ICH E9 Statistical Principles for Clinical Trials—Scientific Guideline [Internet]. EMEA; 1998. Accessed 26 June, 2024 at: <https://www.ema.europa.eu/en/ich-e9-statistical-principles-clinical-trials-scientific-guideline#current-version-section/>
 - 32 Wilson ML, Roush JK, Renberg WC. Single-day and multiday repeatability of stance analysis results for dogs with hind limb lameness. *Am J Vet Res* 2019;80(04):403–409
 - 33 Bosscher G, Tomas A, Roe SC, Marcellin-Little DJ, Lascelles BD. Repeatability and accuracy testing of a weight distribution platform and comparison to a pressure sensitive walkway to assess static weight distribution. *Vet Comp Orthop Traumatol* 2017;30(02):160–164