



# Is Endoscopic Retrograde Cholangiopancreatography with Balloon Sweeps a Must in Postcholecystectomy Stent Removal for Choledocholithiasis?

Deepak Sasikumar<sup>1</sup> Saiprasad Lad<sup>1</sup> Meghraj Ingle<sup>1</sup> Chintan Tailor<sup>1</sup> Vikramaditya Rawat<sup>1</sup>  
Mit Shah<sup>1</sup> Kiran Basavaraju<sup>1</sup> Yatin Lunagariya<sup>1</sup> Shivani Chopra<sup>1</sup> Vinay Borkar<sup>1</sup>

<sup>1</sup> Department of Gastroenterology, Lokmanya Tilak Municipal Medical College and General Hospital, Sion, Mumbai, India

Address for correspondence Dr. Meghraj Ingle, MD, DNB (Medicine), DrNB (Gastroenterology), Department of Gastroenterology, Lokmanya Tilak Municipal Medical College and General Hospital, Sion, Mumbai 400022, India (e-mail: gastroSION@gmail.com).

J Digest Endosc 2024;15:157–162.

## Abstract

**Objectives** This study aims to evaluate whether stent removal through endoscopic retrograde cholangiopancreatography (ERCP) with balloon sweeps is necessary or whether stent removal by forward-viewing gastroscopy without cholangiogram is sufficient.

**Materials and Methods** A prospective, single-center study was conducted from April 2022 to March 2023 for 1 year. Adult patients with choledocholithiasis who underwent common bile duct (CBD) clearance and CBD stenting followed by cholecystectomy were included. Then, they underwent CBD stent removal either by gastroscopy directly or by side-viewing endoscopy with balloon sweeps and occlusion cholangiogram. Recurrence of stones and complications after stent removal were studied in both groups.

**Results** Forty-seven patients were enrolled in the final study. A total of 64% of patients ( $n = 30$ ) underwent CBD stent removal followed by balloon sweeps and cholangiogram, and the remaining 34% ( $n = 17$ ) patients underwent direct stent removal. Time taken for the procedure was more in the balloon sweeps group compared with the direct stent removal group and was statistically significant. No statistically significant adverse events were seen in both groups.

**Conclusion** Patients who underwent CBD stenting for choledocholithiasis after cholecystectomy can safely undergo stent removal using a gastroscopy rather than be subjected again to ERCP. This will significantly reduce the duration, unplanned adverse events, and cost of ERCP.

## Keywords

- ▶ Choledocholithiasis
- ▶ Cholecystectomy
- ▶ Endoscopic retrograde cholangiopancreatography
- ▶ Gastroscopy

## Introduction

Symptomatic gallstone disease is a leading cause of hospital admissions, with higher incidence in females compared with males.<sup>1</sup> In patients undergoing cholecystectomy for gallstones, 10 to 15% of patients have concomitant common bile duct (CBD) stones.<sup>2</sup> In these patients, the most common two-step approach is used, which is endoscopic stone extraction fol-

lowed by cholecystectomy. A single-step approach of combining cholecystectomy and CBD exploration is less commonly used. In patients undergoing two-step approach, it is common practice to perform prophylactic CBD stent placement even after complete CBD clearance is achieved. The recurrence rate of choledocholithiasis after endoscopic retrograde cholangiopancreatography (ERCP) is between 2 and 22%.<sup>3</sup> There are

article published online  
September 2, 2024

DOI <https://doi.org/10.1055/s-0044-1788724>.  
ISSN 0976-5042.

© 2024. The Author(s).

This is an open access article published by Thieme under the terms of the Creative Commons Attribution License, permitting unrestricted use, distribution, and reproduction so long as the original work is properly cited. (<https://creativecommons.org/licenses/by/4.0/>)  
Thieme Medical and Scientific Publishers Pvt. Ltd., A-12, 2nd Floor, Sector 2, Noida-201301 UP, India

three possible explanations for such recurrence, which are precholecystectomy, during cholecystectomy, or de novo development of stone in the CBD.<sup>4</sup> For first two scenarios, prophylactic CBD stent during index ERCP can mitigate risk-related CBD stones, and these stones can be subsequently removed during stent removal by balloon sweep.

There is no formal recommendation about performing repeat ERCP during stent removal, and it can be associated with added cost and risk of adverse events. There is not enough evidence to recommend ERCP for all patients undergoing stent removal postcholecystectomy. The current study aimed to compare direct stent removal and ERCP with balloon sweep.

## Methods

### Study Population

This is a prospective study conducted at the Lokmanya Tilak Medical College and Sion Hospital, Mumbai between April 2022 and March 2023. The institutional ethics committee approval was obtained for the current study. All patients who underwent ERCP for choledocholithiasis with CBD stent placement followed by cholecystectomy were screened for enrollment. Those patients who did not undergo cholecystectomy, malignancy, chronic kidney disease, patients taking hepatotoxic drugs, pregnancy, or abnormal liver function test or ultrasonography (USG) abdomen at the time of stent removal were excluded. All included patients were divided into two groups: Group 1 (balloon sweep group) in whom ERCP with balloon sweep and occlusion cholangiogram was performed and Group 2 (direct stent removal group) stent removal was performed directly using gastroscope as per endoscopist preference.

The recurrence of stone, ERCP-related complications, time between cholecystectomy and stent removal, and duration of procedure in both groups were noted. All patients were subsequently followed for next 8 weeks for occurrence of abdominal pain, gastrointestinal bleeding, blood and radiological investigation whenever indicated.

The primary outcome was recurrence of CBD stone requiring repeat ERCP at the time of stent removal. Secondary outcomes were ERCP-related complications, duration of the procedure, and cost-effectiveness of the procedure.

### Statistical Analysis

Categorical variables were expressed as number and proportion and continuous variables were expressed as mean and standard deviation. Categorical variables were compared with the chi-square test or Fisher's exact test wherever required. Continuous variables were compared with an independent *t*-test. The *p*-value of <0.05 was considered statistically significant. All statistical analysis was performed using IBM SPSS version 22.<sup>5</sup>

## Results

A total of 47 patients were included in the study. Thirteen patients who did not meet inclusion criteria were excluded.

Group 1 (*n* = 30, 64%) underwent balloon sweep during ERCP, whereas group 2 (*n* = 17, 36%) underwent direct stent removal (►Fig. 1). Majority of patients underwent laparoscopic cholecystectomy (*n* = 40, 90%); rest underwent open cholecystectomy.

Group 1 (*n* = 30, 64%) underwent balloon sweep during ERCP, whereas group 2 (*n* = 17, 36%) underwent direct stent removal (►Fig. 1). Majority of patients underwent laparoscopic cholecystectomy (*n* = 40, 90%); rest underwent open cholecystectomy. Abdominal pain was the most common symptom for which patients presented to the hospital (90%; ►Table 1).

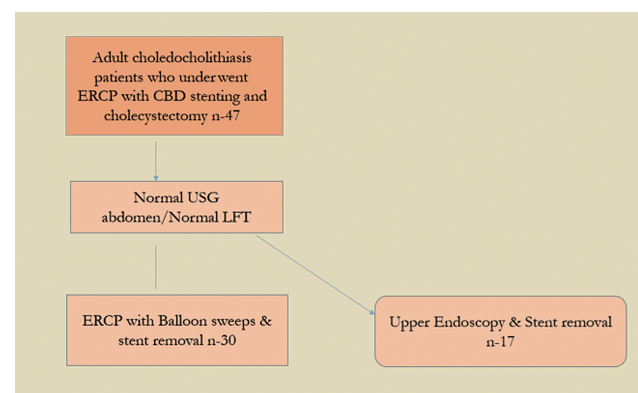
Following precholecystectomy ERCP, four patients had post-ERCP complications. Subsequently, three of them underwent balloon sweeps during the stent removal.

Following the second ERCP, two patients who underwent balloon sweeps had persistent abdominal pain (6%) (abdominal pain resolving with oral analgesics but without evidence of any other complications like pancreatitis, cholangitis, perforation) and one patient had post-ERCP pancreatitis (biochemical and radiological evidence of pancreatitis; ►Fig. 2).

There was one patient who had persistent abdominal pain in the direct stent removal group (5.88%) and later the same patient developed a recurrence of stone and cholangitis (►Table 2). Recurrence of stone after stent removal was seen only in group 2 (1 out of 17 patients); however, a significant association was not found using Fisher's exact test (*p* = 0.362) among both the groups. None of the patients in either group had bleeding or perforation after stent removal.

All patients underwent cholecystectomy after index ERCP by 4th week. The majority of patients in either group underwent stent removal within 4 weeks (80% in group 1 and 76% in group 2 as shown in ►Table 3).

The mean duration of the procedure in group 1 was 29.3 ± 5.40 minutes and the mean duration in group 2 (which was also an unsedated procedure) was 11.941 ± 1.71 minutes. On applying one-way analysis of variance, the difference was statistically significant as there was less procedural time and less anesthesia-related side effects (►Table 4).

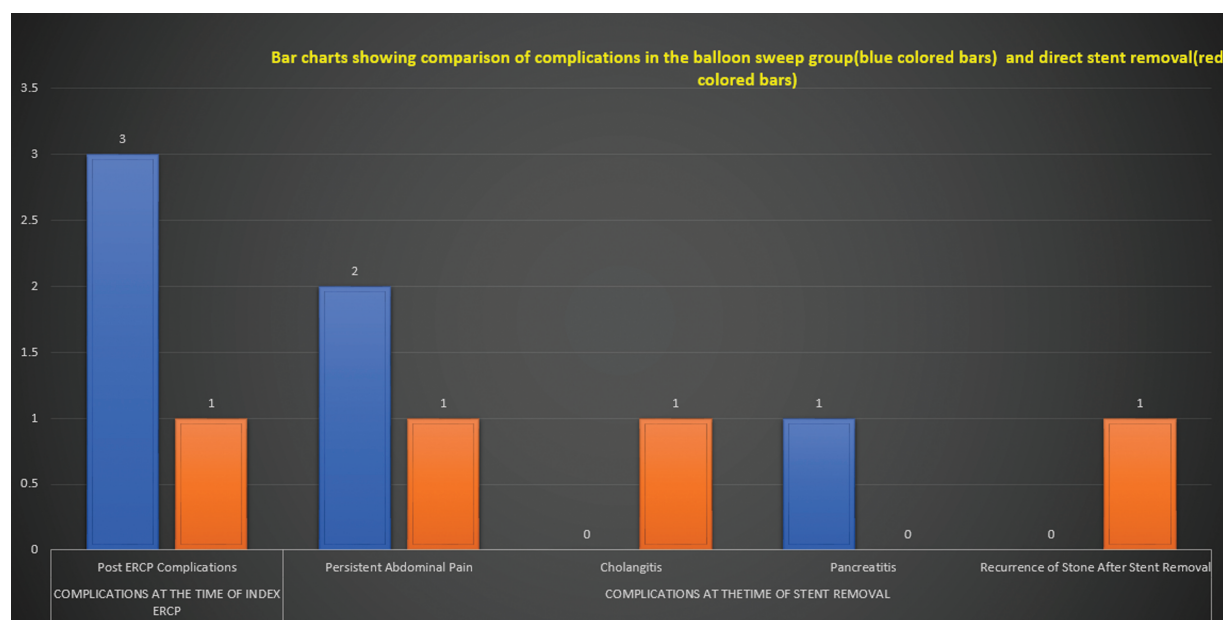


**Fig. 1** Flow chart depicting the recruitment of patients into two groups for stent removal. CBD, common bile duct; ERCP, endoscopic retrograde cholangiopancreatography; LFT, liver functional test; USG, ultrasonography.

**Table 1** Patient demographics, type of cholecystectomy underwent, symptomatic (yes/no) at the time of first endoscopic retrograde cholangiopancreatography, and recurrence of stone after stent removal

	Group 1 or balloon sweep group (N = 30)	Group 2 or direct stent removal group (N = 17)
Mean patient age (y)	46.93	46.8
Sex (male/female)	11/19	5/12
Type of cholecystectomy—open/laparoscopic	3/27	4/13
Symptomatic at the time of first ERCP (yes/no)	25/5	15/2
Recurrence of stone after stent removal (yes/no)	0/30	1/16

Abbreviation: ERCP, endoscopic retrograde cholangiopancreatography.



**Fig. 2** Bar chart showing complications at the time of index ERCP and at the time of stent removal in both the groups. ERCP, endoscopic retrograde cholangiopancreatography.

**Table 2** Comparison of complications at the time of index endoscopic retrograde cholangiopancreatography and at the time of stent removal in both the groups

Complications	Method of stent removal		Fisher exact p-value
	Balloon sweep group	Direct stent removal group	
Post-ERCP complications at the time of initial CBD stenting	3 (10%)	1 (5.88%)	1.00
Persistent abdominal pain after stent removal	2 (6.67%)	1 (5.88%)	1.000
Cholangitis after stent removal	0 (0%)	1 (5.88%)	<sup>a</sup>
Pancreatitis after stent removal	1 (3.33%)	0 (0%)	<sup>a</sup>
Recurrence of stone after stent removal	0 (0%)	1 (5.88%)	<sup>a</sup>

Abbreviations: CBD, common bile duct; ERCP, endoscopic retrograde cholangiopancreatography.

<sup>a</sup>No statistical test was applied due to 0's in cells.

Note: No bleeding, no perforation for all the 47 patients.

All patients of group 1 were asymptomatic on follow-up at 4th week and one patient later at follow-up at 8th week had mild abdominal pain, which was relieved with oral analgesics.

There was one patient in the direct stent removal group who had a sonologically dilated CBD > 10 mm at the time of stent removal and later developed a recurrence of CBD stone and cholangitis for which we had intervened (► Tables 5–7).

**Table 3** Comparison of time of stent removal in weeks in both the groups

Time of stent removal (wk)	Method of stent removal	
	Balloon sweep group	Direct stent removal group
4	24 (80%)	13 (76.47%)
6	0 (0%)	2 (11.76%)
8	4 (13.33%)	1 (5.88%)
12	1 (3.33%)	1 (5.88%)
24	1 (3.33%)	0 (0%)

**Table 4** Time taken for the procedure in both the groups

Procedure done	Mean	Number of patients	Standard deviation	p-Value
Direct stent removal by forward-viewing gastroscope	11.941	17	1.7128	
ERCP with balloon sweeps	29.300	30	5.4021	<0.001
Total	23.021	47	9.5131	

Abbreviation: ERCP, endoscopic retrograde cholangiopancreatography.

## Discussion

Prior to the present study, ERCP with balloon sweeps was the norm in our institution, as there are no previous studies or guidelines in the literature regarding the method of stent removal after postcholecystectomy in the case of choledocholithiasis. This study tries to generate some evidence on this topic. In our study, the majority of patients (90%) who

presented with choledocholithiasis had abdominal pain as the presenting symptom. A study done by Sarli et al also showed that asymptomatic CBD stones were in 36% of patients and symptomatic in 64% of patients.<sup>6</sup> Natural history of asymptomatic CBD stones is difficult to predict.<sup>7</sup> The majority of the patients in our study were in their 4<sup>th</sup> and 5<sup>th</sup> decades. Studies by Gupta and Selva et al also showed similar trends.<sup>8,9</sup> Ponugoti et al noticed a female

**Table 5** Comparison of common bile duct size at the time of stent removal between balloon sweep and direct stent removal

CBD	Balloon sweep	
	Balloon sweeps with cholangiogram by side-viewing duodenoscope	Direct stent removal by forward-viewing gastroscope
Dilated	0 (0%)	1 (5.88%)
Not dilated	30 (100%)	16 (94.12%)

**Table 6** Comparison of symptoms at 4th week between balloon sweep and direct stent removal (N = 47)

Symptoms	Balloon sweep	
	Yes (N = 30)	No (N = 17)
Asymptomatic	30 (100%)	16 (94.12%)
Fever	0 (0%)	1 (5.88%)

**Table 7** Comparison of symptoms at 8th week between balloon sweep and direct stent removal (N = 47)

Symptoms at 8th week	Balloon sweep	
	Yes (N = 30)	No (N = 17)
Asymptomatic	29 (96.67%)	16 (94.12%)
Pain abdomen	1 (3.33%)	0 (0%)
Reintervened	0 (0%)	1 (5.88%)

preponderance in patients with choledocholithiasis, similar to our study.<sup>10</sup>

The reported rate of complications post-ERCP varies from 6 to 7% in different studies.<sup>11</sup> In our study, after the index ERCP, complications were seen in 8% of the patients. The majority of patients underwent laparoscopic cholecystectomy rather than open cholecystectomy within 2 weeks. Laparoscopic cholecystectomy in the presence of CBD stents poses a significant risk when the stent is kept in situ for a long time.<sup>12</sup> The mean time frame between cholecystectomy and stent removal in our study was 5.2 weeks. This was similar to the time frame seen in other studies. A delay in stent removal can lead to a recurrence of stone and stent blockage.<sup>10</sup>

A study by Freeman et al showed pancreatitis in 5 to 6% of the patients.<sup>13</sup> Tsujino et al study showed that injecting contrast into the biliary tree can result in post-ERCP pancreatitis after balloon dilatation.<sup>14</sup> The incidence of poststent removal pancreatitis in our study was 3.3%, which was observed in the balloon sweep group.

The risk factors for recurrent bile duct stones after Endoscopic sphincterotomy (EST) were previously suggested to be a dilated CBD, Gall bladder (GB) stone, periampullary diverticulum, biliary stricture, angulation of the CBD, previous open cholecystectomy, and lithotripsy.<sup>15-19</sup> Patients in the direct stent removal group who had a recurrence of stone had a dilated CBD greater than 1 cm on sonographic evaluation of the biliary system before stent removal, suggesting caution in such patients (dilated CBD > 1 cm) for direct removal. A study done by Hawes et al estimated the recurrence of postcholecystectomy CBD stone after CBD clearance to be around 4%.<sup>20</sup> In our study, CBD stone recurrence after stent removal was 2% (1 out of 47 patients). A clear sweep was obtained in the majority of the balloon sweep group, with 2 patients having sludge out of 30 patients.

The duration of the procedure was significantly reduced in the direct stent removal group compared with the balloon sweep group; moreover, all patients in the balloon sweep group were exposed to sedation with midazolam in comparison to those in the direct stent removal group who were unsedated.

The average cost of ERCP with balloon sweep (418 U.S. dollars) and stent removal is much higher than gastroscopic stent removal (176 U.S. dollars).<sup>21</sup> This will help to cut down on the cost to the patient and the health care system if the patient undergoes direct stent removal. We need a larger number of randomized controlled trials that can guide us with data supporting direct gastroscopic stent removal with the use of ultrasounds and liver functional tests (LFT) as guiding parameters.

## Limitations of the Study

This is a single-center observational study.

## Conclusion

Patients who underwent CBD stenting for choledocholithiasis after cholecystectomy can safely undergo stent removal

using a gastroscope rather than subjecting again to ERCP, based on their LFTs and abdominal USG. This will significantly reduce the duration, unplanned adverse events, and the cost associated with the ERCP procedure.

### Author Contributions

Conceptualization: D.S., M.I., S.L.; formal analysis: D.S., S.L., C.T., V.R., M.S.; project administration: D.S.; writing—original draft: D.S., S.L., C.T., V.B.; writing—review and editing: D.S., K.B., M.S., S.C., Y.L.

### Ethics Committee Approval

The study was approved by the Institutional Ethics Committee Board at Lokmanya Tilak Municipal Medical College, Sion Hospital, Mumbai, India.

### Funding

None declared.

### Conflict of Interest

None declared.

## References

- De Silva WSL, Pathirana AA, Wijerathne TK, Gamage BD, Dassanayake BK, De Silva MM. Epidemiology and disease characteristics of symptomatic choledocholithiasis in Sri Lanka. *Ann Hepatobiliary Pancreat Surg* 2019;23(01):41–45
- Alponat A, Kum CK, Rajnakova A, Koh BC, Goh PM. Predictive factors for synchronous common bile duct stones in patients with cholelithiasis. *Surg Endosc* 1997;11(09):928–932
- Deng F, Zhou M, Liu PP, et al. Causes associated with recurrent choledocholithiasis following therapeutic endoscopic retrograde cholangiopancreatography: a large sample sized retrospective study. *World J Clin Cases* 2019;7(09):1028–1037
- Horiuchi A, Nakayama Y, Kajiyama M, et al. Biliary stenting in the management of large or multiple common bile duct stones. *Gastrointest Endosc* 2010;71(07):1200–1203.e2
- SPSS Inc. IBM SPSS Statistics Version 22 Statistical Software: Core System Users' Guide. SPSS Inc. 2014.
- Sarli L, Pietra N, Franzé A, et al. Routine intravenous cholangiography, selective ERCP, and endoscopic treatment of bile duct stones before laparoscopic cholecystectomy. *Gastrointest Endosc* 1999;50(02):200–208
- Shah KN, Clary BM. Chapter 36A - Stones in the bile duct: clinical features and open surgical approaches and techniques. In: Blumgart's Surgery of the Liver, Biliary Tract and Pancreas, 6<sup>th</sup> ed, Vol. 1–2; 2017.
- Gupta AM, Ramteke S, Kanwar KS, et al. Study of morphological spectrum of gallstone and bacteriology of bile in cholelithiasis. *Int Surg J* 2017;4:177–180
- Selvi TR, Sinha P, Subramaniam PM, et al. A clinicopathological study of cholecystitis with special reference to analysis of cholelithiasis. *Iran J Basic Med Sci* 2011;2:68–72
- Ponugoti S, Juluri R, Sundaram U. Is a follow-up endoscopic retrograde cholangiopancreatography procedure necessary for removal of biliary stents?: 1920 *Am J Gastroenterol* 2013;108: S582
- Andriulli A, Loperfido S, Napolitano G, et al. Incidence rates of post-ERCP complications: a systematic survey of prospective studies. *Am J Gastroenterol* 2007;102(08):1781–1788
- Nair MS, Uzzaman MM, Fafemi O, Athow A. Elective laparoscopic cholecystectomy in the presence of common bile duct stent. *Surg Endosc* 2011;25(02):429–436

- 13 Freeman ML, Nelson DB, Sherman S, et al. Complications of endoscopic biliary sphincterotomy. *N Engl J Med* 1996;335(13): 909–918
- 14 Tsujino T, Isayama H, Komatsu Y, et al. Risk factors for pancreatitis in patients with common bile duct stones managed by endoscopic papillary balloon dilation. *Am J Gastroenterol* 2005;100(01): 38–42
- 15 Ando T, Tsuyuguchi T, Okugawa T, et al. Risk factors for recurrent bile duct stones after endoscopic papillotomy. *Gut* 2003;52(01): 116–121
- 16 Kim DI, Kim MH, Lee SK, et al. Risk factors for recurrence of primary bile duct stones after endoscopic biliary sphincterotomy. *Gastrointest Endosc* 2001;54(01):42–48
- 17 Keizman D, Shalom MI, Konikoff FM. An angulated common bile duct predisposes to recurrent symptomatic bile duct stones after endoscopic stone extraction. *Surg Endosc* 2006;20(10): 1594–1599
- 18 Cheon YK, Lehman GA. Identification of risk factors for stone recurrence after endoscopic treatment of bile duct stones. *Eur J Gastroenterol Hepatol* 2006;18(05):461–464
- 19 Keizman D, Ish Shalom M, Konikoff FM. Recurrent symptomatic common bile duct stones after endoscopic stone extraction in elderly patients. *Gastrointest Endosc* 2006;64(01):60–65
- 20 Hawes RH, Cotton PB, Vallon AG. Follow-up 6 to 11 years after duodenoscopic sphincterotomy for stones in patients with prior cholecystectomy. *Gastroenterology* 1990;98(04):1008–1012
- 21 Coelho-Prabhu N, et al. Is repeat ERCP required at the time of biliary stent removal after clinical resolution of an endoscopically managed post- cholecystectomy bile leak? *Gastrointest Endosc* 2009;69(05):AB151