



# Hemorrhagic Fourth Ventricle Colloid Cyst: A Report of an Unusual Presentation at an Uncommon Location

Ankit S. Shah<sup>1</sup> Madhur S. Shroff<sup>1</sup>

<sup>1</sup> Department of Neurosurgery, SSG Hospital, Vadodara, Gujarat, India

**Address for correspondence** Ankit S. Shah, M.Ch., Department of Neurosurgery, SSG Hospital, Vadodara, Gujarat, India (e-mail: aksshah88@gmail.com).

Indian J Neurosurg

## Abstract

Colloid cysts are benign cystic lesions characteristically arising from the third ventricle roof close to the foramen of Monro. Although incredibly rare, hemorrhage within a third ventricular colloid cyst is sparsely reported. To the best of our knowledge, no cases of hemorrhage within the fourth ventricle colloid have ever been documented. Here, we present an interesting case describing a hemorrhagic colloid cyst situated within the fourth ventricle of a 55-year-old female patient who presented with symptoms of headache, vomiting, and gait imbalance. The cyst was excised during surgery via a suboccipital microscopic telovelar approach. Our findings led us to the conclusion that, despite being extremely rare, colloid cysts in the fourth ventricle can present with hemorrhagic episodes, which can exacerbate symptoms and hasten neurological decline. As a result, the presence of unusual radiological characteristics in a fourth ventricle lesion should prompt medical practitioners to suspect an atypical colloid cyst. This consideration can be pivotal in making informed surgical decisions. Expedited management and a microsurgical approach are recommended strategies for a better outcome.

## Keywords

- ▶ colloid cyst
- ▶ fourth ventricle
- ▶ hemorrhage

## Introduction

Colloid cysts comprise around 0.5 to 1% of all primary brain tumors.<sup>1,2</sup> These rare benign cystic tumors are endodermal embryological remnants, frequently situated on the roof of the third ventricle. Their occurrence within the fourth ventricle is unusual.<sup>3</sup> The clinical manifestations vary, ranging from incidental detection of cysts to instances of sudden fatality due to rapid-onset hydrocephalus.<sup>1,4</sup>

Typically measuring 0.3 to 4 cm in size, these cysts possess a distinct cyst wall, display well-defined boundaries, and expand due to amorphous and protein-rich fluid secretions.<sup>2</sup> On computed tomography (CT) scans, they appear homogeneously hyperdense, while on magnetic resonance imaging (MRI), they exhibit high T1 signal intensity and low

T2 signal intensity.<sup>5</sup> Instances of acute hemorrhage occurring within colloid cysts are exceedingly uncommon and can manifest with sudden, severe symptoms or even lead to abrupt demise.<sup>6,7</sup> In this article, we present a remarkable case of a patient harboring an unconventional colloid cyst within the fourth ventricle and presenting with acute worsening of symptoms. This patient exhibited intracystic hemorrhage, prompting the consideration of alternative diagnoses. To our knowledge, intracystic hemorrhage in colloid cyst of the fourth ventricle has never been documented.

## Case Report

A 55-year-old woman presented with intermittent headaches and occasional vertigo over the past 2 months. Since last week,

DOI <https://doi.org/10.1055/s-0044-1788699>.  
ISSN 2277-954X.

© 2024. The Author(s).

This is an open access article published by Thieme under the terms of the Creative Commons Attribution License, permitting unrestricted use, distribution, and reproduction so long as the original work is properly cited. (<https://creativecommons.org/licenses/by/4.0/>)

Thieme Medical and Scientific Publishers Pvt. Ltd., A-12, 2nd Floor, Sector 2, Noida-201301 UP, India

she had persistent headaches of throbbing variety, accompanied by vomiting and gait imbalance. During the physical examination, no focal neurological deficits were noted. CT of the brain spotted a hyperdense mass in the fourth ventricle with mild upstream dilatation of ventricles. The contents showed attenuation values of 80 to 95 HU. MRI of the brain demonstrated a distinct, well-defined mass in the posterior part of the fourth ventricle that measured approximately  $3.3 \times 2.4 \times 2.5$  cm in all dimensions. The lesion appeared hypointense on T2 and fluid attenuated inversion recovery (FLAIR) images, displayed intermediate characteristics on T1 images, and exhibited blooming on susceptibility-weighted images. A small, irregularly enhancing mural nodule was evident on the left posterior side on contrast-enhanced images (►Fig. 1). The MRI findings suggested the possibility of a lesion with hemorrhagic or calcific attributes and raised suspicion of it being a hemangioblastoma, ependymoma, or metastatic lesion.

The patient underwent suboccipital craniotomy and the telovelar approach, which revealed a grayish-white spherical smooth cystic mass with a thin capsule. The cyst was found within the fourth ventricle and could be separated from its surroundings through a clear plane of cleavage, except for its attachment to the vermis. The cyst contained a thick, sticky, gelatinous, brownish content with noticeable vascularity (►Fig. 2A, B). The cyst was excised completely except for its posterosuperior attachment to the vermis. On

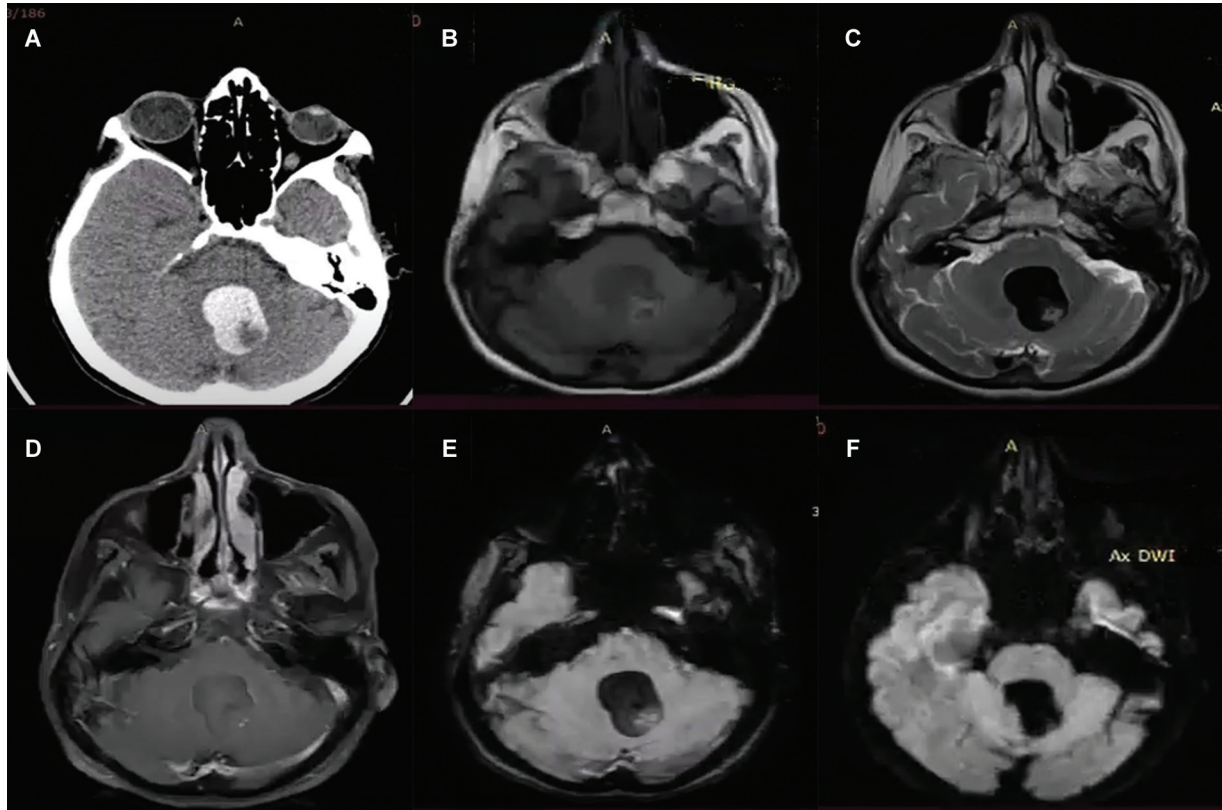
follow-up at 1 month, the patient is doing well with resolution of headaches and vertigo.

Upon histopathological analysis, the cyst wall was observed to be lined variably with two to three layers of cuboidal to multilayered squamous lining cells, accompanied by regions of hypocellular collagenous tissue. The cyst content consisted of a homogenous, colloidlike material. Notably, the existence of red blood cells, macrophages laden with hemosiderin, chronic inflammatory cells, and cholesterol crystals indicated hemorrhage within the colloid cyst.

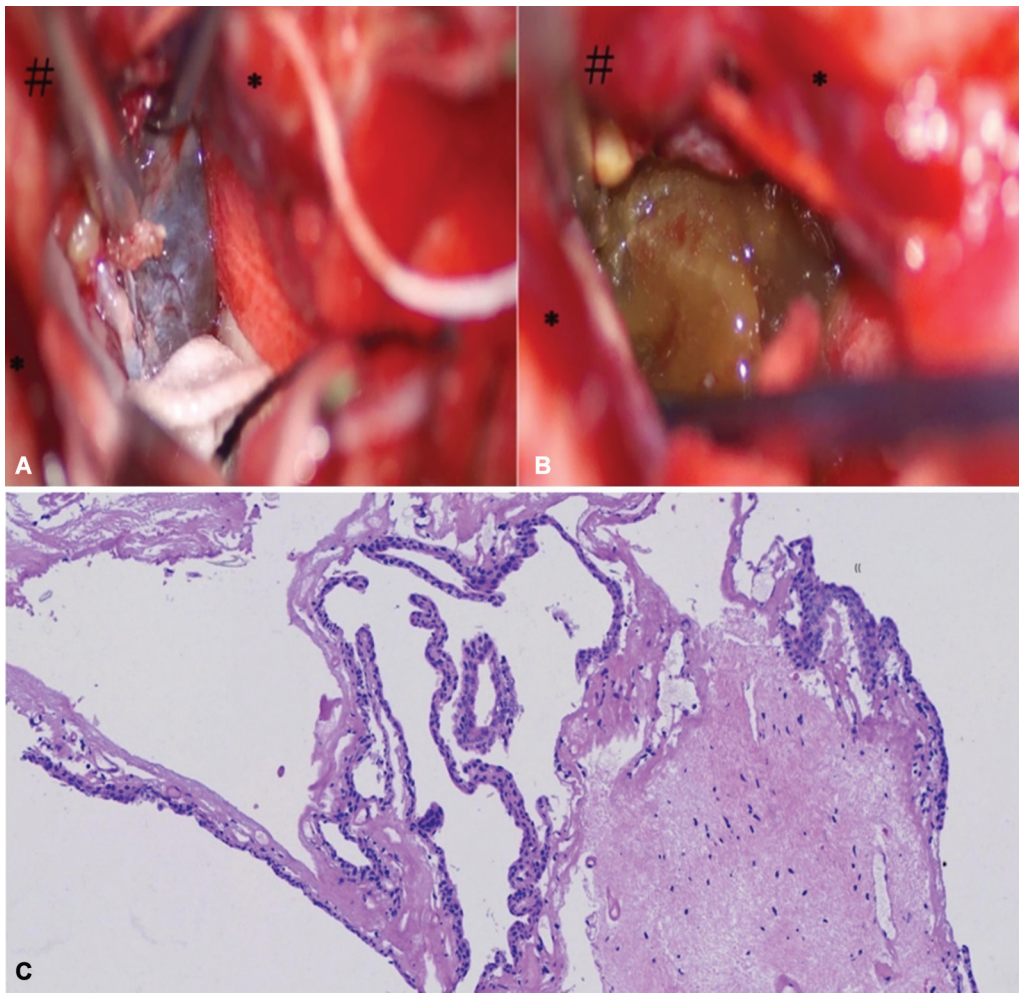
## Discussion

Colloid cysts are characterized by their benign nature and thin walls, with a preferential location along the midline of the third ventricle, in proximity to the foramen of Monro. These cysts are filled with colloid material.<sup>8,9</sup> They originate from the residual endodermal embryonic structures within the brain. Other potential sites include diencephalic ependymoma, the invagination of the neuroepithelium within the ventricle, or the respiratory epithelium of endodermal origin.<sup>5,10,11</sup> These cysts account for about 15 to 20% of intraventricular masses and 0.5 to 1.0% of all primary brain tumors.<sup>4,10,11</sup>

The utilization of CT and MRI has led to an increased identification of asymptomatic colloid cysts.<sup>10</sup> Common symptoms, often linked to heightened intracranial pressure in the third ventricular cysts, include headaches, memory



**Fig. 1** Preoperative images. (A) Axial view of the computed tomography (CT) of the brain showing hyperdense lesion in the region of the fourth ventricle. Axial views of the magnetic resonance imaging (MRI) of the brain showing lesion in the fourth ventricle displaying (B) heterogeneous intensity on T1 and (C) hypointense on T2. (D) The lesion does not take contrast on T1 + C images. There is blooming on (E) susceptibility-weighted imaging (SWI) without any diffusion restriction on (F) diffusion-weighted imaging (DWI).



**Fig. 2** (A, B) Intraoperative images showing the telovelar approach with tonsils (\*) and vermis (#) in view. A thin-walled cyst containing hemorrhage-stained gelatinous content is also visible. (C) Histopathology showing the cyst wall lined by a cuboidal epithelium with a subepithelial xanthogranulomatous reaction.

impairments, and cognitive impairments.<sup>5,8,10</sup> Additional modes of presentation encompass dementia, disruptions in gait, and urinary incontinence due to chronic hydrocephalus. Colloid cysts can give rise to significant morbidity and, in some cases, even mortality. The potential causes include acute obstructive hydrocephalus and, in rare instances, intracystic hemorrhage referred to as “cyst apoplexy.”<sup>8,9,12</sup> The occurrence of hemorrhagic changes within colloid cysts can cause rapid enlargement, ultimately leading to a sudden and total obstruction of cerebrospinal fluid (CSF) circulation.<sup>6,13</sup>

There have been a handful of events of hemorrhagic third ventricle cysts described in the literature. However, a hemorrhagic colloid cyst, especially one within the fourth ventricle, has never been reported. A slow-growing cyst does not manifest clinically, as the intracranial pressures are maintained within normal ranges for longer periods of time despite progressive enlargement of the ventricles. On the contrary, rapid expansion of the cyst in cases of cyst apoplexy may lead to elevated intracranial pressure, resulting in clinical symptoms.<sup>12</sup> This occurs as a result of failure of the CSF dynamics to adjust to sudden changes in cystic volume.<sup>4</sup> The symptoms of headache and vertigo in our

patient can be attributed to a mass lying within the fourth ventricle. Intracystic hemorrhage is assumed to be a potential cause of rapid lesion expansion and the sudden worsening of symptoms in our case; however, there is no way to establish it, and the precise reason remains unknown.

On CT scan, colloid cysts usually present as hyperdense, rarely as isodense, and exceptionally rarely as hypodense. This density variation is contingent upon the cholesterol content within the cyst.<sup>6,14</sup> On MRI, hyperintensity on T1-weighted images is typical and reflects cholesterol levels, while the degree of protein fluid determines signal intensity on T2-weighted images, which generally appears isointense to hypointense. Importantly, these cysts usually do not suppress on FLAIR studies and demonstrate absence of diffusion restriction on diffusion-weighted imaging.<sup>5,6,14</sup> In our case, the signal intensity on T1 and T2 aligns with the literature. However, notable heterogeneity in signal intensity on T2-weighted images, accompanied by blooming artifacts on susceptibility-weighted imaging (SWI), corresponds to the confirmed cystic hemorrhage.

The underlying cause of intracystic bleeding remains elusive. While hypertension and coagulation disorders have been proposed as potential factors, concrete proof is



lacking in most cases.<sup>2,9,11,12</sup> However, in the majority of cases, including ours, the cause of the hemorrhage remains unclear due to a lack of any significant medical history.

Management strategies for colloid cysts vary. Many reports have shown that rapidly addressing hydrocephalus through emergency external ventricular drainage followed by elective cyst removal yields satisfactory outcomes.<sup>5,7,10</sup> Stable patients can undergo direct cyst excision without the need for emergency ventricular drainage,<sup>11</sup> as was the case in our situation.

Surgical procedures for symptomatic colloid cysts usually involve open microsurgical or endoscopic techniques for excision.<sup>11</sup> For the common third ventricular colloid cyst, the preferred method is the interhemispheric transcalsal approach. An alternative is the endoscopic approach, which has been considered advantageous over the microscopic method due to its exceptional vision and minimally invasive entry through the enlarged ventricles.<sup>10</sup> Also, rates of gross total resection are higher, and recurrence and reoperation are lower in the endoscopic approach as compared to the microscopic approach, as reported by Sheikh et al in their analysis of outcomes in 1,278 patients.<sup>15</sup> Stereotactic aspiration is also a minimally invasive option in third ventricular colloid cysts with thin contents; however, it has fallen out of favor due to chances of recurrence.<sup>10</sup>

A hemorrhagic colloid cyst may alter the recommended course of therapy, depending on its size and location.<sup>9,10</sup> Surgery for cystic lesions of the fourth ventricle often consists of suboccipital craniotomy for direct cyst excision, endoscopic fenestration, or ventricle shunting. Endoscopic removal of cysts in the fourth ventricle has also been reported. On the other hand, the endoscopic method appears to be more difficult and needs special expertise, especially when the cyst is attached to the ependymal lining or when there is a thin aqueduct.<sup>16</sup> In contrast to colloid cysts in the third ventricle, the location of the cyst in our case obviated the use of endoscopy or stereotactic aspiration. Our recommended treatment plan was suboccipital craniotomy and the telovelar approach with microsurgical excision due to the cyst's size and hemorrhagic nature, as well as additional differentials to be addressed. We favor the use of microscopic surgery in cases of a hemorrhagic cyst due to the potential challenges of aspirating thick clots and gelatinous material. During microsurgery, the sticky gelatinous content and dense clot necessitate a sequential, gradual piecemeal decompression and capsular dissection approach similar to that used for fourth ventricle tumors, evading any harm to the crucial neighboring structures.

## Conclusion

A hemorrhagic fourth ventricle colloid cyst is a rare entity and has never been described in the literature. Preoperative

radiological diagnosis can be challenging due to wide variations in CT and MRI scans, and a colloid cyst should be considered a differential in hyperdense lesions of fourth ventricle masses to avoid any intraoperative surprises. Intracystic hemorrhage should be considered a plausible explanation for acute deterioration of a patient with a colloid cyst. Expedited management and a microsurgical approach are recommended in the treatment of hemorrhagic colloid cysts.

## Conflict of Interest

None declared.

## References

- 1 Beems T, Menovsky T, Lammens M. Hemorrhagic colloid cyst: case report and review of the literature. *Surg Neurol* 2006;65(01):84–86
- 2 Tamura Y, Uesugi T, Tucker A, et al. Hemorrhagic colloid cyst with intraventricular extension. *J Neurosurg* 2013;118(03):498–501
- 3 Jan M, Ba Zeze V, Velut S. Colloid cyst of the fourth ventricle: diagnostic problems and pathogenic considerations. *Neurosurgery* 1989;24(06):939–942
- 4 Carrasco R, Pascual JM, Medina-López D, Burdaspal-Moratilla A. Acute hemorrhage in a colloid cyst of the third ventricle: a rare cause of sudden deterioration. *Surg Neurol Int* 2012;3(01):24
- 5 Al-Saiari SA, Abdoh MG, Farag AA, et al. Atypical haemorrhagic colloid cyst: 2 case reports surgical management and review of literature. *Int J Surg Case Rep* 2020;76:435–440
- 6 Akhavan R, Zandi B, Pezeshki-Rad M, Farrokh D, Abbasi B. Hemorrhagic colloid cyst presenting with acute hydrocephaly. *Case Rep Neurol Med* 2017;2017:2978080
- 7 Farooq MU, Bhatt A, Chang HT. Hemorrhagic colloid cyst in a 9-year-old girl. *Pediatr Neurol* 2008;38(06):443–444
- 8 Beaumont TL, Limbrick DD Jr, Rich KM, Wippold FJ II, Dacey RG Jr. Natural history of colloid cysts of the third ventricle. *J Neurosurg* 2016;125(06):1420–1430
- 9 Al Abdulsalam HK, Ajlan AM. Hemorrhagic colloid cyst. *Neurosciences (Riyadh)* 2018;23(04):326–333
- 10 Diyora B, Nayak N, Kukreja S, Sharma A. Hemorrhagic colloid cyst: case report and review of the literature. *Asian J Neurosurg* 2013;8(03):162–162
- 11 Menon G, Kongwad LI, Nair RP, Kumar V. Hemorrhagic colloid cyst. *Neurol India* 2017;65(05):1164–1167
- 12 Ogbodo E, Kaliaperumal C, Bermingham N, O'Sullivan M. Spontaneous haemorrhage and rupture of third ventricular colloid cyst. *BMJ Case Rep* 2012;2012:bcr2012006863
- 13 Coce N, Pavliša G, Nanković S, Jakovčević A, Šeronja-Kuhar M, Pavliša G. Large hemorrhagic colloid cyst in a 35-year-old male. *Turk Neurosurg* 2012;22(06):783–784
- 14 Algin O, Ozmen E, Arslan H. Radiologic manifestations of colloid cysts: a pictorial essay. *Can Assoc Radiol J* 2013;64(01):56–60
- 15 Sheikh AB, Mendelson ZS, Liu JK. Endoscopic versus microsurgical resection of colloid cysts: a systematic review and meta-analysis of 1,278 patients. *World Neurosurg* 2014;82(06):1187–1197
- 16 Simão D, Teixeira JC, Campos AR, Coiteiro D, Santos MM. Fourth ventricle neurocysticercosis: a case report. *Surg Neurol Int* 2018;9:201