



Application of Using Gore Preclude MVP Dura Substitute for Intraoperative Durotomy Repair in Lumbar Spine Surgery: Case Series and A Technical Note

Yoshinori Maki¹ Toshinari Kawasaki² Kota Nakajima² Mitsushige Ando³ Tamaki Kobayashi²
Yoshihiko Irooi² Motohiro Takayama²

¹ Department of Neurosurgery, Hikone Chuo Hospital, Hikone City, Shiga, Japan

² Department of Neurosurgery, Otsu City Hospital, Otsu, Shiga, Japan

³ Department of Neurosurgery, Shiga General Hospital, Moriyama City, Shiga, Japan

Address for correspondence Yoshinori Maki, MD, Department of Neurosurgery, Hikone Chuo Hospital, 421 Nishiima-cho Hikone, Shiga 522-0054, Japan (e-mail: passatempo19840816@gmail.com).

Asian J Neurosurg

Abstract

Keywords

- spine surgery
- intraoperative durotomy
- cerebrospinal fluid leakage
- gore preclude MVP dura substitute
- repair

Durotomy is an intraoperative complication in lumbar surgery, which can result in refractory cerebrospinal leakage. Therefore, intraoperative durotomy in lumbar surgery should be appropriately repaired. The aim of the study was to describe our method to repair intraoperative durotomy using the Gore Preclude MVP Dura Substitute (MVP). The MVP is an artificial dural substitute of three layers. Its surfaces are composed of expanded polytetrafluoroethylene, and the intermittent layer is made of a proprietary fluoroelastomer. After an incidental durotomy during surgery, the MVP was cut and designed bigger than the size of the durotomy site. The MVP was inserted into the space between the dura and the arachnoid membrane. The MVP was unfolded in the inserted space and fixed to the dura using four nodes of 6-0 nylon yarn. Intraoperative dural repair was achieved, and cerebrospinal fluid leakage did not persist. No complications were observed. Our method to repair intraoperative durotomy using the MVP can be simple and useful.

Introduction

Intraoperative durotomy or incidental durotomy (ID) can occur unintentionally during spine surgery. ID can occur from the cervical levels to the lumbar region along the spinal cord, but ID in the lumbar region is relatively common.¹ The incidence of ID can vary from 3 to 27% during lumbar spinal surgery.² Moreover, ID can occur more frequently in the revision/secondary operation than in the primary operation.³ ID that is inappropriately

managed can result in secondary complications such as cerebrospinal fluid (CSF) leakage, CSF cutaneous fistula, headache, pseudomeningocele, arachnoiditis, meningitis, epidural abscess, and neurological deterioration.^{1,4} Moreover, a persistent CSF leakage due to ID can also lead to a chronic pain disorder, cranial nerve palsy, and radiculopathy.^{1,4} To prevent these ID-related secondary complications, ID should be appropriately managed before wound closure.

DOI <https://doi.org/10.1055/s-0044-1788634>.
ISSN 2248-9614.

© 2024. Asian Congress of Neurological Surgeons. All rights reserved.

This is an open access article published by Thieme under the terms of the Creative Commons Attribution-NonDerivative-NonCommercial-License, permitting copying and reproduction so long as the original work is given appropriate credit. Contents may not be used for commercial purposes, or adapted, remixed, transformed or built upon. (<https://creativecommons.org/licenses/by-nc-nd/4.0/>)

Thieme Medical and Scientific Publishers Pvt. Ltd., A-12, 2nd Floor, Sector 2, Noida-201301 UP, India

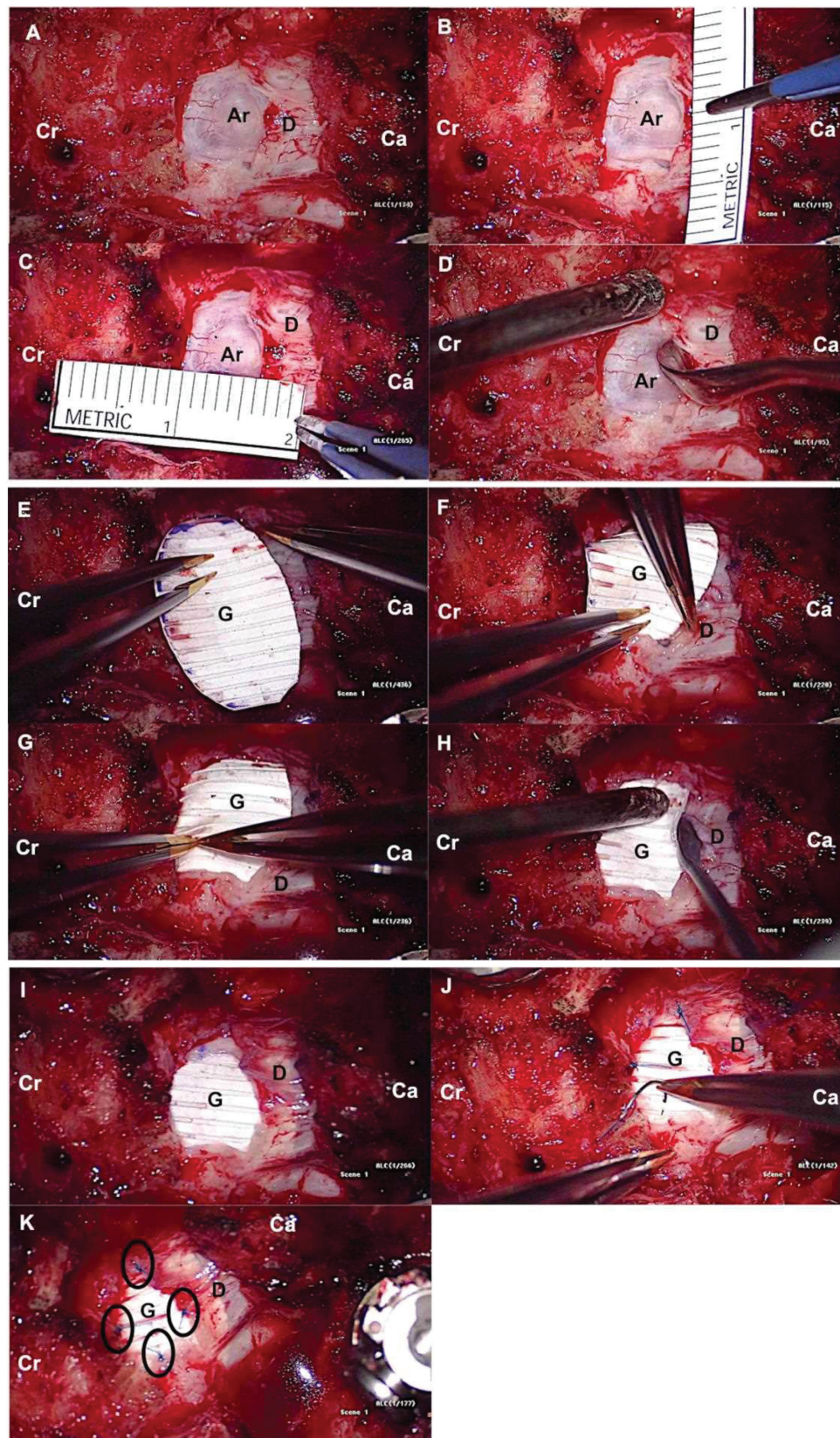


Fig. 1 Intraoperative procedure of dural repair. (A) A durotomy occurred during granulation tissue excision from the lamina and dura. Cerebrospinal fluid leakage was observed. (B, C) The size of the dura was measured. In this case, the dimension of the durotomy site was 5×7 mm. (D) The dura was circumferentially detached from the arachnoid membrane. (E) The dimension of the MVP was approximately 10×14 mm. (F–I) The MVP was inserted into the space between the dura and arachnoid membrane. (J, K) The MVP was sutured to the dura using 6–0 nylon yarn. The nodes were made by penetrating the convex surface of the MVP. Ar, arachnoid membrane; Ca, caudal; Cr, cranial; D, dura; G, MVP (Gore Preclude MVP Dura Substitute).

Several methods concerning the intraoperative repair of ID have been proposed. In the cases where direct suture of the ID site is possible, a 6–0 or 7–0 needle is applied. The needle hole should be covered with a fibrin glue sealant.⁵ Nonpenetrating clips can also seal the puncture directly. In the cases where the puncture is large enough, a muscle pouch, fascia pouch, and artificial dura sheet can be used. Durotomy repair using a polyglactin acid sheet covered with fibril glue seems to be an effective method.^{5,6} Effective intraoperative repair of the durotomy using DuraGen has also been described.³ However, to the best of our knowledge, reports on the intraoperative repair of ID using Gore Preclude MVP Dura Substitute (W. L. Gore & Associates, Inc. Japan; henceforth referred to as “MVP”) seem to be scant. In this study, we present our method to repair intraoperative durotomy during spine surgery using the MVP.

Materials and Methods

A Representative Case

During the removal of granulation tissue on the dura, an ID occurred during additional posterior lumbar intervertebral fixation surgery. The subsequent CSF leakage led us to conclude that repair of the ID was necessary. We measured the dimensions of the ID site. The MVP was designed to be twice the size of the ID site. The dura around the ID site was circumferentially detached from the arachnoid membrane. Following this, the MVP was inserted into the space between the dura and the arachnoid membrane. Care was taken not to damage the arachnoid membrane. Subsequently, the MVP was stitched to the dura using a 6–0 nylon yarn by penetrating the convex surface of the MVP. This procedure was performed under an operative microscope. CSF leakage was not associated with the Valsalva maneuver (► Fig. 1).

ID repair using MVP was performed in five patients by three neurosurgeons. The method was applied to a patient with refractory CSF leakage and four patients in the same operation where an ID occurred. Bolheal (fibrin sealant), Neoveil sheet, fascia patch, and DuraGen were also applied if required (► Table 1).

Results

The intraoperative dural repair was achieved, and CSF leakage did not persist. Postoperative complications related to ID did not occur.

Discussion

We described a simple and effective method to repair ID using the MVP. This method successfully managed the incidental occurrence of durotomy and prevented secondary complications associated with ID in lumbar surgery.

The MVP is an artificial dura mater like Gore-Tex. Gore-Tex is composed of an expanded polytetrafluoroethylene (EPTFE) sheet.⁷ After the utility of the EPTFE sheet to prevent postoperative fibrous ingrowth was confirmed by

Table 1 Five patients with intraoperative durotomy treated using Gore Preclude MVP Dura Substitute

Patients	Sex, age (y)	Preceded operation	Operation related to intraoperative durotomy	Preceded procedures to repair intraoperative durotomy	Additional procedures to repair durotomy
Patient 1	Male, 55	L2/L3 PLIF	L3/L4 PLIF Removal of L2 screws	1 Neoveil and Bolheal 2 fascia patch (6–0 Prolene), Surgicel, Bolheal, and DuraGen	Bolheal, DuraGen, fascia and fatty tissue patch, and Neoveil
Patient 2	Female, 54	None	L4/L5 PLIF	None	None
Patient 3	Male, 76	L4/L5, L5/S1 PLIF	L3/L4 MD + laminectomy	None	Fascia patch
Patient 4	Female, 77	None	L3/L4, L4/L5 laminectomy	None	Bolheal, DuraGen, and Neoveil
Patient 5 (representative case)	Female, 81	MD	L3–S1 PLIF	None	Bolheal and Neoveil

Abbreviations: MD, microdisectomy; PLIF, posterior lumbar intervertebral fixation.

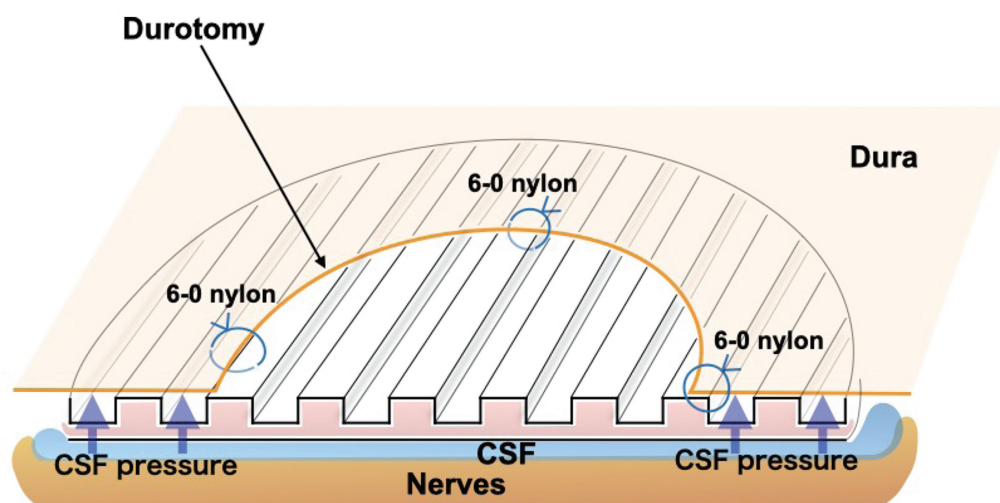


Fig. 2 Schema of our method to repair intraoperative using MVP. The MVP was designed bigger than the size of the durotomy. The MVP was anchored with 6-0 nylon to the dura. The CSF pressure aids better attachment of MVP to the inner surface of the dura. This condition seems favorable to prevent CSF leakage. CSF, cerebrospinal fluid; MVP, Gore Preclude MVP Dura Substitute.

experimental studies,^{8,9} Gore-Tex was applied to clinical use.^{10–12} However, Gore-Tex is associated with CSF leakage from needle holes on the surface can be a disadvantage. To minimize the CSF leakage, small needles such as 6-0 or 7-0 are applied to suture Gore-Tex to an ID site.³ Alternatively, ID repaired with nonpenetrating titanium clips is preferred.¹³ Similar to Gore-Tex, the surface of the MVP is also composed of EPTEE. Moreover, the three-layered MVP consists of a proprietary intermediate layer of fluoroelastomer between two EPTEE layers. The intermediate layer works as an impermeable watertight barrier owing to a self-sealing feature. Among the two outer layers, the surface attaching to the neural tissue is relatively smooth and not adhesive and, hence, ensures flexibility. The opposite surface is designed as an open pore structure that facilitates rapid ingrowth of fibroblasts.¹⁴

In our method, the MVP was inserted in the space between the dura and arachnoid membrane (→Fig. 2). For sufficient coverage of the ID site, the MVP was designed bigger than the size of the ID site in the representative case. Since fixing MVP with a multinodes of 6-0 nylon yarn is associated with CSF leakage from the holes, only four nodes were used for suturing the 6-0 nylon yarn anchoring the convex surface to the dura in our method.

Our method to repair ID using the MVP seems to have the following advantages: (1) minimization of CSF leakage from the node holes; (2) the open pore surface of the MVP firmly attaches to the inner surface of the dura, facilitating rapid ingrowth of fibroblasts; and (3) as the MVP is not tightly fixed to the dura, the flexibility of the MVP is maintained. Thus, the MVP can adapt to the dural position and expansion due to CSF pressure change associated with posture.

Since a long-term follow-up is lacking in this method, the patients undergoing our method to repair ID using the MVP are now monitored in an outpatient clinic.

Conclusion

Our simple method of dural repair using the Gore Preclude MVP Dura Substitute is effective. This method will be useful in improving the management of complications associated with ID.

Funding

None.

Conflict of Interest

None declared.

Acknowledgment

We would like to thank Editage (www.editage.com) for English-language editing.

References

- 1 Moussa WMM, Aboul-Enein HA. Combined thrombin and autologous blood for repair of lumbar durotomy. *Neurosurg Rev* 2016; 39(04):591–597
- 2 Epstein NE. Incidence and management of cerebrospinal fluid fistulas in 336 multilevel laminectomies with noninstrumented fusions. *Surg Neurol Int* 2015;6(suppl 19):S463–S468
- 3 Epstein NE. A review article on the diagnosis and treatment of cerebrospinal fluid fistulas and dural tears occurring during spinal surgery. *Surg Neurol Int* 2013;4(suppl 5):S301–S317
- 4 Jankowitz BT, Atteberry DS, Gerszten PC, et al. Effect of fibrin glue on the prevention of persistent cerebral spinal fluid leakage after incidental durotomy during lumbar spinal surgery. *Eur Spine J* 2009;18(08):1169–1174
- 5 Hara T, Takahashi R, Ohara Y, et al. Preventive effect of Duragen® on cerebrospinal fluid leakage in spinal surgery. *J Spine Res* 2021; 12:926–932
- 6 Sugawara T, Itoh Y, Hirano Y, et al. Novel dural closure technique using polyglactin acid sheet prevents cerebrospinal fluid leakage after spinal surgery. *Neurosurgery* 2005;57(04):290–294, discussion 290–294

- 7 Yamagata S, Goto K, Oda Y, Kikuchi H. Clinical experience with expanded polytetrafluoroethylene sheet used as an artificial dura mater. *Neurol Med Chir (Tokyo)* 1993;33(08):582–585
- 8 DiFazio FA, Nichols JB, Pope MH, Frymoyer JW. The use of expanded polytetrafluoroethylene as an interpositional membrane after lumbar laminectomy. *Spine* 1995;20(09):986–991
- 9 Lladó A, Sologaistua E, Guimerá J, Marín M. Expanded polytetrafluoroethylene membrane for the prevention of peridural fibrosis after spinal surgery: a clinical study. *Eur Spine J* 1999;8(02):144–150
- 10 Aliredjo RP, de Vries J, Menovsky T, Grotenhuis JA, Merx J. The use of Gore-Tex membrane for adhesion prevention in tethered spinal cord surgery: technical case reports. *Neurosurgery* 1999;44(03):674–677, discussion 677–678
- 11 Inoue HK, Kobayashi S, Ohbayashi K, Kohga H, Nakamura M. Treatment and prevention of tethered and retethered spinal cord using a Gore-Tex surgical membrane. *J Neurosurg* 1994;80(04):689–693
- 12 Mohsenipour I, Daniaux M, Aichner F, Twerdy K. Prevention of local scar formation after operative discectomy for lumbar disc herniation. *Acta Neurochir (Wien)* 1998;140(01):9–13
- 13 Ito K, Aoyama T, Horiuchi T, Hongo K. Utility of nonpenetrating titanium clips for dural closure during spinal surgery to prevent postoperative cerebrospinal fluid leakage. *J Neurosurg Spine* 2015;23(06):812–819
- 14 Chappell ET, Pare L, Salehpour M, Mathews M, Middlehof C. GORE PRECLUDE MVP dura substitute applied as a nonwatertight “underlay” graft for craniotomies: product and technique evaluation. *Surg Neurol* 2009;71(01):126–128, discussion 128–129