



Successful Rectification of Cervical Nerve Root Irritation with Sequential Surgical Maneuvers during Posterior Cervical Instrumentation

Balaji Vaithialingam¹ Ramachandran Govindasamy² Swaroop Gopal³ Satish Rudrappa³

¹Division of Neuroanaesthesiology, International Institute of Neurosciences, Aster Whitefield Hospital, Bengaluru, Karnataka, India

²Division of Spine and Deformity Surgery, International Institute of Neurosciences, Aster Whitefield Hospital, Bengaluru, Karnataka, India

³Department of Neurosurgery and Spine Surgery, International Institute of Neurosciences, Aster Whitefield Hospital, Bengaluru, Karnataka, India

Address for correspondence Balaji Vaithialingam, MD, DM, Division of Neuroanaesthesiology, International Institute of Neurosciences, Aster Whitefield Hospital, Bengaluru 560066, Karnataka, India (e-mail: balamedicine04@gmail.com).

Asian J Neurosurg

Abstract

Posterior cervical instrumentation is used to treat a variety of cervical pathologies, including cervical spondylotic myelopathy, severe canal stenosis, and degenerative diseases. A 55-year-old man with severe cervical canal stenosis underwent a C3–C6 laminectomy and lateral mass screw fixation under general anesthesia. After lateral mass screw fixation and rod placement on the right side, raw electromyography (EMG) revealed irritative discharges in the right biceps brachii muscle. Following a suspicion of irritation/mechanical stretching of the C5–C6 nerve root, a posterior foraminotomy was performed on the right side as a rescue measure. The amplitude of raw EMG irritative discharges in the right biceps brachii muscle decreased significantly after posterior foraminotomy. Following rod reapplication with decreased rod lordosis, the irritative EMG discharges were eliminated. Before implementing further measures, posterior foraminotomy can be a crucial initial intervention for minimizing nerve root irritation due to mechanical factors after cervical lateral mass screw fixation.

Keywords

- ▶ raw electromyography
- ▶ foraminotomy
- ▶ posterior cervical instrumentation
- ▶ lateral mass screw fixation

Introduction

The two most common instrumentation methods for posterior cervical fusion are fluoroscopy-guided pedicle screw placement and lateral mass screw fixation. Because of the technical difficulty and high screw misplacement rate, cervical pedicle screw placement has limited application.^{1,2} The use of a cervical lateral mass screw, on the other hand, is a

well-established technique due to its simplicity and low complication rate. During posterior cervical instrumentation, neurovascular structures such as the vertebral artery, nerve root, and spinal cord may be injured.³ We present a case of mechanical irritation of the right C5–C6 nerve root after cervical lateral mass screw fixation, which was identified and rectified with various sequential surgical maneuvers under continuous raw electromyographic (EMG) monitoring.

DOI <https://doi.org/10.1055/s-0044-1788632>
ISSN 2248-9614.

© 2024, Asian Congress of Neurological Surgeons. All rights reserved.

This is an open access article published by Thieme under the terms of the Creative Commons Attribution-NonDerivative-NonCommercial-License, permitting copying and reproduction so long as the original work is given appropriate credit. Contents may not be used for commercial purposes, or adapted, remixed, transformed or built upon. (<https://creativecommons.org/licenses/by-nc-nd/4.0/>)

Thieme Medical and Scientific Publishers Pvt. Ltd., A-12, 2nd Floor, Sector 2, Noida-201301 UP, India

Case Presentation

A 55-year-old man presented with walking difficulty for the past 6 months. A clinical examination revealed a motor power of 3/5 in all four limbs, as well as an upper limb sensory deficit. Preoperative magnetic resonance imaging revealed severe cervical canal stenosis with myelopathy at the C3–C6 level (►Fig. 1). The patient was scheduled for cervical lateral mass screw fixation under general anesthesia with transcranial motor evoked potential (MEP) and raw EMG monitoring. An awake oral fiberoptic tracheal intubation and awake prone positioning were performed due to cervical myelopathy. After confirming baseline neurological status in the prone position, 100 mg of intravenous propofol and 10 mg of intravenous cisatracurium were administered to induce anesthesia. The scalp corkscrew electrodes were paced at the C3–C4 anatomical locations using the 10–20 electroencephalographic placement system for MEP monitoring. Needle electrodes were placed in the bilateral deltoid, biceps brachii, flexor carpi radialis, and abductor pollicis brevis muscles to record the compound muscle action potential (CMAP) and spontaneous EMG activity. A propofol target-controlled infusion of 4 µg/mL and a single bolus of 10 mg intravenous morphine were used to maintain intraoperative anesthesia, without administration of muscle relaxants. After completion of cervical lateral mass screw fixation at the C3–C6 levels under fluoroscopy, cervical laminectomy was performed at the C3–C6 levels. Intermittent MEP recordings were taken to ensure cervical cord integrity during the process, and raw EMG was monitored for cervical nerve root irritative discharges with the Medtronic (Dublin, Ireland) intraoperative neuromonitoring system. The right rod was placed first and tightening of the rod was done with screw tulips. The raw EMG recorded constant

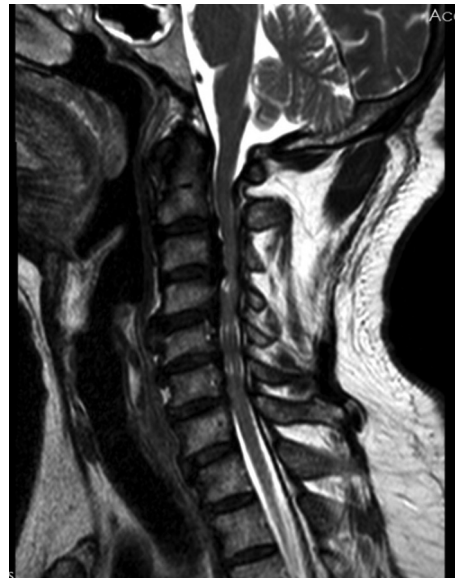

Fig. 1 Preoperative magnetic resonance imaging (T2 sagittal) showing severe cervical canal stenosis with myelopathy at the C3–C6 level.

irritative discharges in the right biceps brachii immediately after rod placement on the right side (►Fig. 2A), indicating mechanical irritation of the right C5–C6 nerve root. After notifying the surgeon, the surgical field was irrigated with warm saline, and the rod was taken out. Despite all measures, raw EMG irritative discharges in the right biceps brachii muscle persisted. A posterior foraminotomy was performed at the right C5 and C6 levels as a second measure, and the amplitude of the irritative discharge (right biceps brachii) in the raw EMG recording decreased immediately (►Fig. 2B). The irritative EMG discharge in the right biceps brachii

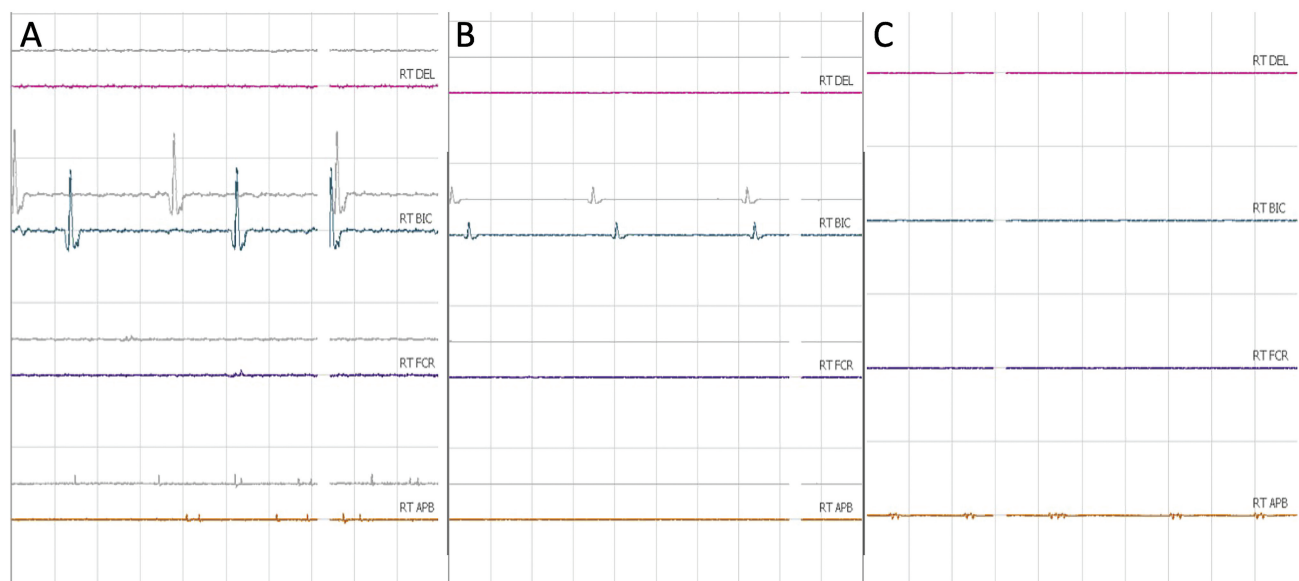


Fig. 2 (A) Continuous raw electromyographic (EMG) recording showing irritative discharge in the right biceps brachii muscle after cervical lateral mass screw fixation (C3–C6), laminectomy, and rod placement on the right side. (B) Continuous raw EMG recording showing significant reduction in the amplitude of irritative discharge in the right biceps brachii after posterior foraminotomy. (C) Continuous raw EMG recording showing the complete disappearance of irritative discharge in the right biceps brachii after rod reapplication with a lesser rod lordosis.

muscle fully disappeared after the rod was reapplied with a lesser lordosis than the prior contouring (►Fig. 2C). There were no further irritative EMG discharges following bilateral rod placement. The trachea was successfully extubated following an uneventful intraoperative course, and the patient's neurological assessment revealed baseline motor power.

Discussion

Following cervical lateral mass screw fixation and cervical laminectomy, a rod is placed and final screw tightening is performed. The nerve roots have an anteromedial location with the cervical lateral mass screws after their correct placement. The irritative discharges in the raw EMG can be due to the vicinity of the screw tip with the nerve root or stretching of the nerve root due to excessive cervical lordosis following the rod placement. Immediate intraoperative identification and rectification with continuous raw EMG recording is imperative to prevent postoperative neurological complications. Intraoperative raw EMG monitoring is an excellent modality to monitor nerve root integrity with high specificity.^{4,5} We noticed the irritative EMG discharges in the right biceps brachii muscle immediately after the right rod placement. A significant reduction in the amplitude of the irritative EMG discharge was noted following the right C5–C6 foraminotomy. The C5–C6 nerve roots get stretched due to the backward drifting of the spinal cord following cervical laminectomy. Posterior foraminotomy is a standard procedure to relieve cervical nerve root compression by partial removal of the medial aspect of the facet joint.⁶ Posterior foraminotomy creates more space allowing the roots to drift along with the spinal cord, thereby reducing its stretching and mechanical irritation. A second measure involved recontouring the rod and applying it to reduce lordosis, which resulted in the complete disappearance of the irritative EMG discharge. The foraminal height at the apex of lordosis, which is typically at the C5–C6 level, is opened up by reducing the rod's lordosis.

Conclusion

Irritation of the C5–C6 nerve roots due to compression or stretching can be anticipated after posterior cervical instru-

mentation. Upon completion of the procedure, re-instrumentation may be required if mechanical compression or stretching of the cervical nerve root is suspected based on raw EMG. Posterior foraminotomy is a standard method to relieve cervical nerve root compression. It can be performed as an immediate corrective measure if irritative EMG discharges are noted following the completion of the cervical instrumentation and this can even avoid a complete re-instrumentation.

Authors' Contributions

B.V. was responsible for design, conceptualization, medical writing, and initial draft of the manuscript. R.G., S.G., and S.R. were responsible for manuscript review and editing.

Conflict of Interest

None declared.

Acknowledgment

We are grateful to Sakra World Hospital in Bengaluru, India, where the authors handled the case.

References

- 1 Ludwig SC, Kramer DL, Balderston RA, Vaccaro AR, Foley KF, Albert TJ. Placement of pedicle screws in the human cadaveric cervical spine: comparative accuracy of three techniques. *Spine* 2000;25(13):1655–1667
- 2 Miller RM, Ebraheim NA, Xu R, Yeasting RA. Anatomic consideration of transpedicular screw placement in the cervical spine. An analysis of two approaches. *Spine* 1996;21(20):2317–2322
- 3 Yoshihara H, Passias PG, Errico TJ. Screw-related complications in the subaxial cervical spine with the use of lateral mass versus cervical pedicle screws: a systematic review. *J Neurosurg Spine* 2013;19(05):614–623
- 4 Paradiso G, Lee GY, Sarjeant R, Hoang L, Massicotte EM, Fehlings MG. Multimodality intraoperative neurophysiologic monitoring findings during surgery for adult tethered cord syndrome: analysis of a series of 44 patients with long-term follow-up. *Spine* 2006;31(18):2095–2102
- 5 Gunnarsson T, Krassioukov AV, Sarjeant R, Fehlings MG. Real-time continuous intraoperative electromyographic and somatosensory evoked potential recordings in spinal surgery: correlation of clinical and electrophysiologic findings in a prospective, consecutive series of 213 cases. *Spine* 2004;29(06):677–684
- 6 Scoville WB. Cervical spondylosis treated by bilateral facetectomy and laminectomy. *J Neurosurg* 1961;18:423–428