


# Intra-Arterial Nitroglycerin Injection in Upper Extremity Buerger's Disease for Faster Ulcer Recovery: A Case Report

Nyityasmono Tri Nugroho, MD, PhD<sup>1,2</sup>  Raka Aldy Nugraha, MD<sup>2</sup> R. Mohamad Javier, MD<sup>1</sup>  
Alexander Jayadi Utama, MD<sup>1</sup> Dedy Pratama, MD, PhD<sup>1</sup>

<sup>1</sup> Division for Vascular and Endovascular Surgery, Department of Surgery, Faculty of Medicine, Universitas Indonesia – Cipto Mangunkusumo National Hospital, Jakarta, Indonesia

<sup>2</sup> Department of Surgery, Faculty of Medicine, Universitas Indonesia – University of Indonesia Hospital, Depok, Indonesia

**Address for correspondence** Nyityasmono Tri Nugroho, MD, PhD, Building A, Third Floor, Cipto Mangunkusumo Hospital, Jalan Diponegoro 71, Jakarta 10430, Indonesia (e-mail: yasmonn@gmail.com).

Int J Angiol

## Abstract

Thromboangiitis obliterans (TAO), also known as Buerger's disease, is a challenging nonatherosclerotic vascular disorder predominantly affecting smokers. Current management of TAO lacks standard guidelines, with smoking cessation as the only cornerstone. We present the case of a 28-year-old smoker with TAO manifesting as necrotic finger ulcers. Regardless of initial debridement, conventional therapy failed to improve his condition. Angiography confirmed the diagnosis of TAO and intra-arterial nitroglycerin injection was administered, leading to immediate vasodilation and improved perfusion. Combined with oral vasodilators and anticoagulants, the patient showed significant ulcer healing within 2 weeks. TAO's etiology remains unclear; however, it is linked to smoking and immune responses. Diagnosis relies on clinical criteria and angiographic findings. While smoking cessation remains crucial, various pharmacological interventions like vasodilators show considerable potential for enhancing therapeutic outcomes. Our case highlights the potential of intra-arterial nitroglycerin in TAO management. However, further studies are warranted due to limited sample size. Advancements in understanding TAO's biology and diagnostic techniques offer hope for improved management strategies in the future.

## Keywords

- ▶ thromboangiitis obliterans
- ▶ Buerger's disease
- ▶ smoking
- ▶ angiography
- ▶ intra-arterial
- ▶ nitroglycerin
- ▶ vasodilator

Thromboangiitis obliterans (TAO), also known as Buerger's disease, is a progressive, nonatherosclerotic, diffuse segmental inflammatory disease affecting small to medium arteries, vein, and nerves of the extremities.<sup>1–3</sup> There are no standard guidelines on the management of TAO and the mainstay treatment relies on smoking cessation.<sup>3,4</sup> Surgical intervention is proven to be ineffective owing to the diffuse nature of the thrombus affecting the segmental vessels, while endovascular interventions are often challenging.<sup>3,5</sup> Vasodilators have also been

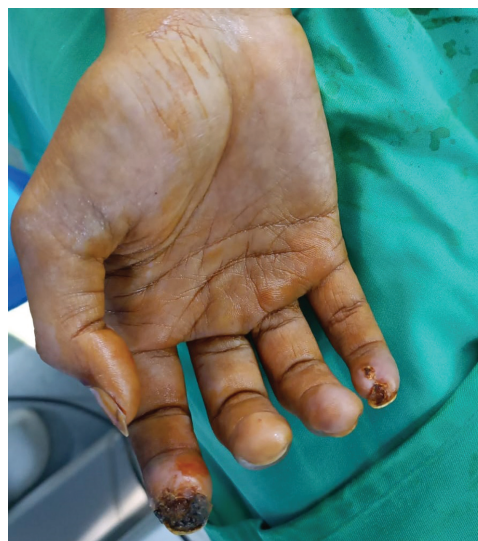discussed for its potential use in TAO; however, it has not widely been studied. Prostacyclin has been the most studied pharmacological agent with moderate efficacy.<sup>6</sup> The other potential agents include endothelin-1 receptor antagonist, phosphodiesterase type 5 inhibitor, and prostaglandin E1 analogues.<sup>1</sup> To the best of our knowledge, no literature has ever been published in favor of the use of a nitrate agent in TAO. Here, we presented a case of TAO treated with intra-arterial nitroglycerin that resulted in favorable ulcer recovery.

## Case Report

A 28-year-old man with a smoking history (2 packs a day; Brinkman Index of 200 pack-years) was referred to our vascular clinic complaining disturbing pain and darkening of the tip of his right index and little fingers for the past month. The complaints were precipitated by a traumatic event where he got his fingers squeezed by a car door approximately 4 months earlier. The patient reported neither cardiovascular risk factors nor comorbidities other than smoking. The patient had undergone debridement surgery in the previous hospital, but no improvement was seen. Upon examination, necrotic tissue along with perifocal edema was found on the tip of his right index and little fingers (→Fig. 1). The patient was given clopidogrel 75 mg once daily, cilostazol 100 mg twice daily, and warfarin 2 mg once daily and was also advised to completely stop smoking. The patient was followed up after 1 week where no improvement was observed and was scheduled for angiography and another debridement surgery.

Contrast angiography showed stenosis of the proximal radial artery and total occlusion of the medial ulnar artery with a corkscrew appearance, indicating a TAO (→Fig. 2A B). Subsequently, 10-mg nitroglycerin was injected within 30 minutes through the catheter. Completion angiography showed vasodilation and significantly improved flow to both distal radial and ulnar arteries (→Fig. 2C).

The patient was given a 5,000-IU intravenous heparin injection followed by continuous infusion of 20,000 IU/24 h for 4 days. The patient was discharged on day 4 with clopidogrel 75 mg once daily, cilostazol 100 mg twice daily, and warfarin 2 mg twice daily and was followed up every

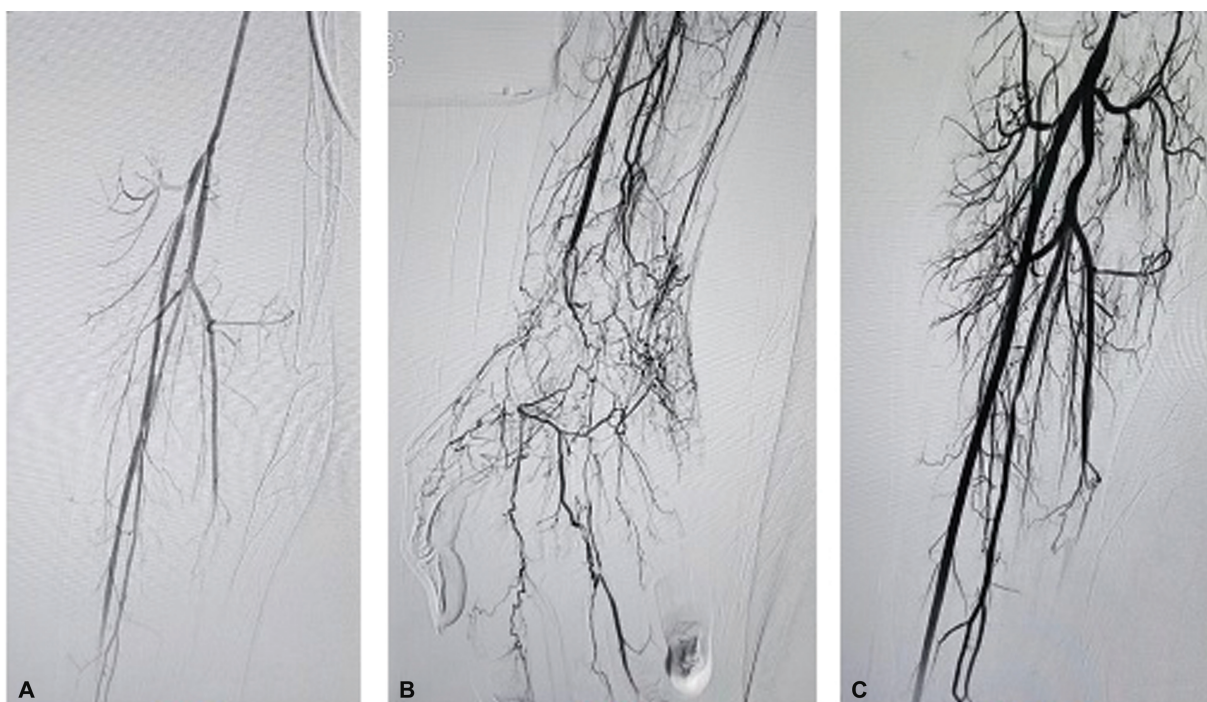


**Fig. 1** Preoperative examination shows darkening of the tip of his right index.

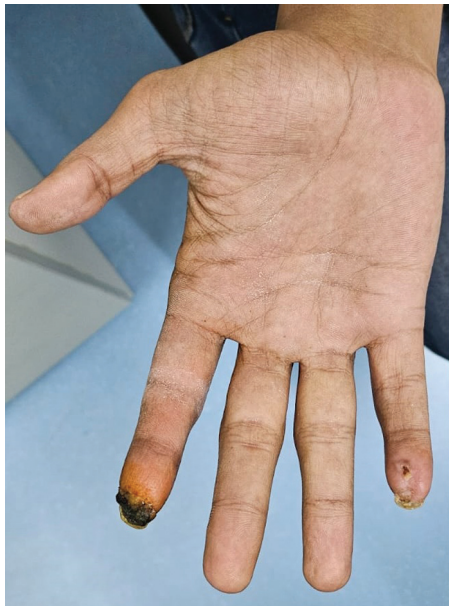week. At 2 weeks, there was significant improvement in wound recovery. The necrotic area was reduced, and the patient complained of only minimal pain (→Fig. 3).

## Discussion

TAO is found to be more prevalent in the eastern part of the world and accounts for approximately 0.5 to 5.6, 45 to 63, 16 to 66, and 80% of the total incidence of peripheral artery disease (PAD) in Western Europe, India, Korea and Japan, and Middle East countries, respectively.<sup>3,7,8</sup> However, in the last two



**Fig. 2** (A, B) Stenosis of the proximal radial artery and total occlusion of the medial ulnar artery with corkscrew appearance. (C) Vasodilation and significantly improved flow to both distal radial and ulnar arteries (after nitroglycerin injection).



**Fig. 3** Postoperative examination at 2 weeks shows significant wound recovery improvement.

decades, the incidence of TAO is decreasing, with an incidence of 0.10 to 0.04 per 100,000 persons-years from 2002 to 2011 in Taiwan.<sup>9</sup> A similar result was reported previously by Matsushita et al, where only 12 TAO patients were recorded between 1990 and 1996 compared with 46 patients between 1985 and 1989.<sup>10</sup> This phenomenon might have been attributed to improvements in the socioeconomic status and lower smoking rates throughout the entire period of observation.<sup>9,10</sup>

The etiology of TAO is unknown; however, studies have linked its occurrence to tobacco exposure, genetic susceptibility, and immune and coagulation response.<sup>8,9,11</sup> Studies have also found increased risk of developing TAO with older age, male gender, and comorbidities such as hypertension, diabetes mellitus, myocardial infarction, heart failure, stroke, chronic kidney disease, malignancy, severe periodontitis, and rickettsial infection.<sup>8,12</sup> However, TAO most typically occurs in young men with an onset before the age of 50 years and a history of excessive smoking.<sup>3,8,9,12</sup> In some cases, the role of history of trauma in the development of TAO has to be better clarified.<sup>13</sup> Histologically, TAO stages are distinguished based on the disease's acute, subacute, and chronic stages.<sup>14,15</sup> Thromboarteritis or a thrombophlebitic process is the initial pathologic process. Furthermore, TAO is distinct from many other forms of vasculitis because it does not exhibit the typical immunologic indicators of elevated acute-phase reactants, circulating immune complexes, and auto-antibodies are often normal or negative. Thus, diagnosis based solely on biochemical blood test result is impossible. People with TAO have been shown to have significant titers of antiendothelial cell antibodies. Multiple hypersensitivity reactions also account for the occurrence of TAO. Type III hypersensitivity is mainly present, in addition to other types of hypersensitivity reactions.<sup>13-15</sup> Numerous researches suggest that oxidative stress increases endothelial cell dysfunction and can affect vascular tone directly by lowering the

bioavailability of nitric oxide (NO). However, it is unclear if the elevated oxidative stress in TAO results from low NO levels or if low NO levels are a contributing factor. Furthermore, it has been documented that in TAO patients, polymorphisms in the NO synthase promoter area are correlated with significant amputation.<sup>16</sup>

The most widely used clinical criteria for directing TAO diagnosis are Shionoya's criteria.<sup>17</sup> Patients with TAO usually present with ischemic signs and symptoms that progress with more advanced disease. Patients at the early stage of the disease typically present with intermittent claudication in either upper or lower extremity that could worsen into rest pain, ulcerations, and gangrene. Raynaud's disease is reported in greater than 40% of TAO and is found to be asymmetrical.<sup>7,8</sup> Diagnosis can further be supported by angiographic findings, which show typical corkscrew-patterned collateral vessels (Martorell's sign), which represent a compensatory mechanism to segmental lesions.<sup>3,12</sup>

Interestingly, the patient presented here experienced a thrombotic event that was precipitated by a traumatic injury a few months earlier, which resulted in inflammation and abscess formation. However, despite undergoing debridement, the wound did not heal and two of his fingers got darker and painful. He further developed rest pain and gangrene of the right index and little fingers that lasted for a month. Angiography showed typical corkscrew collaterals, confirming the diagnosis of TAO.

Currently there is no consensus regarding the gold standard management of TAO. However, smoking cessation has always been the core pillar of TAO treatment. Studies showed that tobacco withdrawal is effective in terminating disease progression.<sup>9,18</sup> The exact mechanism on how smoking precipitates thrombotic events remains unclear. It is thought to be mediated by smoking-induced endothelial dysfunction, which creates a highly thrombotic environment.<sup>3</sup> For decades, researchers have attempted to investigate the most effective treatment modalities for TAO, but the efforts seem to show slow progress. Surgical intervention was found to be ineffective in TAO owing to the diseased distal vessels and diffused nature of the thrombosis.<sup>3,5</sup> Endovascular intervention is also challenging because of the distal location, which is usually complicated by compromised distal run-off. Successful revascularization is essential in such cases in order to heal the ulcer, rapidly. Graziani et al performed percutaneous transluminal angioplasty, which was followed by stent placement in some patients with unsatisfactory recanalization, which resulted in 95% technical success rate.<sup>19</sup> The other potential interventions include sympathectomy and spinal cord stimulation, the usefulness and effectiveness of which remain controversial.<sup>3</sup>

Studies on medical therapy in TAO are limited and the majority investigated the potentials of oral high-potency vasodilators. Iloprost, a prostacyclin analog, has been shown to exert potential therapeutic effects in TAO. Bozkurt et al showed complete healing rate of 60.23% at 24 weeks and significantly improved pain and ulcer size at 4 and 24 weeks.<sup>20</sup> Iloprost is the only vasodilator that has been studied among Buerger's disease patients and it was found

that intravenous iloprost was superior than aspirin in terms of mending ulcers, lowering discomfort during rest, and lowering the incidence of amputations. The vasodilator mechanism will improve the circulatory system and arterial blood circulation, decrease the systemic vascular resistance, and dilate the vessels proximity to the lesion. As a result, it decreases blood flow to the area of distal ischemia. Additional vasodilators such as sildenafil,  $\alpha$ -blockers, and calcium channel blockers may be beneficial. However, they have not been examined in clinical studies.<sup>21,22</sup> Individuals who have Buerger's disease typically experience excruciating ischemic agony. As a result, using analgesics is crucial. High-dose sedatives and substances containing morphine are frequently used to lessen pain. Additionally, neuro-blockers, epidural anesthetic, and antidepressants are used.<sup>21</sup>

Endovascular therapy in TAO is a potentially beneficial and technically feasible therapeutic option. Combined antegrade and retrograde therapies may enhance clinical recovery and technical success, particularly when the antegrade technique has not worked.<sup>23</sup> Unpredictable intervals of recovery time and recurrence are hallmarks of TAO, which can potentially lead to idiopathic mortality in the 45- to 50-year age range.<sup>21</sup> In our case, the use of intra-arterial nitroglycerin injection and the combination of oral vasodilator, anticoagulant, and antiplatelet gave significant immediate improvement in wound recovery. The necrotic area was reduced, and the patient complained of only minimal pain. As we know, this is because of the way that nitroglycerin mechanism acts in the body, converting it to NO. In vascular smooth muscle and other tissues, NO subsequently triggers the enzyme guanylyl cyclase, which changes guanosine triphosphate (GTP) to guanosine 3',5'-cyclic monophosphate (cGMP). Following this, cGMP triggers many phosphorylations of proteins that are dependent on protein kinase. These phosphorylations improve calcium absorption into the sarcoplasmic reticulum, raise extracellular calcium levels, and open the calcium-gated potassium channel, creating the intended vasodilatory impact by relaxing the smooth muscle in the blood vessels, under the autonomic nervous system.<sup>7,8</sup> When compared with iloprost, nitroglycerin has less scientific evidence when it comes to intra-arterial injection treatment, as discussed earlier.

## Conclusion

More information on the biology of TAO has been discovered during the years of research. Patients can be diagnosed more quickly even though the causes of the disease are still unknown because to advancements in diagnostic techniques and a greater knowledge of the nature of the illness. The largest obstacle to effective treatment still remains. While quitting smoking is presently the best way to prevent problems and halt the progression of the illness, there is currently no definitive and gold standard management for TAO. Patients with Buerger's disease may experience an improvement in pain and healing of ulcers by reducing tobacco usage and avoiding secondhand smoke. Moreover, other treatment modalities such as nitroglycerin, which are used in vasodila-

tor therapy, may potentially contribute to ulcer healing and recovery. In our situation, the patient's ulcers healed and his pain improved as a result of intra-arterial nitroglycerin injection and the combination of other vasodilators. That being said, the sample size of this study is severely limited. Larger, more detailed investigations should be done to confirm the results of the study. New clinical studies are currently ongoing and could be a game changer in the future.

## Funding

None.

## Conflict of Interest

None declared.

## References

- Jiménez-Gallo D, Albarrán-Planellas C, Arjona-Aguilera C, Blanco-Sánchez G, Rodríguez-Mateos ME, Linares-Barríos M. Treatment of thromboangiitis obliterans (Buerger's disease) with high-potency vasodilators. *Dermatol Ther* 2015;28(03):135-139
- Hartmann P, Mohokum M, Schlattmann P. The association of Raynaud syndrome with thromboangiitis obliterans: a meta-analysis. *Angiology* 2012;63(04):315-319
- Rivera-Chavarría IJ, Brenes-Gutiérrez JD. Thromboangiitis obliterans (Buerger's disease). *Ann Med Surg (Lond)* 2016;7:79-82
- Uyanık SA, Ögürlü U, Aminu IS, et al. Endovascular treatment of critical limb ischemia in Buerger disease (thromboangiitis obliterans) with midterm follow-up: a viable option when bypass surgery is not feasible. *AJR Am J Roentgenol* 2021;216(02):421-427
- Dargon PT, Landry GJ. Buerger's disease. *Ann Vasc Surg* 2012;26(06):871-880
- Bozkurt AK, Köksal C, Demirbas MY, et al; Turkish Buerger's Disease Research Group. A randomized trial of intravenous iloprost (a stable prostacyclin analogue) versus lumbar sympathectomy in the management of Buerger's disease. *Int Angiol* 2006;25(02):162-168
- Sawan ZH, Soliman M, Ezzat A, Mostafa A, Kamel RA. A review on nitroglycerin: present and future. *Egypt J Hosp Med* 2018;2023;91(01):4972-4974
- Maniskas ME, Roberts JM, Trueman R, et al. Intra-arterial nitroglycerin as directed acute treatment in experimental ischemic stroke. *J Neurointerv Surg* 2018;10(01):29-33
- Zheng JF, Chen YM, Chen DY, Lin CH, Chen HH. The incidence and prevalence of thromboangiitis obliterans in Taiwan: a nationwide, population-based analysis of data collected from 2002 to 2011. *Clinics (São Paulo)* 2016;71(07):399-403
- Matsushita M, Nishikimi N, Sakurai T, Nimura Y. Decrease in prevalence of Buerger's disease in Japan. *Surgery* 1998;124(03):498-502
- Bérard AM, Bedel A, Le Trequesser R, et al. Novel risk factors for premature peripheral arterial occlusive disease in non-diabetic patients: a case-control study. *PLoS One* 2013;8(03):e37882
- Choi B, Jang SY, Kim SK, Kim N, Kim K, Kim DK. The incidence, prevalence, and survival rate of thromboangiitis obliterans in Korea: a retrospective population-based study. *Cardiovasc Diagn Ther* 2020;10(05):1238-1244
- Zheng P, Wang W. Etiology and Pathogenesis of Buerger's Disease. In: Mourad Aribi, ed. *Probing Selected Autoimmune Diseases for Focused Perspectives*. London: IntechOpen; 2024
- Şahin S. Thromboangiitis obliterans (Buerger's disease). *Dent Med J-Rev* 2022;4(01):79-89
- Bogacz R, Gaik M, Uram E, et al. Thromboangiitis obliterans (Buerger's disease): a review. *J Educ Health Sport* 2023;36(01):124-134

- 16 Fazeli B, Ligi D, Keramat S, Maniscalco R, Sharebani H, Mannello F. Recent updates and advances in Winiwarter-Buerger disease (thromboangiitis obliterans): biomolecular mechanisms, diagnostics and clinical consequences. *Diagnostics (Basel)* 2021;11(10):1736
- 17 Shionoya S. What is Buerger's disease? *World J Surg* 1983;7(04): 544–551
- 18 Mills JL Sr. Buerger's disease in the 21st century: diagnosis, clinical features, and therapy. *Semin Vasc Surg* 2003;16(03):179–189
- 19 Graziani L, Morelli L, Parini F, et al. Clinical outcome after extended endovascular recanalization in Buerger's disease in 20 consecutive cases. *Ann Vasc Surg* 2012;26(03):387–395
- 20 Bozkurt AK, Cengiz K, Arslan C, et al. A stable prostacyclin analogue (iloprost) in the treatment of Buerger's disease: a prospective analysis of 150 patients. *Ann Thorac Cardiovasc Surg* 2013;19(02):120–125
- 21 Aledari M, Alzamili R, Kadim M, Alwan AM, Afshari JT, Darban RA. Thromboangiitis obliterans or Buerger's disease: important characteristics. *J Pharm Negat Results* 2023;14(01):232–248
- 22 Jaroonwanichkul S, Hall JC. Decreasing tobacco use promotes ulcer healing in a patient with Buerger's disease. *Clin Case Rep* 2023;11(02):e6999
- 23 Firat A, Igus B. Endovascular recanalization of thromboangiitis obliterans (Buerger's disease) in twenty-eight consecutive patients and combined antegrade-retrograde intervention in eight patients. *Cardiovasc Intervent Radiol* 2019;42(06): 820–828