



# Medially Based “Abdominal Rotation Advancement Flap”: A Promising Technique for Mastectomy Defect Reconstruction in “High-Risk Patients” Awaiting Adjuvant Radiotherapy

Praveen Harish<sup>1</sup> Kathi Srinath<sup>1</sup> Swamy Vivek<sup>1</sup> Santosh Kumar Gandupalli<sup>2</sup> Yogesh Kadam<sup>2</sup>  
G. Kavya<sup>2</sup>

<sup>1</sup>Department of Plastic Surgery, MNJ Institute of Oncology and Regional Cancer Centre, Hyderabad, Telangana, India

<sup>2</sup>Department of Plastic Surgery, Osmania Medical College, Telangana, India

**Address for correspondence** Santosh Kumar Gandupalli, MS, Mch, Department of Plastic Surgery, 10-2-289/27, Shanti Sagar Apartment, Shanti Nagar Road-2 AC Guards, Hyderabad, Telangana 500028, India (e-mail: santoshtheclarion@gmail.com).

Indian J Plast Surg

## Abstract

**Background** Extensive postmastectomy defects and soft-tissue defects often require some additional flap cover of reconstruction after excision. The reconstruction aim in this group should be a diligent and easy closure with a quality skin cover, early recovery, and brief stay in hospital so that the patients can receive early postoperative radiotherapy/chemotherapy. Medially based abdominal transposition flap is a type C fasciocutaneous flap based on medial perforating vessels. We present our experience in significant postmastectomy defects, especially in high-risk morbid patients.

**Materials and Methods** This is a retrospective study conducted by the department of plastic surgery, from an analysis of the breast cancer database maintained by our hospital from 2019 to 2023. A total of 826 breast cancer patients underwent surgery, of which 547 were locally advanced breast cancer (LABC) patients and 138 (32.5%) LABC patients needed flap cover for mastectomy defect. Medially based abdominal transposition flap was used in 56 of 138 (40.5%) LABC patients for defect closure, and 42 of the 56 patients were stage IIIB patients. Upfront surgery was primarily done in 20 patients and 36 patients underwent surgery after neoadjuvant chemotherapy. This analysis aimed to assess the operative duration, postoperative morbidity, hospital stay, and time taken to start adjuvant treatment by analyzing the medical records of patients who underwent this procedure.

**Results** Fifty-six patients with breast cancer underwent surgical intervention, whereby 8 patients presented with tip and edge necrosis, and 3 patients were infected. The mean duration of operation was 58.852 minutes, and the average length of hospital stay was 5.39 days. It took 24.57 days for the patients to stabilize sufficiently for adjuvant therapy. The average age of the patients in the study was 48.73 years.

## Keywords

- ▶ medially based abdominal transposition flap
- ▶ postmastectomy defects
- ▶ locally advanced breast cancer

DOI <https://doi.org/10.1055/s-0044-1788571>.  
ISSN 0970-0358.

© 2024. Association of Plastic Surgeons of India. All rights reserved. This is an open access article published by Thieme under the terms of the Creative Commons Attribution-NonDerivative-NonCommercial-License, permitting copying and reproduction so long as the original work is given appropriate credit. Contents may not be used for commercial purposes, or adapted, remixed, transformed or built upon. (<https://creativecommons.org/licenses/by-nc-nd/4.0/>)  
Thieme Medical and Scientific Publishers Pvt. Ltd., A-12, 2nd Floor, Sector 2, Noida-201301 UP, India

**Conclusion** Our clinical experience has demonstrated that the medial abdominal transposition fasciocutaneous (MATF) flap represents a straightforward, reliable, and cost-effective method for managing extensive postmastectomy soft-tissue defects in a subset of patients with LABC. This group typically consists of high-risk and comorbid patients. The procedure holds considerable promise for developing countries with limited infrastructure and expertise, owing to its ease of execution and short learning curve. By its simplicity and affordability, the MATF flap offers a viable and sustainable solution for treating LABC-associated soft-tissue defects.

## Introduction

Breast cancer is a widely prevalent condition that affects women worldwide. In developing countries, locally advanced breast cancer (LABC) constitutes a significant proportion of breast cancer cases. In the aftermath of mastectomy, the presence of sizable soft-tissue defects often necessitates additional cover. In such instances, the primary objective of reconstruction is to effectuate prompt and uncomplicated closure with high-quality skin cover, thereby facilitating early recovery and shortened hospital stay. Breast reconstruction techniques have undergone significant evolution over time. These techniques include options such as latissimus dorsi (LD) flap, transverse rectus abdominis myocutaneous (TRAM) flap, deep inferior epigastric artery perforator (DIEP) flap, as well as locoregional and microvascular free flaps. Factors such as patient age and comorbidities, institutional practice, and available surgical expertise<sup>1</sup> are critical in selecting the appropriate reconstruction method.

Selecting a suitable technique can enable patients to receive early postoperative radiotherapy/chemotherapy. Therefore, choosing the most appropriate approach is of utmost importance.

The transverse fasciocutaneous flap has been an essential technique in reconstructive surgery since its first description by Tai and Hasegawa<sup>2</sup> in 1974. This flap is harvested from the homolateral thoracoabdominal (TA) area and is based on perforator vessels from the superior epigastric artery and vein. Subsequently, Davis et al<sup>3</sup> modified the technique in 1977. The vascular anatomy of the anterior and lateral abdominal wall was better understood due to the studies conducted by Brown et al<sup>4</sup> in 1975. Their research has helped enhance the effectiveness of the transverse fasciocutaneous flap and made it a more reliable option for flap reconstruction.

In 1978, Baroudi et al<sup>5</sup> proposed a TA fasciocutaneous flap. This flap was subsequently modified by Rivas et al<sup>6</sup> in the 1980s to extend from the middle sternal line to the anterior axillary line opposite to the defect. During the 1980s, musculocutaneous flaps,<sup>7–10</sup> including the pectoralis major, LD, serratus anterior, rectus abdominis, and omentum flaps, became the preferred method for chest wall reconstruction, either pedicled or free,<sup>11–13</sup> providing adequate coverage even from distant sites. In 1980, Hodgkinson et al<sup>14</sup> revisited large TA flaps and described new musculocutaneous flaps harvested on the external oblique abdominal muscle. Similar

flaps were later described by Bogossian et al<sup>15</sup> in 1996 and Moschella and Cordova<sup>16</sup> in 1999. Despite these surgical variations, few comparative studies have been published, making it difficult to conclude the superiority of musculocutaneous over fasciocutaneous flaps.

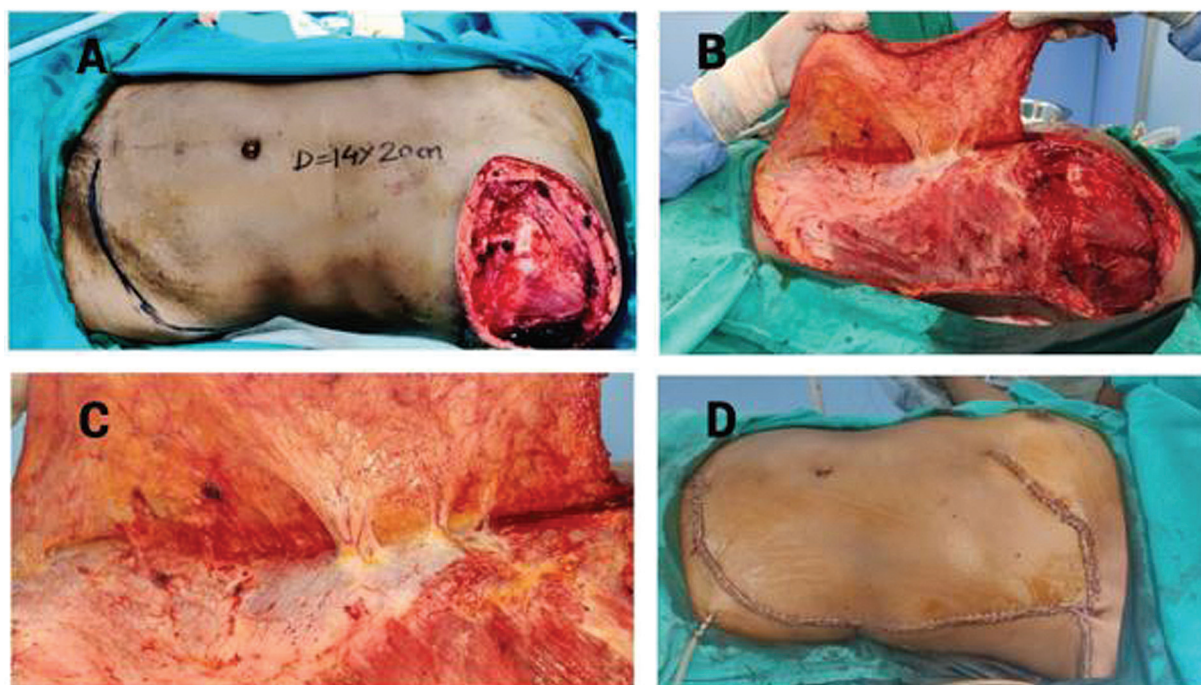
In 2003, Deo et al<sup>17</sup> recommended the fasciocutaneous “TA” flap as the preferred option for patients requiring mastectomy defect reconstruction. However, the muscle-sparing TRAM flap has emerged as a promising alternative for elderly and high-risk patients. This article examines the use of MATF in mastectomy defect reconstruction, including its surgical technique, benefits, and clinical outcomes.

The MATF procedure involves the transfer of abdominal tissue to the breast area to reconstruct the defect. Compared with other methods, MATF offers advantages such as reduced donor site morbidity, shorter hospital stays, and faster recovery time. The surgical technique involves preserving the rectus abdominis muscle while dissecting the overlying skin and subcutaneous tissue.

## Material and Methods

The present study entails a retrospective analysis of a prospectively maintained computerized database pertaining to postmastectomy reconstruction patients in the Department of Plastic Surgery at MNJ Institute of Oncology & Regional Cancer Centre in India. Specifically, we have retrieved and analyzed the medical records and clinical details of patients who underwent MATF flap cover for LABC between 2019 and 2023. Our investigation has aimed to assess several key factors surrounding patient outcomes, including operative duration, blood loss, postoperative morbidity, hospital stay, adjuvant therapy, and recurrence patterns. By conducting a comprehensive analysis of these variables, we aim to provide critical insights into the efficacy and safety of surgical interventions for LABC patients, ultimately contributing to the broader body of knowledge in this field.

The utilization of the MATF flap in reconstructive surgery is a well-established type C rotation advancement fasciocutaneous flap. This technique employs the skin and subcutaneous tissue of the anterior abdominal wall while utilizing two distinct sets of perforating branches. The lateral branches arise from the lumbar and subcostal arteries adjacent to the anterior border of the LD, while the medial branches arise from the deep epigastric arcade.<sup>4</sup> A subfascial



**Fig. 1** Patient 1 exhibits a left-sided postmastectomy defect. (A) Left-sided postmastectomy defect with size 14 × 20 cm. (B) Elevation of medially based abdominal transposition flap. (C) Perforators from the epigastric artery. (D) Postclosure of defect with medial abdominal transposition fasciocutaneous (MATF) flap.

anastomosis between the medial and lateral perforators<sup>1,18</sup> ensures vascular continuity. These features provide the foundation for this technique's effectiveness in reconstructive surgery.

This article concerns harvesting a flap based on medial direct perforating segmental arteries originating from the deep epigastric arcades. The flap is fashioned via the rotation advancement technique, with the surgical plane maintained superficial to the rectus fascia and aponeurosis of the external oblique muscle. The boundaries of the flap are limited by the anterior axillary line laterally and a horizontal plane at the level of the anterosuperior iliac spine inferiorly. The donor site<sup>17</sup> can be closed primarily, thanks to the ability to mobilize the loose abdominal skin. This technique can utilize excess lateral abdominal tissue to restore the breast contour while preserving muscle function, maintaining a nearly natural appearance, and producing minimal morbidity (► Figs. 1 and 2).

## Results

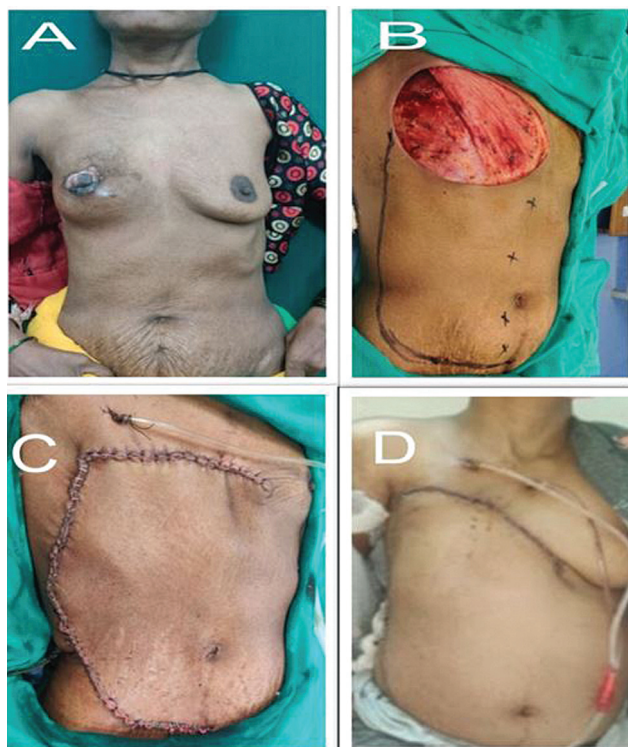
A total of 826 cancer breast patient underwent surgery, of which 547 were LABC patients and 138 (32.5%) of the LABC patients needed flap cover for mastectomy defect. Medially based abdominal transposition flap was used in 56 of 138 (40.5%) LABC patients for defect closure, and 42 of these 56 patients in stage IIIB. Upfront surgery was primarily done in 20 patients and 36 patients underwent surgery after neo-adjuvant chemotherapy (NACT). A total of 56 breast cancer patients underwent surgical intervention, of whom 8 exhibited tip and edge necrosis and 3 were complicated by infection "(Clavien–Dindo grade 2: 1 case; grade 3a: 7cases;

and grade 3b: 3 cases). Three of the eight cases presented extensive necrosis (► Table 1), requiring debridement and latissimus dorsi flap coverage within 5 days following surgery. The remaining five cases, marked by marginal necrosis, were treated with debridement and secondary closure within a week. Of the three instances complicated by infection, one was successfully treated with intravenous antibiotics, while the other two were drained and closed through secondary closure. The mean operating time for these procedures was 58.852 minutes, ranging from 40 to 110 minutes, resulting in minimal blood loss (► Table 2).

The study revealed that the mean duration of hospitalization for patients was 5.39 days, with the minimum and maximum stays being 3 and 14 days, respectively. The average time required for patients to show stability and receive adjuvant therapy was 24.57 days. The mean age of the patients in the study was 48.73 years, with the youngest patient being 33 years old and the oldest being 70 years old. The average defect size was 441.160 cm<sup>2</sup>, with the most minor defect being 210 cm<sup>2</sup> and the largest being 750 cm<sup>2</sup>. These data provide valuable insights into the clinical outcomes and demographics of the study population.

## Discussion

Breast cancer is the most prevalent type of cancer in women worldwide. It is becoming more common in India,<sup>19,20</sup> due to lack of awareness, lack of screening, social stigma, delays in referral, insufficient health care infrastructure, and lengthy waiting lists at tertiary care cancer centers. The majority of breast cancer patients in developing nations like India present with locally advanced stage of the disease.



**Fig. 2** Patient 2 exhibits a right-sided postmastectomy defect. (A) Right-sided locally advanced breast cancer. (B) Right-sided postmastectomy defect. (C) Postclosure with medial abdominal transposition fasciocutaneous (MATF) flap. (D) Postoperative day 3 status of the flap.

Surgical intervention is a fundamental element of the treatment plan for LABC after NACT. In some instances, patients who do not respond favorably to NACT may require a radical excision of the affected skin, which results in extensive soft-tissue defects that cannot be healed by primary closure. To address these defects, supplementary surgical procedures may be required. Numerous options are available for treating these postmastectomy defects, which have been chronicled in the literature dating back to the Halstead era.<sup>21</sup>

In the first half of the 20th century, postradical mastectomy defects of significant size were typically addressed through a treatment regimen utilizing the principles of healing by secondary intention, as well as staged split-thickness skin grafting. However, the results of such an approach were not ideal owing to the suboptimal nature of the resultant cosmetic and therapeutic outcomes. In addition, the use of skin grafts is associated with several risks, including secondary infection, morbidity at both the recipient and donor sites, staged procedures, late contracture, and partial or complete graft loss following radiotherapy.<sup>22–24</sup>

**Table 1** Postoperative complications

Sl. no.	Complications	No. of cases	%
1	Tip necrosis	5	8.9
2	Partial necrosis	3	5.3
3	infection	1	1.7
4	seroma	4	7

A range of locoregional tissue transfer techniques have been developed with the aim of early wound healing and a decreased risk of total flap failure.<sup>1,11,17,24–29</sup> These techniques include the bilateral advancement flap, a relatively uncomplicated method of wound closure that results in a single horizontal scar on the chest wall.<sup>21</sup> However, this technique is unsuitable for more extensive wounds with increased vertical dimensions, as such wounds may be subject to tension, resulting in wound dehiscence.

The field of reconstructive surgery experienced a significant breakthrough in the latter part of the 20th century, thanks to the introduction of the dermal muscle flap, which yielded impressive results. In 1896, Iginio Tansini performed the first broad dorsal muscle flap (LD) procedure to address a significant defect following a radical mastectomy.<sup>30</sup> However, the utility of the LD flap declined later, as Halstead considered it an unnecessary and risky procedure.<sup>31</sup> Subsequently, it was not until 1975 that the LD flap was reintroduced as a viable option for reconstructing defects after mastectomy, and it remained popular until 1982.<sup>32,33</sup>

The literature reports the utilization of omentum transposition in conjunction with skin grafts to conceal defects resulting from mastectomy and chest wall surgeries. Lopez et al<sup>34</sup> reported a 76% success rate and an 8% incidence of abdominal hernia in 50 patients with advanced breast cancer who underwent omental transposition with Split Skin Graft (SSG). Similarly, Cheung et al<sup>35</sup> reported a 100% success rate and a median hospital stay of 16 days in breast cancer patients who underwent omental transposition. Despite its efficacy, omental transplantation has not garnered much popularity due to associated complications such as hernia, wound infection, and abdominal rupture, as well as the morbidity of laparoscopic surgery. Moreover, the feasibility of skin grafts in the omental bed is also limited<sup>35</sup> in certain patients.

The TRAM flap technique for breast reconstruction was introduced by Hartrampf et al<sup>33</sup> in 1982. This technique is characterized by its superior cosmetic outcomes, reliability, positional advantage, and added benefit of abdominoplasty, and has been the primary method for breast reconstruction until the 1990s.<sup>36</sup> However, it is essential to note that the TRAM flap technique is technically demanding and is associated with significant wound and donor site morbidities such as subsequent muscle weakness and hernias. As such, careful consideration is advised before opting for this method of breast reconstruction.

The TA flap was first described in 1975 by Brown et al.<sup>4</sup> It is a type C fasciocutaneous flap that utilizes the skin and fat from the upper abdomen based on the medial or lateral perforating vessels. The TA flap has been used in breast reconstruction with a prosthesis and soft-tissue cover after surgery for LABC during the late 1970s and early 1980s.<sup>1,4,18,23</sup> However, the usage of TA flaps significantly declined with the introduction of myocutaneous flaps in the 1980s.

Keystone perforator island flap (KPIF) is a local advancement flap based on multiple perforators, including fasciocutaneous and musculocutaneous perforators, which results in reliable and versatile vascularization. Introduced in 2003,

**Table 2** Statistics of patients

Sl. no.	Age (y)	Defect size (cm <sup>2</sup> )	Time for reconstruction (min)	Hospital stay (d)	Complications	Adjuvant therapy received after (d)
1	44	18 × 20	55	3	None	26
2	50	21 × 19	90	5	Tip and edge necrosis	23
3	51	23 × 21	55	6	None	22
4	45	25 × 23	50	5	None	27
5	47	22 × 24	65	4	None	24
6	53	20 × 19	40	3	None	21
7	39	24 × 28	55	5	Tip and edge necrosis	25
8	44	27 × 23	45	12	Infection	22
9	38	25 × 16	110	4	None	23
10	41	24 × 15	60	4	None	22
11	60	22 × 18	50	5	None	28
12	40	30 × 15	55	6	None	27
13	56	22 × 12	50	3	None	18
14	49	25 × 30	45	9	Infection	23
15	52	20 × 15	65	5	None	21
16	45	20 × 25	70	3	None	20
17	42	30 × 25	50	14	Tip and edge necrosis	30
18	37	25 × 14	45	4	None	29
19	62	19 × 18	80	5	None	26
20	58	23 × 24	45	8	None	23
21	46	25 × 20	50	6	None	22
22	53	24 × 23	75	3	None	27
23	55	14 × 15	50	10	INFECTION	24
24	39	22 × 21	45	5	None	21
25	33	19 × 19	60	7	None	25
26	41	21 × 20	65	8	Tip and edge necrosis	22
27	46	24 × 22	55	5	None	23
28	44	25 × 23	40	3	None	22
29	52	23 × 20	70	5	None	28
30	49	18 × 17	50	4	None	27
31	65	26 × 20	65	4	None	24
32	47	21 × 19	55	3	None	27
33	53	21 × 20	100	4	None	23
34	34	22 × 17	50	4	None	32
35	40	26 × 26	60	5	None	29
36	45	17 × 15	45	4	None	23
37	54	21 × 15	55	6	None	25
38	68	18 × 14	110	3	None	19
39	62	22 × 21	80	4	None	30
40	58	19 × 24	45	4	None	21
41	43	23 × 12	50	5	None	24
42	39	23 × 16	70	9	Tip and edge necrosis	27
43	53	20 × 15	55	3	None	22

(Continued)

**Table 2** (Continued)

Sl. no.	Age (y)	Defect size (cm <sup>2</sup> )	Time for reconstruction (min)	Hospital stay (d)	Complications	Adjuvant therapy received after (d)
44	37	27 × 21	50	5	None	27
45	46	24 × 17	50	5	None	30
46	54	21 × 22	65	6	None	24
47	70	19 × 16	70	3	None	22
48	63	25 × 18	55	5	None	28
49	42	23 × 20	45	11	Tip and edge necrosis	23
50	59	29 × 23	50	3	None	27
51	45	30 × 21	55	8	Tip and edge necrosis	24
52	36	25 × 19	45	4	None	19
53	64	17 × 17	75	5	None	30
54	57	22 × 18	50	10	Tip and edge necrosis	22
55	38	18 × 21	60	6	None	27
56	46	17 × 20	50	4	None	26

this flap is relatively used for small defect throughout the body. In 2011, keystone flap could be used for larger defect in both the trunk and the extremities. However, there are several modifications to cover a large defect, such as double keystone flap or deep fascia incision to allow better mobility. Another modification but commonly overlooked is the omega subtype, which optimizes a part of the flap with excessive laxity during its inseting.<sup>37</sup>

In 2019, we initiated using the medially based abdominal transposition flap as an alternative to the TA flap for treating lumpectomy breast cancer defects. This technique has yielded positive outcomes, leading us to primarily employ the MATF flap for patients who are elderly or in fragile health. But this flap has some drawbacks such as the following: (1) it mainly covers chest wall wounds for timely healing and adjuvant rather than true breast reconstruction, (2) it results in visible scars in saree, and (3) the option of abdomen-based free/pedicle flap is lost forever.

The average operating time for the TA flap, in our study, was 58.852 minutes, with minimal blood loss. However, compared with the TA flap, the MATF flap provides several advantages, including a shorter average hospital stay of 5.39 days and reduced morbidity. Patients who received the MATF flap have also experienced high-quality vascularized skin coverage and have demonstrated the capacity to tolerate postoperative radiation without significant wound morbidity.

Overall, our experience with the MATF flap has been favorable, and we believe it is a safe and effective option for treating lumpectomy breast cancer defects in appropriate patient populations.

## Conclusion

Breast reconstruction is a crucial procedure for patients with LABC. The main goal is to ensure that the skin cover is simple, efficient, and reliable, allowing for quick recovery and timely

administration of adjuvant therapy. However, for a subset of LABC patients with aggressive biology that does not respond to NACT, cosmetic breast reconstruction of the breast mound is not a top priority. The use of myocutaneous flaps, such as the LD and TRAM flaps, presents technical challenges and is not commonly practiced by the general surgical community for managing postmastectomy soft-tissue defects. These flaps are primarily reserved for high-volume centers specializing in cosmetic breast reconstruction.

Our clinical experience has demonstrated that using the MATF flap technique is a practical, dependable, and cost-effective solution for managing significant postmastectomy soft-tissue defects in patients with LABC. This procedure is particularly successful in handling this type of patient subset, where the patient is at high risk or has other health conditions. The technique has remarkable potential in developing countries that treat many LABC patients but may lack the necessary medical expertise or infrastructure. The procedure is straightforward, has a short learning curve, and promotes efficient wound healing, making it an excellent option for follow-up treatments. Surgical delay, either pre- or postmastectomy, can be considered in future modifications to decrease edge necrosis.

## Funding

None.

## Conflict of Interest

None declared.

## References

- 1 Leinster SJ, Webster DJ. Thoraco-abdominal and thoracoepigastric flaps: alternatives to skin grafting after mastectomy. *Clin Oncol* 1982;8(02):145–148
- 2 Tai Y, Hasegawa H. A transverse abdominal flap for reconstruction after radical operations for recurrent breast cancer. *Plast Reconstr Surg* 1974;53(01):52–54

- 3 Davis WM, McCraw JB, Carraway JH. Use of a direct, transverse, thoracoabdominal flap to close difficult wounds of the thorax and upper extremity. *Plast Reconstr Surg* 1977;60(04):526–533
- 4 Brown RG, Vasconez LO, Jurkiewicz MJ. Transverse abdominal flaps and the deep epigastric arcade. *Plast Reconstr Surg* 1975;55(04):416–421
- 5 Baroudi R, Pinotti JA, Keppke EM. A transverse thoracoabdominal skin flap for closure after radical mastectomy. *Plast Reconstr Surg* 1978;61(04):547–554
- 6 Rivas B, Carrillo JF, Escobar G. Reconstructive management of advanced breast cancer. *Ann Plast Surg* 2001;47(03):234–239
- 7 Larson DL, McMurtrey MJ. Musculocutaneous flap reconstruction of chest-wall defects: an experience with 50 patients. *Plast Reconstr Surg* 1984;73(05):734–740
- 8 Tobin GR, Mavroudis C, Howe WR, Gray LA Jr. Reconstruction of complex thoracic defects with myocutaneous and muscle flaps. Applications of new flap refinements. *J Thorac Cardiovasc Surg* 1983;85(02):219–228
- 9 Arnold PG, Pairolero PC. Chest-wall reconstruction: an account of 500 consecutive patients. *Plast Reconstr Surg* 1996;98(05):804–810
- 10 Cohen M, Ramasastry SS. Reconstruction of complex chest wall defects. *Am J Surg* 1996;172(01):35–40
- 11 Micali E, Carramaschi FR. Extended V-Y latissimus dorsi musculocutaneous flap for anterior chest wall reconstruction. *Plast Reconstr Surg* 2001;107(06):1382–1390, discussion 1391–1392
- 12 Hidalgo DA, Saldana EF, Rusch VW. Free flap chest wall reconstruction for recurrent breast cancer and radiation ulcers. *Ann Plast Surg* 1993;30(04):375–380
- 13 Cordeiro PG, Santamaria E, Hidalgo D. The role of microsurgery in reconstruction of oncologic chest wall defects. *Plast Reconstr Surg* 2001;108(07):1924–1930
- 14 Hodgkinson DJ, Arnold PG. Chest-wall reconstruction using the external oblique muscle. *Br J Plast Surg* 1980;33(02):216–220
- 15 Bogossian N, Chaglassian T, Rosenberg PH, Moore MP. External oblique myocutaneous flap coverage of large chest-wall defects following resection of breast tumors. *Plast Reconstr Surg* 1996;97(01):97–103
- 16 Moschella F, Cordova A. A new extended external oblique musculocutaneous flap for reconstruction of large chest-wall defects. *Plast Reconstr Surg* 1999;103(05):1378–1385
- 17 Deo SV, Purkayastha J, Shukla NK, Asthana S. Myocutaneous versus thoraco-abdominal flap cover for soft tissue defects following surgery for locally advanced and recurrent breast cancer. *J Surg Oncol* 2003;83(01):31–35
- 18 Bohmert H. Experience in breast reconstruction with thoracoepigastric and advancement flaps. *Acta Chir Belg* 1980;79(02):105–110
- 19 Jhulka PK, Prasad R, Mohanti BK, et al. Cancer of the breast. In: Rath GK, Mohanti BK, eds. *Textbook of Radiation Oncology*. New Delhi: B. I. Churchill Livingstone; 2000:239–284
- 20 Parkin DM, Pisani P, Ferlay J. Estimates of the worldwide incidence of eighteen major cancers in 1985. *Int J Cancer* 1993;54(04):594–606
- 21 Halsted WS. I. The results of operations for the cure of cancer of the breast performed at the Johns Hopkins Hospital from June, 1889, to January, 1894. *Ann Surg* 1894;20(05):497–555
- 22 Nakao K, Miyata M, Ito T, et al. Omental transposition and skin graft in patients for advanced or recurrent breast cancer. *Jpn J Surg* 1986;16(02):112–117
- 23 Parkash S, Srinivasan R, Ananthakrishnan N. Primary closure of excisional defects of the breast with local flaps: a problem in the treatment of advanced carcinoma of the breast in developing countries. *Br J Plast Surg* 1981;34(03):291–294
- 24 Ryan JJ. A lower thoracic advancement flap in breast reconstruction after mastectomy. *Plast Reconstr Surg* 1982;70(02):153–160
- 25 Skoracki RJ, Chang DW. Reconstruction of the chestwall and thorax. *J Surg Oncol* 2006;94(06):455–465
- 26 Persichetti P, Tenna S, Cagli B, Scuderi N. Extended cutaneous “thoracoabdominal” flap for large chest wall reconstruction. *Ann Plast Surg* 2006;57(02):177–183
- 27 Matros E, Disa JJ. Uncommon flaps for chest wall reconstruction. *Semin Plast Surg* 2011;25(01):55–59
- 28 McCraw JB, Bostwick J III, Horton CE. Methods of soft tissue coverage for the mastectomy defect. *Clin Plast Surg* 1979;6(01):57–69
- 29 Strauch B, Vasconez LO, Hall-Findlay EJ, et al. Thoraco-epigastric skin/fascia flap to the arm. In: Strauch B, Vasconez L, Hall-Findlay E, et al., eds. *Grabb's Encyclopedia of Flaps: Upper Extremities*. Philadelphia, PA: Lippincott Williams & Wilkins; 2009:981–984
- 30 Maxwell GP, Iginio Tansini and the origin of the latissimus dorsi musculocutaneous flap. *Plast Reconstr Surg* 1980;65(05):686–692
- 31 Schneider WJ, Hill HL Jr, Brown RG. Latissimus dorsi myocutaneous flap for breast reconstruction. *Br J Plast Surg* 1977;30(04):277–281
- 32 Bostwick J III. Latissimus dorsi flap: current applications. *Ann Plast Surg* 1982;9(05):377–380
- 33 Hartrampf CR Jr, Schelfan M, Block PW. Breast reconstruction with TRAM. *Plast Reconstr Surg* 1982;69:216–225
- 34 Lopez JF, Bouchet Y, Dupre A. The Kiriuta procedure in reconstructive surgical treatment of the breast. *Surg Gynecol Obstet* 1990;170(03):209–211
- 35 Cheung KL, Willsher PC, Robertson JF, Bailie FB, Daly JC, Blamey RW. Omental transposition flap for gross locally recurrent breast cancer. *Aust N Z J Surg* 1997;67(04):185–186
- 36 McGraw JB, Papp C, Crammer A, et al. Breast reconstruction following mastectomy. In: Bland KI, Copeland EM III, eds. *The Breast: Comprehensive Management of Benign and Malignant Diseases*. Philadelphia, PA: WB Saunders Co.; 1998:962–999
- 37 Rini IS, Krisna MA, Kamayana J, Djarot KR, Gunardi AJ. Keystone perforator island flap for postmastectomy defect resurfacing in late-stage breast cancer patients. *Plast Reconstr Surg Glob Open* 2019;7(11):e2457