




# The Fatty Dilemma: A Rare Instance of Extra- and Intravascular Lipoma of the Brachiocephalic Vein

Roja Hiregouja Eranna<sup>1</sup> Suhasini Devi Pokanati<sup>1</sup> B. Rajkumar<sup>1</sup>

<sup>1</sup>Department of Radiodiagnosis, Continental Hospitals, Hyderabad, Telangana, India

**Address for correspondence** Roja Hiregouja Eranna, DNB (Radiodiagnosis), Mallikarjuna Nilaya, 4th Block, 1st Cross, Kalyana Nagar, Jyothi Nagar Post, Chikmagalur 577102, Karnataka, India (e-mail: rojahek@gmail.com).

Indian J Radiol Imaging

## Abstract

Oftentimes, incidental findings are made on routine diagnostic imaging. An intra- and extravascular lipoma is one example of an important incidental finding. Intravascular lipomas are rare benign vascular tumors that are typically asymptomatic. They are most commonly found in the inferior vena cava but have also been recorded in the superior vena cava, brachiocephalic vein, subclavian vein, internal jugular vein, external jugular vein, and common femoral vein. Here, we presented the case of a 64-year-old female patient with an incidentally discovered intra- and extravascular lipoma affecting the right subclavian and brachiocephalic veins. While benign, intravascular lipoma on imaging can resemble a malignant tumor such as leiomyosarcoma or thrombus. As a result, appropriate identification and classification of this imaging finding is crucial for avoiding an exorbitant and futile workup.

## Keywords

- ▶ lipoma
- ▶ intravenous lipoma
- ▶ intra- and extravascular lipoma
- ▶ brachiocephalic vein
- ▶ intravascular tumor

## Introduction

Lipomas are benign, well-differentiated tumors made up of adipocytes and are the most common type of soft tissue mass.<sup>1</sup> They can appear anywhere in the body but are most commonly found in the subcutaneous tissue of the upper half and proximal limbs. Primary venous tumors can occur anywhere on the body and the walls of the veins are rarely the site of the origin of the neoplasm. Intravascular lipoma is very rare and occurs most often in the inferior vena cava,<sup>2</sup> and a review of the literature found only a few isolated case reports involving the superior vena cava<sup>3</sup> and subclavian veins,<sup>4</sup> as well as innominate veins,<sup>5</sup> internal jugular veins, femoral veins,<sup>6</sup> and renal veins.<sup>1</sup>

In this article, we addressed a unique instance of intra- and extravascular lipoma involving the right subclavian and

brachiocephalic veins, as well as insights on differential diagnosis and treatment methods.

## Case Presentation

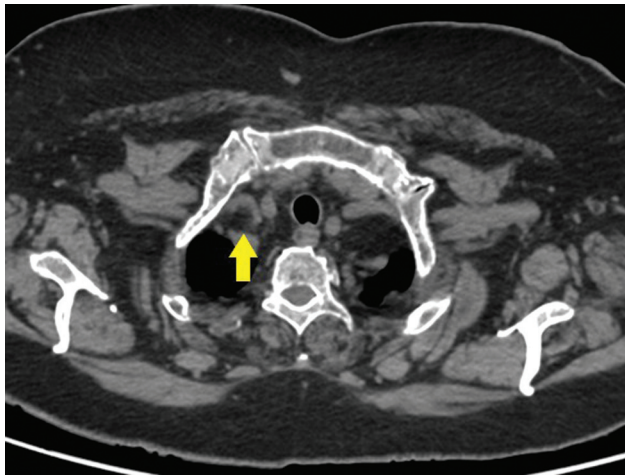
A 64-year-old female patient initially presented with a 3-week history of dry cough. A review of the systems was negative for any other signs and symptoms.

## Imaging Findings

A noncontrast computed tomography (CT) scan of the chest concurrently revealed a homogenous smooth fat-attenuating mass lesion in the perivascular zone of the right subclavian vein (▶ **Fig. 1**), extending to the brachiocephalic vein. At this level, the lesion appeared to be “intravascular” (▶ **Fig. 2A and B**). The coronal CT images show the extent of the lesion (▶ **Fig. 3A–C**)

DOI <https://doi.org/10.1055/s-0044-1788553>.  
ISSN 0971-3026.

© 2024. Indian Radiological Association. All rights reserved.  
This is an open access article published by Thieme under the terms of the Creative Commons Attribution-NonDerivative-NonCommercial-License, permitting copying and reproduction so long as the original work is given appropriate credit. Contents may not be used for commercial purposes, or adapted, remixed, transformed or built upon. (<https://creativecommons.org/licenses/by-nc-nd/4.0/>)  
Thieme Medical and Scientific Publishers Pvt. Ltd., A-12, 2nd Floor, Sector 2, Noida-201301 UP, India



**Fig. 1** Axial computed tomography (CT) plain images showing the extravascular portion of the fat-attenuating tumor in the right subclavian vein.

and the extravascular extension of the lipomatous tissue can be well seen in the sagittal CT images (►Fig. 4A and B).

## Discussion

### Background

The pathology literature proposes two theories to explain this unusual presentation<sup>4</sup>: the mass could originate in the

vein wall or in the fatty perivascular tissue. Initially, the tumor develops into the vein wall, projecting outside and inside the lumen. The second concept argues that the tumor starts from the perivascular tissue, infiltrates the vein wall, and eventually protrudes into the lumen which is an unusual site for a benign tumor.

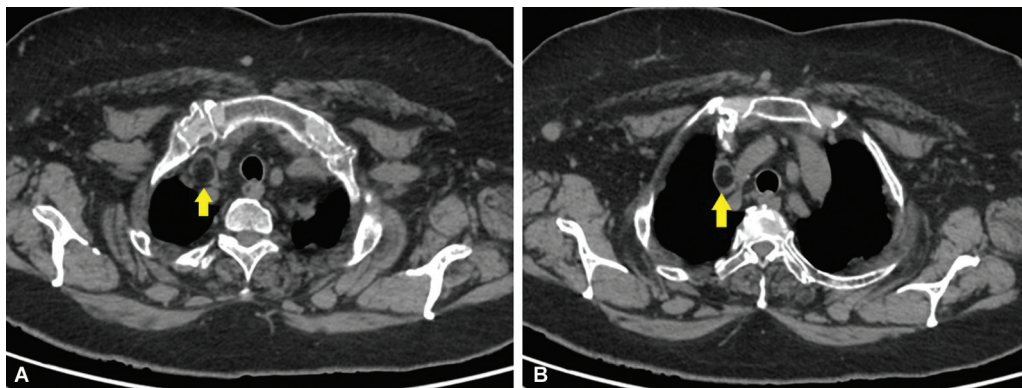
### Clinical Perspective

Although extremely rare, clinical implications of extra- and intravascular lipomas include venous compression or obstruction.

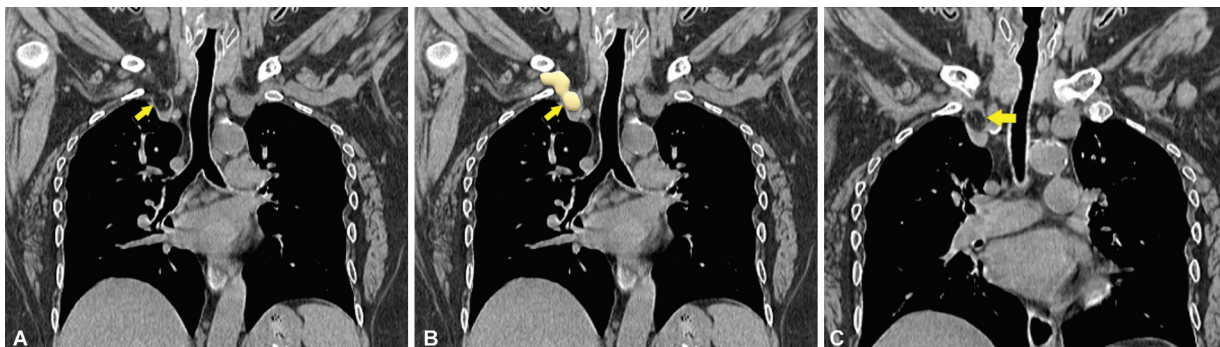
It is important to differentiate intravascular lipomas from other fat-containing intravascular malignant masses like liposarcomas, which appear more heterogeneous on imaging due to the presence of nonadipose components.<sup>7</sup>

### Imaging Perspective

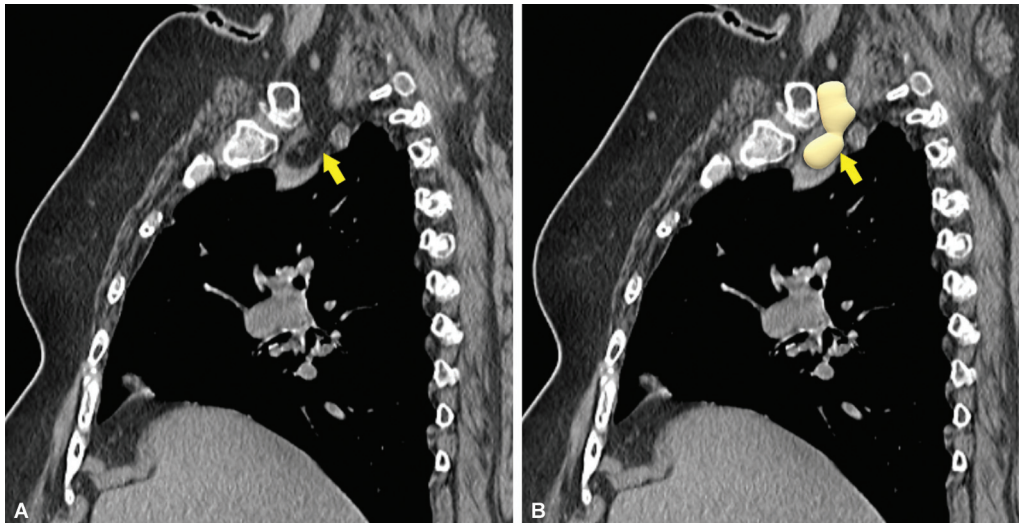
CT often reveals a well-defined, smooth ovoid, nonenhancing, hypoattenuating mass that corresponds to fat density. Intravenous contrast reveals a filling defect, indicating the lipomas' intraluminal location. On magnetic resonance (MR) imaging, these lesions present as nonenhancing, T1 and T2 hyperintense lesions that cancel out on fat-subtraction imaging. MR imaging is also beneficial in identifying simple lipoma from its near differentials, such as liposarcoma with the greatest sensitivity.<sup>8</sup>



**Fig. 2** (A and B) Axial computed tomography (CT) images demonstrating the well-circumscribed fat-attenuating intravascular tumor in the right subclavian vein (A) extending into the right brachiocephalic vein (B).



**Fig. 3** (A and B) Coronal noncontrast computed tomography (NCCT) images show the extent of the lesion with attenuation characters similar to that of surrounding fat. (C) Coronal NCCT image showing the intravascular component of the lesion in the right brachiocephalic/innominate vein.



**Fig. 4** (A and B) Sagittal noncontrast computed tomography (NCCT) images depicting the extravascular portion of the lesion in the perivascular zone of the right subclavian vein.

Angiography is typically used to determine the extent of obstruction and the presence of any venous collaterals. However, angiography is not usually performed if other imaging modalities reveal no significant vascular obstruction.

#### Outcome

The literature on the treatment of extra- and intravascular lipomas varies. Biopsy has often been deemed unnecessary when imaging clearly shows a fat-attenuating mass lesion composed exclusively of fat and the patient is asymptomatic. Surgical resection is usually recommended only if the patient is symptomatic and/or shows signs of venous obstruction.<sup>9</sup>

In the present instance, the lesion exhibited no substantial symptoms of venous blockage or the presence of venous collaterals, and there was no evidence of malignant potential on imaging. As a result, the decision was made to treat the case cautiously adopting surveillance. A repeat CT scan after 3 months revealed no change in the size or shape of the lesion (► **Fig. 5A** and **B**).

#### Learning Points

- Intravascular lipomas must be identified from their more malignant counterparts, such as liposarcomas, because a subset of lipomas might contain soft tissue and may be unrecognizable on imaging alone.
- Although benign, intravascular lipomas may necessitate surgery if there are concerns about obstructive consequences.

#### Patient Consent

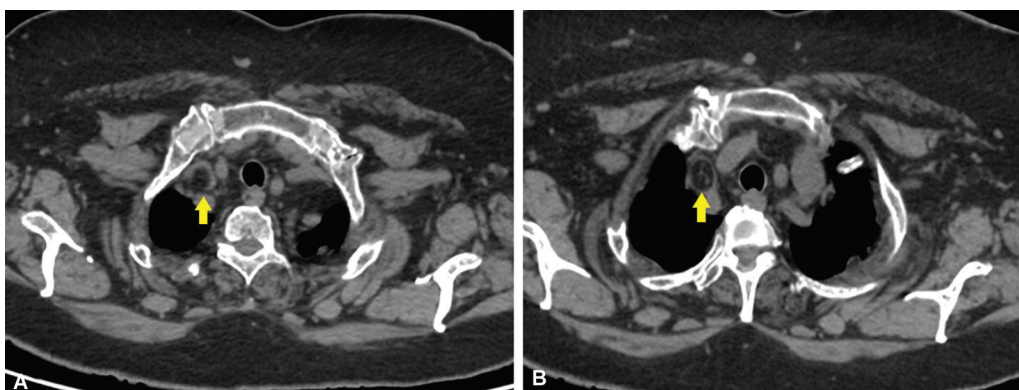
Informed consent was obtained from the patient for the publication of this case report and accompanying image.

#### Conflict of Interest

None declared.

#### Acknowledgments

We would like to thank Dr. Suhasini Devi P. and Dr. Rajkumar B. for the interpretation of images and guidance



**Fig. 5** (A and B) Follow-up imaging after 3 months shows no significant interval changes in the size or morphology of the tumor.

in preparation of this case report. A special note of thanks to CT technologists and Continental Hospitals for providing the medical records and images necessary to write up this case.

## References

- 1 Doyle Z, Wolford B, Morshedi MM, Santillan CS. Intravascular lipoma of the renal vein. *BJR Case Rep* 2015;1(02):20150072
- 2 Miyake H, Suzuki K, Ueda S, Yamada Y, Takeda H, Mori H. Localized fat collection adjacent to the intrahepatic portion of the inferior vena cava: a normal variant on CT. *Am J Roentgenol* 1992;158(02):423–425
- 3 Soetisna TW, Namretta L, Ronidipta B, Elen E, Raharjo SB, Tjubandi A. Giant lipoma in superior vena cava: a case report and literature review. *Int J Surg Case Rep* 2022;95:107142
- 4 Lomeo A, D'Arrigo G, Scolaro A, et al. A case of intra and extra-vascular lipoma of the subclavian vein. *EJVES Extra* 2007;13:37–39
- 5 Moore FO, Petersen SR, Norwood SH. Intravascular lipoma of the right innominate vein in a trauma patient. *J Am Coll Surg* 2008;207(01):139
- 6 Day A, Thomas P. Femoral sheath lipoma causing venous obstruction syndrome. *Ann R Coll Surg Engl* 2010;92(06):W21–2
- 7 Kransdorf MJ, Bancroft LW, Peterson JJ, Murphey MD, Foster WC, Temple HT. Imaging of fatty tumors: distinction of lipoma and well-differentiated liposarcoma. *Radiology* 2002;224(01):99–104
- 8 Gaskin CM, Helms CA. Lipomas, lipoma variants, and well-differentiated liposarcomas (atypical lipomas): results of MRI evaluations of 126 consecutive fatty masses. *Am J Roentgenol* 2004;182(03):733–739
- 9 Sundaram N, Kulkarni R, Sultan I, Singh MJ. Surgical resection of a symptomatic superior vena cava lipoma: a case report and literature review. *Ann Vasc Surg* 2021;71:535.e11–535.e15