

Never Regret Trying Image-Guided Sclerotherapy in Orbital Low-Flow Malformation

Gautam Lokdarshi¹ Shwetam Kumar²

¹Department of Oculoplastic and Ocular Oncology Services, IRIS Superspeciality Eye Hospital, Orchid Medical Centre, Ranchi, Jharkhand, India

²Department of Radiology Services, Orchid Medical Centre, Ranchi, Jharkhand, India

Indian J Radiol Imaging

Address for correspondence Gautam Lokdarshi, MD, MRCS, Oculoplastic and Ocular Oncology Services, IRIS Superspeciality Eye Hospital, Orchid Medical Centre, Ranchi 834001, Jharkhand, India (e-mail: gdarshiaiims@gmail.com).

In the article entitled “Image-guided Percutaneous Sclerotherapy for Orbital Low-Flow Malformation: Our Experience,” we have seen no response in a microcystic lympho-venous malformation (LVM) even in the presence of multimodal imaging.¹ Later, we could not attempt embolization and debulking as planned since this patient was lost to follow-up beyond 1 year. It has been well established that, unlike macrocystic LVM, microcystic LVM responds poorly to sclerosants.² Apart from this, there could be several other factors responsible for no response, such as a longstanding static lesion (no change in size or color), adult age, a scar from previous surgery, or a disproportionate clinical-radiological correlation.³

Interestingly, we have seen at least some favorable responses to image-guided sclerotherapy in a 13-year-old girl child patient for a longstanding LVM of the orbit (→**Fig. 1**). In the past, beginning when she was approximately 8 years old, she started

experiencing repeated episodes of pain and swelling. She had received intermittent, repeated oral and perilesional steroids during flare-ups elsewhere, along with maintenance doses of β -blockers for about 2 years, followed by sildenafil citrate for the next 2 years. Old records showed some resolution of the lesion on the initial 2 years of steroid and β -blocker treatment, while no change had been observed on the sildenafil therapy.

When the patient presented to us, she had a fresh episode of increasing pain and swelling of eyelids but no proptosis, accompanied by a chocolate cyst over the medial canthus and flaring up of oral mucosal lesions, which were not responding to any of the above medications (→**Fig. 1A, B**). Clinically, the left orbital lesion appeared to have ill-defined borders and depths extending over the adjacent periorbital region, ipsilateral temple, and cheek. Multimodal imaging revealed predominantly a microcystic LVM with combined,

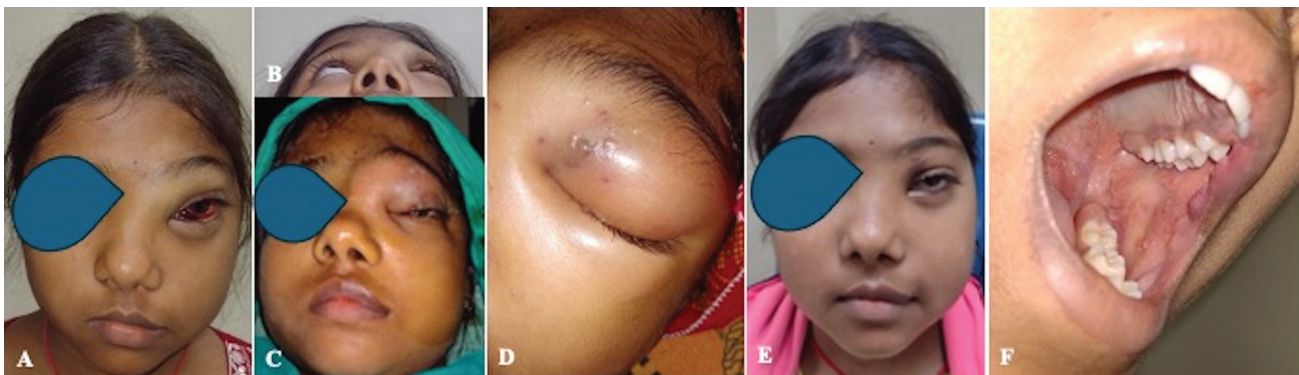

Fig. 1 (A) Left periorbital swelling with chocolate cyst and subconjunctival hemorrhages; (B) no proptosis; (C) lid edema immediately after bleomycin injection, day 0; (D) inflammatory edema worsen on day 1, with blisters appearing on day 2; (E) improvement at 6-month follow-up; (F) regressed oral mucosal lesions, which could be noticed as less deviation of the angle of the mouth, in (E) than in (A).

DOI <https://doi.org/10.1055/s-0044-1788552>.
ISSN 0971-3026.

© 2024. Indian Radiological Association. All rights reserved.
This is an open access article published by Thieme under the terms of the Creative Commons Attribution-NonDerivative-NonCommercial-License, permitting copying and reproduction so long as the original work is given appropriate credit. Contents may not be used for commercial purposes, or adapted, remixed, transformed or built upon. (<https://creativecommons.org/licenses/by-nc-nd/4.0/>)
Thieme Medical and Scientific Publishers Pvt. Ltd., A-12, 2nd Floor, Sector 2, Noida-201301 UP, India

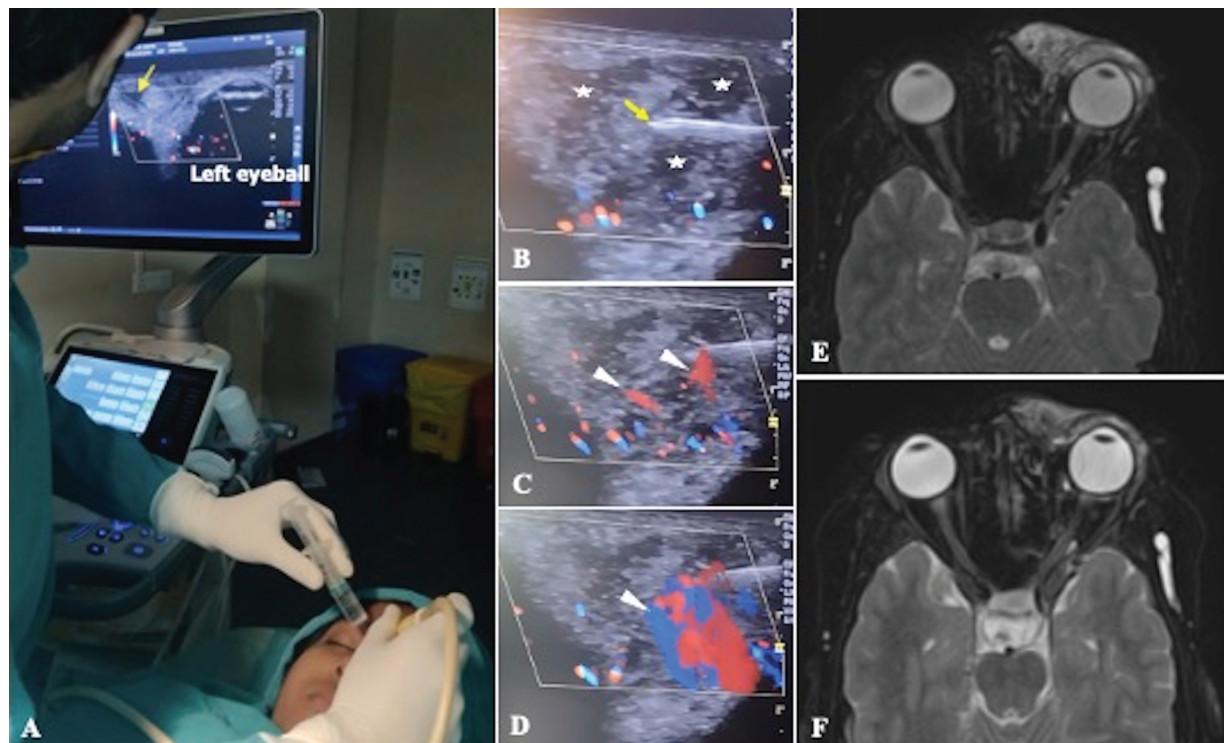


Fig. 2 (A–D) Snapshots of real-time Doppler-guided injection in the medial preseptal lesion. Notice the needle as a white reflecting line (arrow), the left eyeball shadow, the relatively avascular cystic spaces (stars), and the influx of the drug (arrowheads); (E) pre- and (F) postsclerotherapy axial T2 fat saturation (FAT-SAT) magnetic resonance imaging (MRI), showing moderate reduction in the preseptal component at 6 months' follow-up. The postseptal component along the medial extraconal compartment has also reduced.

superficial, and deep orbital and periorbital regions. Intraosseous and intracranial components are also noted. The absence of any well-defined chocolate cyst and the presence of direct communication to the ophthalmic and cavernous vessels, along with the possibility of postinjection severe inflammation, could be the reasons for not trying sclerotherapy by the previous physicians.²

Explaining the risks involved, we took up the case for urgent bleomycin sclerotherapy under fluoroscopic control. Using the aspiration-injection technique under Doppler guidance for the needle tip, the chocolate cyst, and the most superficial lesions with multiple punctures under topical priloxine (PRILOX gel) (►Fig. 2A–D; ►Video 1), they were treated with bleomycin (total aspirated blood = 3 mL, total drug injected = 4 mL). No harmful effect was noted apart from the transient, painless preseptal inflammatory edema, for which oral steroid 0.5 mg/kg/day was given for 3 days, and a few blisters with skin pigmentation near some puncture sites, for which topical hydrocortisone cream with silicone gel was advised (►Fig. 1C–E). Moderate clinic-radiological regression was seen over the next 6 months

(►Figs. 1E, F and 2E, F). Albeit no worsening or recurrence has been reported yet, another sclerotherapy session might be considered following review by the multidisciplinary team.

Video 1

Real-time Doppler-guided intralesional sclerosant injection. Online content including video sequences viewable at: <https://www.thieme-connect.com/products/ejournals/html/10.1055/s-0044-1788552>.

So, knowing the safety of image-guided sclerotherapy, if the facility is available, one should not defer even in a relatively less favorable case.

Patient Consent

An informed consent was taken from the parents of the patient for publishing their data.

Ethical Approval

The present study complies with the Declaration of Helsinki and CARE guidelines.

Author Contributions

Preparation and editing of manuscript: G.L., S.K.; data collection and literature search: G.L.; review or approval of the manuscript: G.L., S.K..

Funding

None.

Conflict of Interest

None declared.

References

- 1 Lokdarshi G, Kumar S, Kumar S, Nitu N, Gaur N. Image-guided percutaneous sclerotherapy for orbital low-flow malformation: our experience. *Indian J Radiol Imaging* 2024;34(03): 539–544
- 2 Rootman DB, Diniz SB, Cohen LM. Clinical assessment and lesion-specific management of orbital vascular malformations. *J Neurol Surg B Skull Base* 2021;82(01):116–128
- 3 Nevesny F, Chevallier O, Falvo N, et al. Bleomycin for percutaneous sclerotherapy of venous and lymphatic malformations: a retrospective study of safety, efficacy and mid-term outcomes in 26 patients. *J Clin Med* 2021;10(06):1302